



Acute Ischemic Stroke in COVID-19 Patient with Lung Collapse: A Case Report

Mahpara Nawazish^{1*}, Sana Iqbal¹ and Mujeeb Ur Rehman Abid Butt¹

¹Shalamar Hospital, Lahore, Pakistan.

Authors' contributions

This work was carried out in collaboration among all authors. Authors MN and SI managed the literature searches and drafting. Author MURAB was the primary physician of the patient, gave concept of writing case report and drafting. All authors read and approved the final manuscript.

Article Information

DOI: 10.9734/AJRID/2021/v6i330194

Editor(s):

- (1) Dr. Win Myint Oo, SEGi University, Malaysia.
- (2) Dr. Hetal Pandya, SBKS Medical Institute & Research Center, India.
- (3) Dr. Giuseppe Murdaca, University of Genoa, Italy.

Reviewers:

- (1) Rosario Luca Norrito, University of Palermo, Italy.
- (2) Archavlis Eleftherios, Universitätsmedizin Mainz, Germany.
- (3) Prem Prakash Mishra, LLRM Medical College, India.

Complete Peer review History: <http://www.sdiarticle4.com/review-history/66162>

Received 10 February 2021

Accepted 17 March 2021

Published 24 March 2021

Case Study

ABSTRACT

Novel corona virus 2019 also known as severe acute respiratory syndrome coronavirus 2 [SARS COV2] is enveloped non segmented ribonucleic acid (RNA) virus. Acute ischemic stroke remains emergency during covid19 pandemic [1] Here we present a case of a woman with COVID 19 who presented to us with symptoms of altered state of consciousness (ASOC), cough, fever, dysarthria, right sided body weakness and massive bilateral middle cerebral artery (MCA)/ anterior. Our case was unique in the sense that it showed drastic central nervous system (CNS) damage in the presence of coronavirus infection. There are a few cases of patients who develop stroke after COVID 19 infection.

Aims: Clinicians need to be aware of possible causes of unconsciousness in coronavirus disease (COVID 19) patients, particularly as delirium appears to be common complications to find out the association between stroke and COVID 19 and its impact and mortality.

Case Presentation: A 70 years old lady presented to us with symptoms of stroke like ASOC, right sided body weakness, dysarthria, and symptoms of pneumonia like mild cough and fever later which turned out to be COVID 19. Clinicians need to be aware of possible causes of unconsciousness in coronavirus disease (COVID 19) patients, particularly as delirium appears to

*Corresponding author: E-mail: mahpararajpoot123@gmail.com;

be common complications to find out the association between stroke and COVID 19 and its impact and mortality.

Discussion: Bilateral ischemic stroke is relatively uncommon presentation in general population and is usually the result of cardio embolic cause such as atrial fibrillation and recent myocardial infarction. While this patient had pre existing risk factors for stroke such as type 2 diabetes mellitus, hypertension and old age and her electrocardiography showed sinus rhythm.

Conclusion: COVID-19 may be a risk factor or aggravating factor for stroke.

Keywords: COVID-19; Ischemic stroke; pneumonia; hepatic encephalopathy.

1. INTRODUCTION

COVID 19 appeared from Wuhan, China at the end of 2019 and became pandemic involving the whole world [1]. It presents with symptoms of fever, cough, shortness of breath, acute respiratory distress syndrome (ARDS), severe pneumonia, acute kidney injury (AKI), multiple organ failure, myocarditis and death. The patient may present with atypical gastrointestinal symptoms like diarrhea and abdominal pain and neurological symptoms such as body weakness, headache, seizures, taste and smell impairment and nerve pain, [1]. Neurological manifestations of SARS COV2 were first reported in Wuhan by Zhou et al. [2]. About 36% of COVID positive patients had neurological symptoms. Patients with COVID 19 were in hypercoagulable or in prothrombin state that caused stroke in COVID 19 patients. Increased prothrombin time, activated partial thromboplastin time and decrease platelet count was also reported which may increase the risk of hemorrhagic incident [3].

2. CASE REPORT

A woman 70 years of age presented to hospital with complaints of ASOC, dysarthria, right sided body weakness and mild nonproductive cough of one day duration. She was a known case of diabetes mellitus and hypertension for which she had been following her primary care physician on regular basis. On examination, the patient was confused though occasionally following the verbal commands. Her blood pressure was 90/60mmHg, pulse was 72 beats/minute, respiratory rate was 22 breaths/minute, Spo₂ 98% with 2 liters of oxygen and temperature was 100F. On neurological examination, patient had a score of 8/15 on the Glasgow coma scale (GCS). The power was 1/5 on the right side and 3/5 on the left side. Babinski's sign was also positive on both sides. Sensations could not be checked because of low GCS. There were no signs of meningeal irritation. Chest X-Ray on day 1 is

shown in Fig. 1A. ECG was normal while Echocardiography ejection fraction of 60% with good ventricular systolic function, moderate tricuspid regurgitation and mild pulmonary hypertension. Carotid Doppler was normal with 30% stenosis.

Considering above stroke, hyperosmolar hyperglycemic state formerly called as hyperosmolar non ketotic coma, septic encephalopathy and pneumonia were suspected. Computed tomography (CT) scans the brain and polymerase chain reaction (PCR) by nasal swab for COVID 19 was advised. Four pack cell volume were transfused and an intravenous meropenem, moxifloxacin, insulin according to sliding scale and general supportive care was started. CT scan showed chronic micro vascular angiopathic changes along with old lacunar infarcts in head of right caudate nucleus, asymmetric hypo dense area in right posterior periventricular deep white matter, suggesting subacute focal ischemic changes.

On day 3 of admission, PCR for COVID 19 report came as negative while patient's consciousness level did not improve. On day 4 report of Hepatitis C serology came as positive incidentally, although the patient did not know about her hepatitis C status previously. And considering a reversal of ratio in liver transaminase level treatment was modified to include hepatic encephalopathy, including rifaximin and lactulose.

On day 5th, fever up to 101 F was noted and Ultrasound abdomen showed renal calculi with paper thin cortex and hydronephrosis. Same day chest x-ray was repeated showing right upper lung collapse in Fig. 1B and considering the progression of lung lesion COVID-19 PCR was repeated which turned out to be positive on day 7. Considering financial issues as is quite common in our part of the world family was reluctant to carry on with the treatment in the hospital and decided for self discharge.

Telephonic conversation with the family later revealed that the patient died on the second day of discharge.

So in a nutshell, this case was initially thought of suffering with pneumonia with stroke and later thought of having septic encephalopathy and finally the diagnosis came out to be COVID19 infection.

3. DISCUSSION

COVID-19 is a current worldwide pandemic with diverse complications [1]. It is clear that corona viruses can affect the nervous system either directly or indirectly through different pathways. This unique virus can gain direct access to nervous system either via blood circulation, neuronal pathways or direct extension via olfactory bulb. Umar Farooque SS et al. [1] More

importantly, indirect pathways of central nervous system infection can occur in the setting of hypoxemia, immune mediated insults or as highlighted by this case via multiple organ affection with potential of CNS consequences. The liver is the second most common organ to be affected after lung [1]. Another mechanism that could explain the specific organ affinity is angiotensin converting enzyme 2 (ACE 2) receptors. There is evidence of ACE 2 receptors in the brain specifically on the glial cells and neurons, and also in the liver, meaning that there is high binding affinity between the corona virus and these receptors that make infection, and thus injury, very feasible [1]. Overall, 25% of patients had symptoms considered as evidence of CNS dysfunction, including dizziness, headache, impaired consciousness, acute cerebrovascular disease, ataxia, and seizure [4].

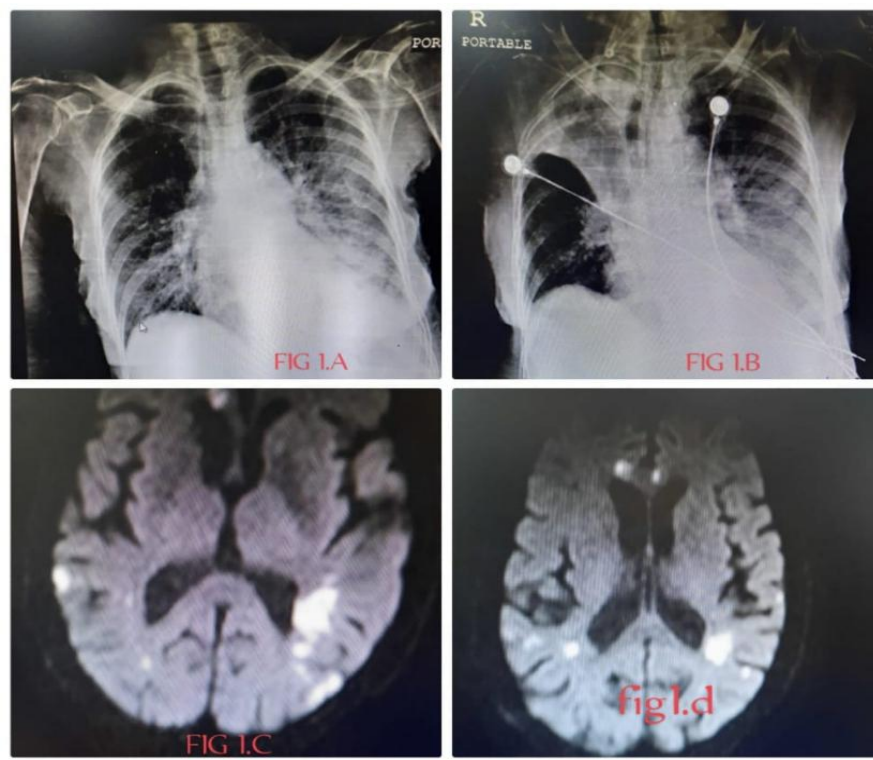


Fig. 1. A. Chest x ray showing inhomogeneous air space opacification in bilateral lower lung zones favoring active inflammatory process and cardiomegaly
B. Chest x ray showing right upper lobe lung collapse, left pleural effusion is suspected, left lung is clear and heart shadow is normal
C and D. Magnetic resonance imaging (MRI) brain diffusion weighted imaging (DWI) sequence showing multiple acute bilateral lacunar infarcts on the background of chronic micro vascular angiopathic changes

Table 1. List of parameters and their concentration

Test name	Day 1	Day 4	Day 7	Unit	Reference range
Hemoglobin	4.1	4.4	9.5	g/dl	12-16
TLC	10.1	10	16	10.e3/uL	4-11
Platelet	241	244	317	10.e3/uL	150-250
pH	7.407	7.234	7.365		7.35-7.45
pCO2	25.0	51.7	39.1	mmHg	35-45
pO2	106	71	83	mmHg	80-100
HCO3	15.7	21.9	22.3	mmol/L	24-28
Urea	140	158	127	mg/dl	10-50
Creatinine	1.6	2.0	1.9	mg/dl	0.5-1.3
CRP	59.0		14	mg/L	<5
Sodium	130	138	147	mmol/L	135-145
Potassium	5.2	4.2	3.1	mmol/L	3.5-5.1
Chloride	97	103	110	mmol/L	96-108
Calcium		8.6		mg/dl	8.5-10.5
HbA1C		7.9 %			< 5.8%
Serum ferritin		265.2		ng/ml	10 to 120 ng/mL
Albumin		2.7		g/dl	3.5-5 gm/dl
ALT		28		U/L	5-40 U/L
AST		50		U/L	5-40 U/L
BILIRUBIN		0.5		Mg/dl	0.10-1.10
HBsAg		-ve			
Anti HCV		+ve			

The main outstanding characteristics of our stroke patient was the size of infarct, the larger size artery involvement and the relative absence of conventional cerebrovascular risk factors. SARS-CoV-2 has been shown to induce a hypercoagulable state, thus increasing the risk of arterial thrombosis with acute ischemic stroke [5]. SARS-CoV-2 binds to ACE 2, the host target cell receptor. The distribution of ACE 2 receptors in different tissues may explain the sites of infection and patient symptoms [6]. The first report of 99 hospitalized patients in Wuhan showed that inflammatory biomarkers of interleukin-6, erythrocyte sedimentation rate, C reactive protein, D-dimer, and other coagulation parameters were increased or deranged [7]. Among all admissions positive for SARS-CoV-2, 0.9% (22/2513) presented with an acute ischemic stroke. Of those that were negative for SARS-CoV-2 infection, 2.4% (544/22295) presented with an acute ischemic stroke. Mortality for COVID-19 positive patients with stroke appears to be 31.8% as compared with 4.6% for COVID-19-negative patients with stroke and this is hypothesized to be due to respiratory impact of COVID-19 on an already compromised patient with stroke [8]. We also observed the same as our patient died on the second day of discharge from the hospital. Liver dysfunction may affect about one-third of the patients, with prevalence greater in men than women, and in

elderly as we observed in our case. Liver injury is specifically observed in acute COVID-19 infections and this is especially true in elderly and those having preexisting liver disease [9]. In a retrospective observational study from Wuhan, China, acute ischemic stroke complicated 5% of hospital admissions with COVID 19 during the study period. As a comparator, data from 2009 study in Seoul prior to COVID 19 reported ischemic stroke complicating 0.04% to 0.06% of hospital admissions for all clinical presentations. Mohamed IZ et al. [10] and this deserves special attention. Sensitivity of COVID- 19 PCR by nasal swab is 70% and specificity is 90% and this is the reason that the test needs to be repeated in strongly suspected cases as was true in our case [11].

4. MANAGEMENT

Early diagnosis, quarantine and supportive treatment are essential to cure patients. As SARS COV 2 is an emerging virus, no anti viral agents have been recommended for corona virus infection. In this case, low doses of dexamethasone therapy were used to avoid inflammatory storms. All suspected stroke cases should have brain imaging on hospital arrival, preferably within 20 mints. Stroke patients who meet the criteria should undergo rapid interventions with thrombolysis using

recombinant tissue plasminogen activator (alteplase) or mechanical thrombectomy in those with large vessel occlusion [12].

5. CONCLUSION

Patients with COVID-19 can present with cerebrovascular accidents. Those having stroke with COVID-19 had worse outcomes compared with those without, with over a 9 fold increase in mortality. Further analysis is needed on a large scale to find out the true relationship between COVID 19 and ischemic stroke and its pathogenesis.

CONSENT

All authors declare that written informed consent was obtained from the patient or other approved parties for publication of this case report.

ETHICAL APPROVAL

It is not applicable.

COMPETING INTERESTS

Authors have declared that no competing interests exist.

REFERENCES

1. Umar Farooque SS, Karimi S, Lohano AK, et al. Coronavirus disease 2019-related acute Ischemic stroke: A case report. *Cureus*. 2020;12(9).
2. Wijeratne T, Sales C, Karimi L, et al. Acute ischemic stroke in COVID-19: A case-based systematic review. *Frontiers in Neurology*. 2020;11.
3. Karvigh SA, Vahabizad F, Banihashemi G, et al. Ischemic stroke in patients with COVID-19 disease: A report of 10 cases from Iran. *Cerebrovascular Diseases*; 2020.
4. Koranik IJ, Tyler KL. COVID-19: A global threat to the nervous system. *Annals of Neurology*. 2020;88(1):1-1.
5. Mahboob S, Boppana SH, Rose NB, et al. Large vessel stroke and COVID-19: Case report and literature review. *Eneurologicalsci*. 2020;20:100250.
6. Cevik M, Kuppalli K, Kindrachuk J, et al. Virology, transmission, and pathogenesis of SARS-CoV-2. *BMJ*. 2020;371.
7. Bhatia R, Pedapati R, Komakula S, et al. Stroke in corona virus disease 2019: A systematic review. *Journal of Stroke*. 2020; 22(3):324.
8. Bekelis K, Missios S, Ahmad J, et al. Ischemic stroke occurs less frequently in patients with COVID-19: A multicenter cross-sectional study. *Stroke*. 2020;51(12): 3570-6.
9. Portincasa P, Krawczyk M, Machill A, et al. Hepatic consequences of COVID-19 infection. Lapping or biting?. *European Journal of Internal Medicine*; 2020.
10. Mohamed IZ, Balson L, Madathil S. Massive bilateral stroke in a COVID-19 patient. *BMJ Case Reports CP*. 2020; 13(8):e236254.
11. Watson J, Whiting PF, Brush JE. Interpreting a COVID-19 test result. *BMJ*. 2020;369.
12. Ojo AS, Balogun SA, Idowu AO. Acute ischemic stroke in COVID-19: Putative mechanisms, clinical characteristics, and management. *Neurology Research International*; 2020.

© 2021 Nawazish et al.; This is an Open Access article distributed under the terms of the Creative Commons Attribution License (<http://creativecommons.org/licenses/by/4.0>), which permits unrestricted use, distribution, and reproduction in any medium, provided the original work is properly cited.

Peer-review history:
The peer review history for this paper can be accessed here:
<http://www.sdiarticle4.com/review-history/66162>