



Antitoxic Effects of *Solanum betaceum* cav. Peel Skin Extract

Janti Sudiono^{a*}, Pretty Trisfilha^a and Debi Agita^a

^a Department of Oral Pathology, Faculty of Dentistry, Universitas Trisakti, Jakarta, Indonesia.

Authors' contributions

This work was carried out in collaboration among all authors. Author JS designed the study, wrote the protocol, and approved the final manuscript. Author PT managed the literature searches and approved the final manuscript. Author DA managed the experimental laboratory, the statistical analysis and approved the final manuscript. All authors read and approved the final manuscript.

Article Information

DOI: 10.9734/AJBGMB/2022/v12i4276

Open Peer Review History:

This journal follows the Advanced Open Peer Review policy. Identity of the Reviewers, Editor(s) and additional Reviewers, peer review comments, different versions of the manuscript, comments of the editors, etc are available here: <https://www.sdiarticle5.com/review-history/93916>

Original Research Article

Received 12 September 2022

Accepted 16 November 2022

Published 22 November 2022

ABSTRACT

Background: In Indonesia, *Solanum betaceum* cav is a traditional herbal medicine which their skin is often wasted because not many people known its content.

Aims: To find out the anti-toxic effect of *Solanum betaceum* cav peel skin ethanol extract on rat's renal post-carrageenan induction.

Study Design: Laboratory experimental in vivo study.

Place and Duration of Study: This research was done at Animal Research Facilities (ARF) Medical Faculty University of Indonesia, at September to December 2021.

Methodology: The samples used in this research are male white mice, Wistar strain (*Rattus norvegicus*) with the body weight 180–220 gram which divided into 5 groups, negative control (saline), positive control (sodium diclofenac 7mg/kgBW), and *Solanum betaceum* Cav. peel skin ethanol extract groups (70mg/kgBW, 140mg/kgBW, and 280mg/kgBW). Mice's buccal mucosa was injected with Carrageenan 1%. Macroscopic and microscopic observation was done before, 24 hours, 48 hours and 72 hours post carrageenan injection.

Results: Phytochemical test showed that *Solanum betaceum* Cav. peel skin ethanol extract contains phenolic, flavonoid, tannin, and alkaloid. At all doses, anti-toxic effect of *Solanum betaceum* Cav. peel skin ethanol extract have same healing effectiveness within 48 hours. In positive control, the renal were normal at 48 hours. Meanwhile, the negative control's healing effectiveness was seen at 72 hours.

*Corresponding author: E-mail: jantish@trisakti.ac.id;

Conclusion: The anti-toxic effect of *Solanum betaceum* Cav. peel skin ethanol extract has effective healing process at all doses in 48 hours post-carrageenan induction without affect rats' body weight, however with lower intensity than positive control which using diclofenac as anti-inflammatory drug.

Keywords: *Solanum betaceum* Cav. peel skin extract; antitoxic; carrageenan; rat's renal.

1. INTRODUCTION

Indonesia has a variety of natural herbal medicine. There are around 30.000 vegetables with 7.000 among them has potential herbal therapy [1]. One of these is *Solanum betaceum* Cav [2]. Its fruit has high protein, low calorie, low lipid, and contain micronutrients such as vitamins, mineral, and bioactive components like as flavonoid, steroid terpenoid, alkaloid, saponin, and tannin. The flavonoid content has antimicrobial effect [3].

Now, the uses of *Solanum betaceum* Cav limited on its fruits as antioxidant usage. The potency of peel skin has not already been known just as natural wasted material. Actually, there is a lot of phytochemical content within the peel skin [4]. The peel skin of *Solanum betaceum* Cav contain vitamins such as vitamin C, A, E, B6, also terpenoid, steroid, saponin, alkaloid and tannin [5]. Therefore this study was done to find out the anti-toxic effect of the peel skin of *Solanum betaceum* Cav ethanol extract on rat's renal after inflammatory induction on its buccal mucosa with carrageenan as inflammatory agent. The result will give an inflammatory process which release inflammatory mediators cause vasodilatation, exudation and phagocyte migration toward inflammatory area. All of these will examine microscopically in the renal as the first metabolic organ against inflammation.

2. MATERIALS AND METHODS

This study is a laboratory experimental in vivo study to find out the anti toxic effect of *Solanum*

betaceum Cav peel skin ethanol extract on kidney rat post carrageenan injection on buccal mucosa as inflammatory induction. The study consisted of 5 groups with two rats for each group. The first group was given saline solution as negative control group. The second was given sodium diclofenac 7 mg/kgBW as positive control group. The treatment group consisted of three groups that were given the peel skin of *Solanum betaceum* Cav ethanol extract with dose of 70 mg/kgBW, 140 mg/kgBW dan 280 mg/kgBW. After 30 minutes the 1% carrageenan injection was done on buccal mucosa of each subject.

The microscopic examination and the thickness measurement on right and left buccal mucosa were done before, 24 hours, 48 hours, and 72 hours post carrageenan injection. Subjects of study were executed by injection of 1.5 ml xylazine and 3 ml ketamines intra peritoneal. Renal organs of subjects were fixated on 10% formalin buffer. The specimen was processed into paraffin and the Hematoxyllin eosin (HE) to find out the microscopic examination. Renal albumin degeneration was scored as criteria: widen of tubular lumen, debris cells accumulation, epithelial tubular hyperplasia, inflammatory cells within glomerular and periglomerular (Table 1).

Score 1: Normal (no inflammatory sign of tubular and glomerular/periglomerular)

Score 2: Mild (one or two inflammatory sign of tubular and glomerular/ periglomerular)

Score 3: Severe (three of four inflammatory sign of tubular and glomerular/ periglomerular).

Table 1. Hystopathological score of renal albumin degeneration

Score	Criteria
1	No sign of albumin degeneration based on tubular lumen wide, debris cells accumulation, tubular epithelial hyperplasia, inflammatory cells of glomerular/periglomerular
2	One to two signs.
3	Three to four signs.

3. RESULTS

Phytochemical test result showed on Table 2.

Histopathological features of renal subjects showed on Figs. 1, 2 and 3.

Histopathological score 1 (normal) found on renal of positive control subjects on 48 hours (Fig. 1).

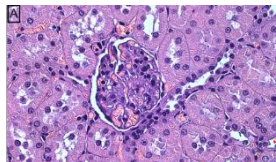
Histopathological score 2 (mild) found on renal of peel skin *Solanum betaceum* Cav ethanol extract 280mg/kgBW subjects on 72 hours (Fig. 2).

Histopathological score 3 (severe) found on renal of negative control subjects on 48 hours (Fig. 3).

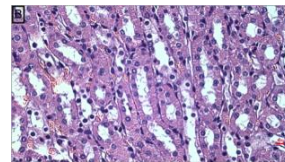
Microscopic examination renal subjects of each group on 24, 48, 72 hours post carrageenan induction showed in Fig. 4.

Table 2. Phytochemical content of peel skin of *Solanum betaceum* Cav ethanol extract

No.	Secondary metabolit	Method	Result
1.	Phenolic	FeCl ₃ 5% solution	+
2.	Flavonoid	a. HCl 38% solution + Mg b. H ₂ SO ₄ 2N solution c. NaOH 10% solution	+ + +
3.	Steroid	Lieberman-Burchard solution	-
4.	Triterpenoid	Lieberman-Burchard solution	-
5.	Saponin	HCl solution + H ₂ O	-
6.	Tannin	FeCl ₃ 1% solution	+
7.	Alkaloid	a. Heger solution b. Wagner solution c. Dragendorff solution	+ + +



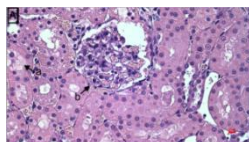
A. Glomerular (Score 1): normal



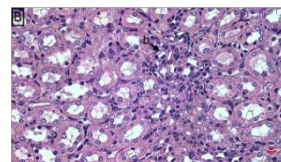
B. Tubular (Score 1): normal

Magnification (10x40); Hematoxyllin Eosin

Fig. 1. Score 1. Positive control subject on 48 hours



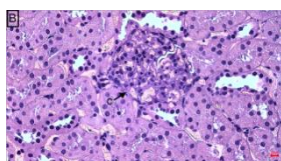
A. Glomerular (Score 2)
b:inflammatory cells within glomerular and periglomerular



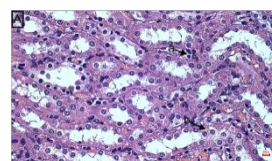
B. Tubular (Score 2)
a: debris in tubular lumen

Magnification (10x40); Hematoxyllin Eosin

Fig. 2. Score 2. Peel skin *Solanum betaceum* Cav ethanol extract 280mg/kgBW subject on 72 hours



A. Glomerular (Score 3): (inflammatory cells within glomerular and periglomerular)



B.Tubular (Score 3):
a: epithelial hyperplasia
b:debris in tubular lumen

Magnification (10x40); Hematoxyllin Eosin

Fig. 3. Score 3. Negative control subject on 48 hours

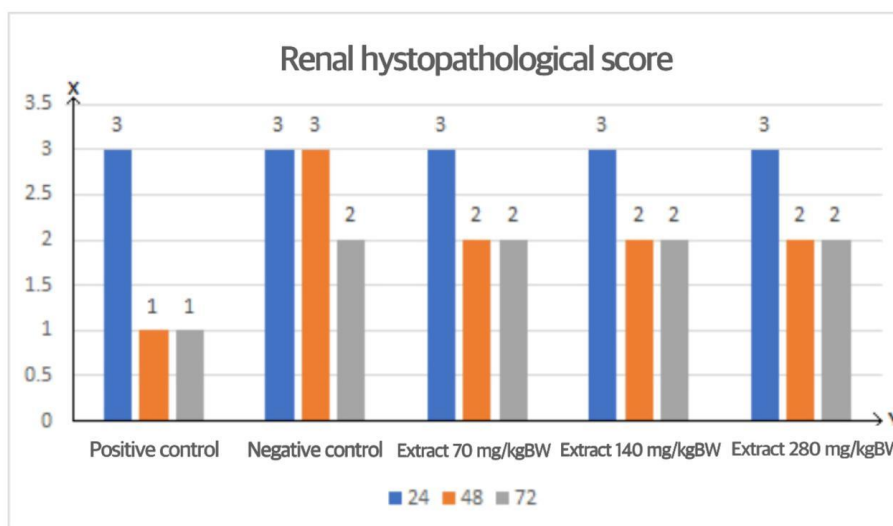


Fig. 4. Renal histopathological score

Table 3. *Kruskal Wallis* test of renal histopathological features

	Carrageenan injection	
	Before	After
Kruskal-Wallis H	29.000	000
Df	14	14
Asymp. Sig.	.010	1.000

This study resulted in categorical data (ordinal score) therefore the non parametric statistical analysis used *Kruskal Wallis* test with the result there was significant differences ($p < 0.05$) among groups that meant there were significant differences within the inflammatory and healing process among groups (Table 3).

Body mass and buccal mucosa thickness of subjects were measured digitally before and 24, 48, 72 hours after carrageenan induction with the result there was increasing within subject groups.

4. DISCUSSION

Phytochemical test of peel skin *Solanum betaceum* Cav ethanol extract in this study showed there are phenolic, flavonoid, tannin, and alkaloid content (Table 2). This result proper with the previous study that bioactive component of peel skin *Solanum betaceum* Cav are flavonoid, steroid terpenoid, alkaloid saponin, tannin and micronutrient like vitamins, mineral, high protein, low calories of lipid, and a lot of active biocomponent [3]. Flavonoid, phenolic content of peel skin *Solanum betaceum* Cav ethanol extract has anti allergy, anti inflammatory, and anti oxidant potency [6]. Tannin within peel skin

Solanum betaceum Cav ethanol extract also has anti oxidant and anti toxic function. The bioactive component content of peel skin *Solanum betaceum* Cav ethanol extract role toward toxic effect in this study which inducted by carrageenan as pro inflammatory agent showed effective in healing process.

The observation in this study used microscopic evaluation of renal subjects with the reason that renal is a very rich vascular organ as a cleanser or blood supply filtrated to put the organic rest material such as urea, creatinine, uric acid, hormone and hemoglobin rest product out. However this cleanser organ will be destroyed by toxic material exposure [7]. The early renal dysfunction is able to be evaluated through hystopathological feature in form of albumin degeneration i.e. increase or widen of tubular lumen, debris cell accumulation within lumen, tubular epithelial hyperplasia and inflammatory cells within glomerular and periglomerular [8].

Degeneration is a non specific form of destruction occurred by etiological factors that disturb the cell function and often used as early indicator of necrosis. In several cases, degeneration occurred after swelling of cells with

or without cytoplasm vacuolization and fragmentation, and pale stain. Degeneration could be reversible or irreversible [9]. The increase or widen of tubular lumen is caused by the necrosis of epithelial tubular cells. It is occurred by the destruction of glomerular that cause lower of filtration rate capacity and make the tubular function to excrete solved materials become heavier. In this condition, every renal tubular cell becomes osmotic diuretic and loss of obligatory water further the dead of cells. The necrotic of tubular cells give rest of necrotic cells or debris within tubular lumen [8]. Apical tubular hyperplasia (HTA) can occur spontaneously related to chronic progressive nephropathy or caused of certain chemical exposure. This is suspected as putative pre neoplastic lesion as part of neoplasm manifestation [9]. The widen of Bowman capsule caused by a lot of glomerular cells destruction as if there is high decrease of glomerular cells make the widen of glomerular and Bowman capsule [10].

Macroscopic evaluation of subject body mass and the buccal mucosa thickness was done before, 24, 48, and 72 hours after carrageenan injection as pro inflammatory agent. Carrageenan induction cause releasing of inflammatory mediator that cause capillary vasodilatation and phagocyte migration toward inflamed area [11].

Histopathological evaluation to the renal destruction in form of albumin degeneration was done in this study based on the increase or widen of tubular lumen, accumulation of debris cells, hyperplasia of epithelial tubular and inflammatory cells within glomerular and periglomerular (Table 1). The result showed that on 24 hour, there was no healing process of renal subject of peel skin *Solanum betaceum* Cav ethanol extract with dose of 70 mg/kgBW, 140 mg/kgBW and 280 mg/kgBW. There were a lot of inflammatory cells found in microscopic feature. This same condition also found in negative control subjects up to 48 hours (Fig. 3). In this phase, the edema of buccal mucosa of subjects was not cured however there was no influence on the subject body weight.

On 48 hours, the anti toxic effect of peel skin *Solanum betaceum* Cav ethanol extract with dose of 70 mg/kgBW, 140 mg/kgBW and 280 mg/kgBW showed the same potency that started renal healing process with the reduction of inflammatory cells on glomerular and periglomerular (Fig. 2). This is caused of

flavonoid content as anti inflammatory and anti-oxidant material [6]. Anti oxidant is needed to prevent oxidative stress that role act as an important etiology of degenerative diseases [12]. Previous study revealed that flavonoid has potency as apoptosis induction to stop the cell cycle and change the way involved in cancer formation such as inflammation and proliferation [13].

In this study, the effectiveness of all doses of peel skin *Solanum betaceum* Cav ethanol extract is still lower than those of positive control which showed that on 48 hours there was no renal inflammatory cells found that mean the healing process more rapid within positive control subjects (Fig. 1). Sodium diclofenac used as positive control due to its anti inflammatory, analgetic, and antipyretic potency therefore often used as a comparative material control within anti inflammatory studies beside its ability to be absorbed rapidly with minimal side effect compared to other anti inflammatory drugs [14].

At 48 hours, there was still no renal healing effect found on negative control group (score 3). On the other hand there was healing process effect found on each group of peel skin *Solanum betaceum* Cav ethanol extract and totally healing process effect found on positive control found at 48 hours without influenced the buccal mucous thickness and body mass increase of subjects.

Anti toxic effect of peel skin *Solanum betaceum* Cav ethanol extract with dose of 70 mg/kgBW, 140 mg/kgBW, 280 mg/kgBW on 72 hours are same as those on 48 hours. Each concentration has the same effect toward inflammatory healing process therefore the 70 mg/kgBW as the minimal dose is recommended as an anti inflammatory optimum dose. However, the effect of peel skin *Solanum betaceum* Cav ethanol extract even on 72 hours is still lower than dose of positive control on 48 hours. On the other hand the anti toxic effect of negative control started on 72 hours with the less of inflammatory cells that showed lower decrease than those of peel skin *Solanum betaceum* Cav ethanol extract and positive control subjects (Fig. 4).

5. CONCLUSION

Peel skin *Solanum betaceum* Cav ethanol extract has anti toxic effect on inflammatory process especially on 48 hours. The optimum dose recommended is 70 mg/kgBW that showed the same effect with those of the higher dose

(140mg/kgBW and 280 mg/kgBW). However its effect is still lower than those of sodium diclofenac as positive control.

ETHICAL APPROVAL

The ethical clearance letter was given by The Ethics Committee of the Faculty of Medicine, University of Indonesia – Cipto Mangunkusumo Hospital with regards of the Protection of human rights and welfare in medical research, No: UN2.F1/ETIK/PPM.00.02/2021.

COMPETING INTERESTS

Authors have declared that no competing interests exist.

REFERENCES

1. Werdhasari A. The role of antioxidant for health. J. Bio. Med. Ind. 2014;3(2): 59-68.
2. Asih IARA, Sudiarta IW, Wulan Suci AA. Antioxidant activity of flavonoid compound within ethanol extract of *Solanum betaceum* Cav. Journal of Chemistry. 2015; 9(1):35-40.
3. Santika PCN, Sudiono J. The Effectivity of Tamarillo (*Cyphomandra Betacea* Sendtn.) Decoction Against The Growth of *Candida albicans*. Journal of Indonesian Dental Association. 2020;3(1):7-10.
4. Mandal P, Ghosal M. Antioxidant activities of different parts of tree tomato fruit (*Cyphomandra betasea* (Cav.) sendtn. International Journal of Pharmaceutical Sciences Review and Research. ISSN. 2012;0976-044:(3-2).
5. Wiwik SR, Oktarini NWAC, Puspawati NM, Swantara IMD, Asih IARA. Antioxidant Activity of Flavonoid Compounds Ethanol Extract of Dutch Eggplant Seeds (*Solanum betaceum*, Syn) in Inhibiting Fat Peroxidation Reactions in Blood Plasma of Wistar Mice, Cakra Chemistry; 2014.
6. Arinaldo. Effect of Addition of Acetic Acid Concentration to Ethanol Solvent on the Effectiveness of Dutch Eggplant Anthocyanin Extraction. Faculty of Agricultural Technology, Andalas University, Padang; 2011.
7. Sharp P, Villano J. The Laboratory Rat Second Edition. Boca Raton: CRC Press. 2013:1.
8. Nirwana I. Activity of Pomegranate Extract (*Punica granatum* L.) As Pulp Capping Material Against Expression of IL-10, IL-6, TGF-B1, MMP-1 and Type I Collagen in Mechanical Perforated Teeth. Dissertation. Surabaya: Faculty of Medicine, Airlangga University. 2012:83.
9. Kurniawan, S.N.; Raisa, N.; Margaret. Use of Experimental Animals in Research in Neurology. Malang: Universitas Brawijaya Press. 2018: 44.
10. Pasha K, Gopal RM, Kumar RB, Ayesha Q, Srinivasulu M, Suseela K. Study of oxidative stress and antioxidant status in ascitic patients with ovarian cancer in comparison to liver cirrhosis patients. MOJ Proteome Bioinform. 2017;6(1):00186. DOI: 10.15406/ mojpb.2017.06.00186
11. Anggraini OD. Effects of Arumanis Mango Peel Extract on Carrageenin-induced Reduction of Foot Edema in Male White Mice. Faculty of Medicine, University of Jember. Thesis; 2016.
12. Guclu UGO, Mazza G. Saponins: Properties, applications and processing. Crit. Rev. Food Science. Nutrient. 2007;47:231–258.
13. Espin S, Gonzalez-Manzano S, Tacos V, Poveda C, Ayuda-Durán B, Gonzalez-Paramas AM, Santos-Buelga C. Phenolic composition and antioxidant capacity of yellow and purple-red Ecuadorian cultivars of tree tomato (*Solanum betaceum* Cav.). Food Chem. 2016;194:1073–1080.
14. Tjay TH, Grace. Essential Medicines. Efficacy, Use and Side Effects Edition V. Publisher PT. Elex Media Komputindo Gramedia Group, Jakarta; 2012.

© 2022 Sudiono et al.; This is an Open Access article distributed under the terms of the Creative Commons Attribution License (<http://creativecommons.org/licenses/by/4.0>), which permits unrestricted use, distribution, and reproduction in any medium, provided the original work is properly cited.

Peer-review history:

The peer review history for this paper can be accessed here:
<https://www.sdiarticle5.com/review-history/93916>