



Marginal Bone Level and Bone Quality Evaluation Using CBCT after Functional Loading around Dental Implant in the Population of Bhubaneswar, Odisha: A Longitudinal Study

**Snehjyoti Jha^a, Jugajyoti Pathi^a, N. C. Sangamesh^a,
Dhirendra Kumar Singh^{a*}, Abhik Sikdar^a and Monalisa Dash^{b#}**

^a Kalinga Institute of Dental Sciences, KIIT Deemed to be University, India.

^b Seth GS and KEM Hospital Parel, Mumbai, India.

Authors' contributions

This work was carried out in collaboration among all authors. All authors read and approved the final manuscript.

Article Information

DOI: 10.9734/JPRI/2022/v34i21A35834

Open Peer Review History:

This journal follows the Advanced Open Peer Review policy. Identity of the Reviewers, Editor(s) and additional Reviewers, peer review comments, different versions of the manuscript, comments of the editors, etc are available here: <https://www.sdiarticle5.com/review-history/82566>

Original Research Article

Received 02 January 2022

Accepted 06 March 2022

Published 10 March 2022

ABSTRACT

Introduction: The importance of Cone Beam Computed Tomography (CBCT) in the field of Implant Planning is a rapidly emerging imaging modality for the purpose of implant planning. Having the obvious benefits over the conventional methods of radiography, CBCT by far is the most promising aid in the efficient implant-supported prosthetic field.

Aim: The present study aimed to evaluate the bone density and the height and width around dental implants and compare it to that of the edentulous space before placing the implant.

Materials and Methods: A longitudinal study was conducted in the Department of Oral Medicine and Radiology of Kalinga Institute of Dental Sciences, Bhubaneswar. A total of 20 subjects from the CBCT database of the department with a single posterior edentulous space indicated for implant-supported dental prosthesis were selected. Approval of the Ethical Committee was taken. A pre-implant radiographic assessment was done with the help of CBCT, to evaluate the crestal height, crestal width and bone density, followed by surgical placement of the implant. After 6 months of implant placement, a post-operative radiographic assessment was done to evaluate the same parameters.

[#]Fellow in Paediatric Pathology;

^{*}Corresponding author: E-mail: dhirendra.singh@kids.ac.in;

Results: The mean difference of pre- and post-implant crestal width was 0.57 ($p < 0.001$), crestal height was 0.5 ($p < 0.001$) and bone density was 58.2 ($p < 0.001$). It was observed that the mean crestal height, width and bone density was higher in the post-operative radiographic assessment compared to the pre-operative radiographic assessment and the difference was statistically significant.

Conclusion: From the given results, it can be concluded that alveolar bone width, height and bone density were significantly improved after implant placement and the osseointegration occurring after implant prosthesis greatly improves the periodontal status of the peri-implant tissues.

Keywords: Dental implant; marginal bone; CBCT; bone density; alveolar height; alveolar width.

1. INTRODUCTION

There has recently been a surge in the field of dental prostheses and there is constantly a look-out for a better alternative to replace the conventional dentures. In this context, dental implants have really taken over the rest of the conventional methods. Not only do they provide a more efficient solution, but also give a long-term survival rate [1].

However, the success of dental implants depends largely upon a number of factors. The absence of any pathology around the implant and the efficiency with which osseointegration occurs, are very important factors in determining the success rate of a dental implant. For the same reason, it is pertinent to evaluate the implant stability, mobility, pain or any bone loss around the implant [2].

Radiographic assessment provides the clear picture of the different factors affecting the implant stability. Among all the radiographic modalities used, Cone Beam Computed Tomography (CBCT) has lately become the best opted modality. The use of CBCT has a number of benefits over the conventional radiographic techniques. Not only does it provide information on the peri-implant tissue and the degree of marginal bone loss, CBCT is efficient in determining the bone loss at different levels and help in early detection of bone loss around implants [3]. However, there is very limited literature available comparing the alveolar bone quality pre- and post-implant placement. In the present study, we aim to evaluate the bone density and the height and width around dental implants and compare it to that of the edentulous space before placing the implant [1-4].

2. MATERIALS AND METHODS

A longitudinal study for evaluating the pre- and post-implant bone density, bone height and width

was done in Kalinga Institute of Dental Sciences, Bhubaneswar. The duration of this study was of 6 months (January 2021- August 2021). For the present study, 20 individuals were selected from the departmental OPD of Oral Medicine and Radiology.

2.1 Sample Size Estimation

Type: Empirical Data Used.

Comparisons of the MEAN DIFFERENCE between the different groups were taken into consideration. Sample size determination was done using G Power software (version 3.0) to achieve a power of 80% and a level of significance of 5%.

Type of test = two-sided

2.2 Inclusion and Exclusion Criteria

Inclusion criteria included; patients within the age group of 18 to 45 years having single posterior edentulous space (molar or premolar region) with completely healed bone (at least 6 months after the loss/extraction of tooth) having a residual crestal bone height of 7 mm, and thickness of at least 6 mm, who were able to understand the study protocol and willing to give informed consent were included in the study.

Exclusion criteria included; patients with history of acute myocardial infarction, coagulation disorders, uncontrolled diabetes, psychological disorders (like Schizophrenia), aggressive periodontitis, head and neck radiotherapy in the past 2 years, immunocompromised patients (graft versus host disease). Patient on long-term non-steroidal anti-inflammatory drug therapy, individuals with history of past or present treatment using oral or intravenous bisphosphonate drugs. Chronic smokers, alcoholics, tobacco abusers or any other recreational drug abuser.

2.3 Pre-operative Radiographic Assessment

Each patient was advised to undergo a radiographic assessment using CBCT before implant placement. MyRay Hyperion X9 CBCT machine was used for the present study. Exposure parameters were 76 kVp, 6 mA and 9.3 seconds exposure time. The software used for CBCT image acquisition was iRYS (version 2.0). The Field of View (FOV) selected for the present study was 11x8 mm. Cone beam computed images were evaluated using the classical orthogonal planes (axial, sagittal and coronal), Multiplanar Reformation (MPR) to provide panorama-like thin slice images and stacked sequential images and 3D volume rendering.

The radiographic parameters were measured by two radiologists. Random 20 cases were investigated by both radiologists before the start of the study in which a value of 0.7 was obtained. Later on, the same radiologists made the measurements for the research. Investigator blinding was done. In order to avoid investigator bias, the cases were selected based on the inclusion and exclusion criteria.

To establish a reproducible reference system for measurements, a reference point was established. For each edentulous site, the cemento-enamel junction (CEJ) of the adjacent teeth on either side of the edentulous space were taken as a reference point for estimation of the crestal height. A virtual implant was simulated and placed in the same region where the actual implant would be placed and the distance from the line joining the CEJ of the adjacent teeth and the virtual implant was pre-recorded for measuring the crestal height. For estimation of the crestal width, the distance between the

buccal and lingual cortical plates was measured in the axial section of CBCT. In the pre-operative radiographs, the width was measured around the virtual implant in order to maintain the same region of interest in the post-operative radiograph. Taking this measurement as a guide for pre- and post-operative radiographs, the region of interest was kept as accurate as possible to avoid discrepancy in results.

For each site, the crestal width and crestal height was measured (Fig. 2). For maxillary arch, the crestal width was measured as the bucco-palatal extent of the alveolar crest in the coronal section, and the crestal height was measured as the distance between the alveolar crest and the floor of the maxillary sinus. Similarly, for mandibular arch, the crestal width was measured as the buccolingual extent of the alveolar crest in the coronal section, and the crestal height was measured as the distance between the alveolar crest and the roof of the mandibular canal [5,6].

Bone density was determined by amount of mineral mass content in a certain volume of a structure, which is described in Hounsfield units (HU) and represents the relative density of a body tissue according to a calibrated gray-level scale based on HU units of air (-1000 HU), water (0 HU) and dense bone (+1000 HU) [6]. For standardization of the measurement, a virtual implant (using iRYS software) was placed in the selected edentulous space, simulating the actual implant planned for the same site [7]. For the pre-implant radiographic assessment, images representing 1 mm buccolingual slices immediately mesial or distal to the implants were selected for estimation of bone density. The region was traced (area ranging from 25-30 mm²) and the mean Hounsfield Unit was recorded [4] (Figs. 1&2).

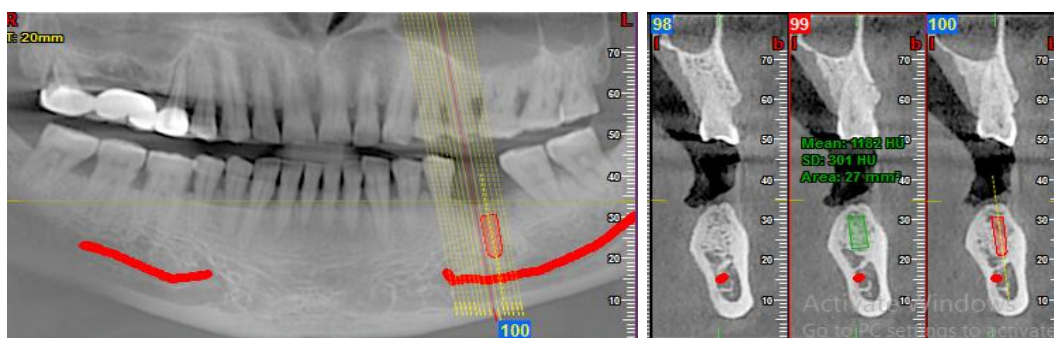


Fig. 1. Pre-operative bone density assessment. Area marked in green represents the site of implant placement where bone density is measured. Area marked in red represents the simulated implant

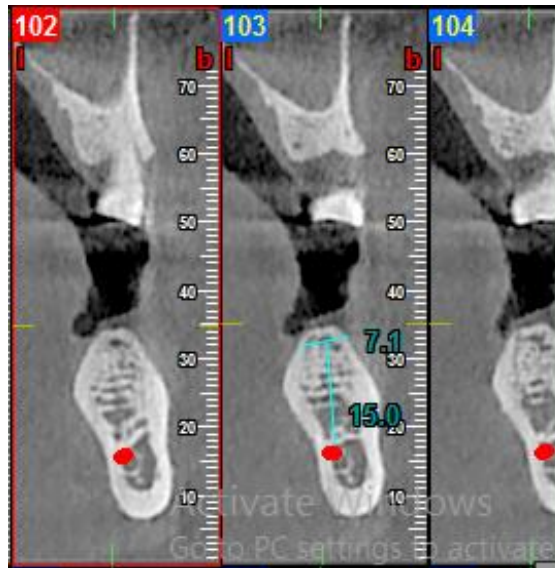


Fig. 2. Pre-operative crestal height and width

2.4 Surgery

All patients received antibiotic prophylaxis (2g of amoxicillin 1 hour prior to surgery) [8]. Local infiltration was given (2% lidocaine with 1:100000 adrenaline) and a crestal incision was made. Using a periosteal elevator, a vestibular full thickness flap was elevated. A full thickness lingual flap was elevated and the site was prepared for xenograft placement along with platelet rich fibrin for acceleration of osteoblastic activity for better bone formation.

Following 1 month of graft placement implant placement was done. Osstem implant of size 5.5x10 mm dimension having corkscrew thread were placed at least 1.5 mm away from the adjoining teeth on either side and the was surrounded by at least 1 mm of bone on both lingual and buccal sides. Primary stability was

achieved by Resonance Frequency Analysis for all implants placed, with torque values above or equal to 25 Ncm [9,10,11] . After 2 months of implant placement healing abutment was placed and after 4 months of implant placement delayed loading of prosthesis was done.

2.5 Post-operative Radiographic Assessment

After the placement of the implant prosthesis 6 months after the implant placement, the subjects were asked to undergo another radiographic assessment using Cone-beam computed tomography. The same parameters were kept in consideration as the pre-operative radiographic assessment and in the same manner the crestal height, crestal width and the bone density were evaluated and recorded [4] (Figs. 3 & 4).

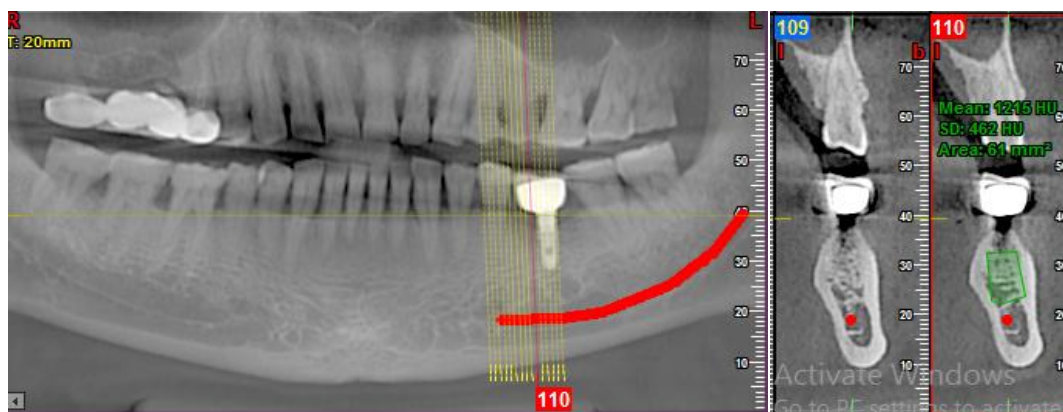


Fig. 3. Post-operative bone density

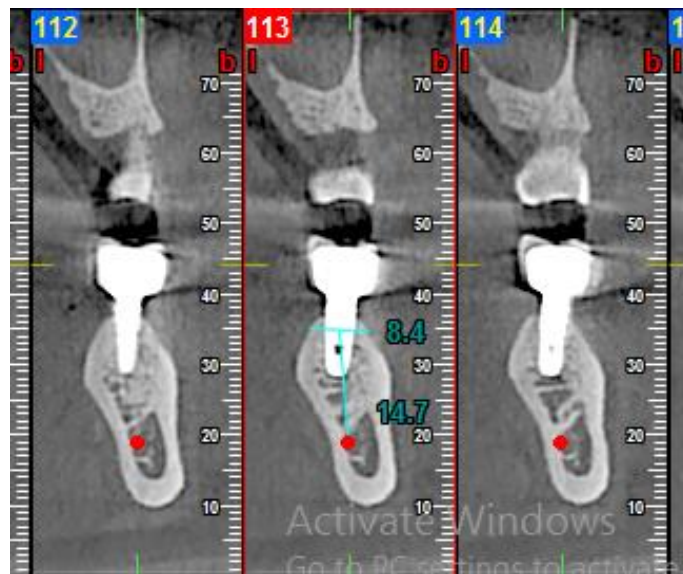

Fig. 4. Post-operative crestal height and width

In the present study, for the post-implant radiographic assessment, images representing 1 mm buccolingual slices immediately mesial or distal to the implants were selected for estimation of bone density [4].

3. RESULTS

In the present study, a total of 20 patients were evaluated using CBCT, both pre- and post-implant placement. Out of the 20 subjects, 10 were male and 10 were female.

3.1 Distribution of the Mean Scores as Compared Pair Wise

a. Distribution of the means scores of crestal width as compared at different time intervals

Table 1. Distribution of the means scores of Crestal width as compared at different time intervals

Crestal Width	Mean	Std. Deviation	Std. Error Mean	Correlation**	P Value
Before Implant Placement	7.16 mm	0.765	0.171	0.918	<0.001*
After Implant Placement	7.73 mm	0.726	0.162		

**statistically significant*

***Correlation value suggests the linear relationship of pre and post implant placement crestal bone width*

b. Distribution of the mean scores of crestal height as compared pair wise

Table 2. Distribution of the mean scores of crestal height as compared pair wise

Crestal Height	Mean	Std. Deviation	Std. Error Mean	Correlation**	P Value
Before	13.20 mm	1.088	0.243	0.992	<0.001*
After	13.77 mm	0.9614	0.215		

**statistically significant*

***Correlation value suggests the linear relationship of pre and post implant placement crestal bone height*

c. Mean Score distribution of the baseline and post-operative variables of bone density

Table 3. Mean Score distribution of the baseline and post-operative variables of bone density

Bone Density	Mean	Std. Deviation	Std. Error Mean	Correlation	P Value
Before	869.30 HU	148.346	33.171	0.977	<0.001*
After	927.50 HU	175.266	39.191		

**statistically significant*

***Correlation value suggests the linear relationship of pre and post implant placement crestal bone density*

The t- value for paired t- test have been presented in Table 4 and the mean in Table 4 represents the delta mean value for the pre and post operative bone level.

Table 4. t-test value for pre and post implant site bone

Variable	Paired Differences					t	df	Sig. (2-tailed)
	Mean	Std. Dev	Std. Error Mean	95% confidence interval of the difference				
				Lower	Upper			
Pre-implant Crestal Width (mm) – Post-implant Crestal Width (mm)	0.57	0.30	0.068	0.71	-.42	-8.37	19	<0.0001*
Pre-implant Crestal Height (mm) – Post-implant Crestal Height (mm)	0.56	0.17	0.039	0.64	-.48	-14.14	19	<0.0001*
Pre-implant Bone density (HU) – Post-implant Bone density (HU)	58.20	43.87	9.811	78.73	-37.66	-5.93	19	<0.0001*

**statistically significant*

4. DISCUSSION

Implant planning requires the precision and the exactness that can only be provided by a tri-dimensional radiographic technique. The proximity of the implant to vital structures such as the mandibular canal and the maxillary sinus makes it absolutely pertinent for clinicians to be undeniably sure of the correct position of these structures in relation to the implant. Also, the post-operative evaluation of the implant is equally necessary to ensure the success of the prosthesis and for that the assessment of the surrounding bone quality is required. Comparing the bone levels and the bone mineral density of the alveolar bone surrounding the implant to that of the edentulous space prior to the placement of the implant gives us a fair idea of the changes in the quality of the bone. And, for all these requirements CBCT has proven to be the appropriate technique capable of evaluating the peri-implant bone measurements [5,6,7,9].

According to the European Association for Osseointegration recommendations for the use of pre-operative cross-sectional imaging (including CBCT), all guided implant surgeries should be accompanied by computer assisted planning for placement of dental implants [11,12,13].

The subjects ranged between the age group of 18-45 years, the mean age being 40 years. On comparing the mean scores of the Crestal width pre- and post-implant, it was seen that a statistically significant correlation existed between the two time-intervals (p<0.0001*) in that the mean crestal height after implant placement was higher than the mean crestal height before implant placement. This finding was in accordance to the study conducted by Bergkvist et al. [14] and contrary to the findings of the study conducted by Dwingadi et al. [1] and by Youssef et al. [2].

When the pre-implant Crestal height was compared to the Crestal height post-implant, it was seen that a statistically significant correlation (correlation between pre and post implant placement crestal height) existed between the two time-intervals ($p < 0.0001^*$) in that the mean crestal height after implant placement was higher than the mean crestal height before implant placement. This finding was in accordance to the study conducted by Bergkvist et al. [14] and contrary to the findings of the study conducted by Dwingadi et al. [1] where mesial bone loss of 1.08 mm and distal bone loss of 1.36mm was noted.

For the bone density evaluation, comparing the mean values of pre- and post-implant bone mineral density revealed that a statistically significant correlation existed between the two time-intervals ($p < 0.0001^*$; correlation coefficient = 0.977) in that the mean bone density before implant placement was higher than the mean bone density after implant placement. This finding was in accordance to the study conducted by Youssef et al. [2] (mean bone density value was 827.96 ± 206.85 immediately post-operatively, then increased to 890.67 ± 138 & 1018.0 ± 149.79 on the 3rd and 6th months respectively after implant placement, there was a statistical significant increase in bone density) and contrary to the findings of the study conducted by Dwingadi et al. [1], and Bergkvist et al. [14].

The placement of Xenograft and platelet rich fibrin in the implant site prior to the implant placement is primarily responsible for the increase in the crestal width, crestal height and bone density. After primary stability, osteosynthesis occurs. The xenograft has a property of osteo-conduction which promotes osteogenesis and increases the osteoblastic activity. It acts as a scaffold for the progenitor osteoblastic cells resulting in new bone formation. The PRF induces the release of various growth factors and promotes angiogenesis. As a consequence, the crestal width and height shows increment following placement of the implant as well as the density of adjacent bone shows osseodensification in the initial periods of healing.

The differences in the results obtained in the present study in comparison to the available literature may be owing to the difference in the study population, the procedure followed in different studies, the type of implant placed and sample size.

5. CONCLUSION

Alveolar bone width, height and bone density are fairly improved after implant placement and the osseointegration occurring after implant prosthesis and xenograft placement. CBCT is indeed one of the most vital imaging modalities that aids in implant planning and the evaluation of dental implants post-treatment. However, research in this sphere of work remains dishearteningly scarce and more emphasis should be given to conducting more such studies in the near future. Also, there is need for more extensive research with a higher sample size to be able to determine the pre- and post-implant changes in the alveolar bone.

6. LIMITATION OF STUDY

The present study was only followed up for a period of 6 months. The parameters need to be re-evaluated for a longer follow-up period to assess whether the changes are retained or the alveolar bone shows degenerative changes in later periods. The short period of follow-up is a limitation of this study.

DISCLAIMER

The products used for this research are commonly and predominantly use products in our area of research and country. There is absolutely no conflict of interest between the authors and producers of the products because we do not intend to use these products as an avenue for any litigation but for the advancement of knowledge. Also, the research was not funded by the producing company rather it was funded by personal efforts of the authors.

CONSENT

Informed consent of all patients was taken. A detailed case history of each patient was recorded.

ETHICAL APPROVAL

Institutional Ethical Committee clearance (IEC letter no. 172, dated 8/10/2020) was obtained for this study.

COMPETING INTERESTS

Authors have declared that no competing interests exist.

REFERENCES

1. Dwingadi E, Soeroso Y, Lessang R, Priaminiarti M. Evaluation of Alveolar Bone on Dental Implant Treatment using Cone Beam Computed Tomography. *Pesqui Bras Odontopediatria Clín Integr.* 2019; 19(4917):1–10.
2. Youssef M, Shaaban AM, Eldibany R. The Correlation between bone density and Implant stability. *Alexandria Dent J.* 2015; 40(1):15–21.
3. Dave M, Davies J, Wilson R, Palmer R. A comparison of cone beam computed tomography and conventional periapical radiography at detecting peri-implant bone defects. *Clin Oral Implants Res.* 2012;00: 1–8.
4. Venkatesh E, Elluru SV. Cone Beam Computed Tomography: Basics and Applications in Dentistry. *J Istanbul Univ Fac Dent.* 2017;51(3):102–21.
5. Jacobs R, Salmon B, Codari M, Hassan B, Bornstein MM. Cone beam computed tomography in implant dentistry: recommendations for clinical use. *BMC Oral Health.* 2018;18(88):1–16.
6. Campos MJ da S, De Souza TS, Luiz S, Fraga MR, Vitral RW. Bone mineral density in cone beam computed tomography: Only a few shades of gray. *World J Radiol.* 2014;6(8):607–12.
7. D'haese J, Ackhurst J, Wismeijer D, De Bruyn H, Tahmaseb A. Current state of the art of computer-guided implant surgery. *Periodontol 2000.* 2017;73(1): 121–33.
8. Ríordáin, R., McCreary, C. NICE guideline on antibiotic prophylaxis against infective endocarditis: attitudes to the guideline and implications for dental practice in Ireland. *Br Dent J.* 2006;20(11):1-6.
9. Bornstein M, Buser D. Implant Dentistry - The Use of Cone Beam Computed Tomography (CBCT): 1–36.
10. Verardi S, Testori T, Stacchi C, Orsini M, Pulici A, Lombardi T, et al. Comparison between two different techniques for peri-implant soft tissue augmentation: Porcine dermal matrix graft versus tenting screw. *J Periodontol.* 2019;00(February 2020):1–7.
11. Roberto C, Paolo T, Giovanni C, Ugo C, Bruno B. Bone remodeling around implants placed after socket preservation: A 10-year retrospective radiological study. *Int J Implant Dent.* 2021;7(74):1–8.
12. Bornstein M, Horner K, Jacobs R. Use of cone beam computed tomography in implant dentistry: Current concepts , indications and limitations for clinical practice and research. *Periodontol.* 2000,2017;73:51–72.
13. Morton D, Chen MSST, Martin WC, Levine MSRA, Buser FD. Consensus Statements and Recommended Clinical Procedures Regarding Optimizing Esthetic Outcomes in Implant Dentistry. *Gr 3 Consens Statements.* 2014;29:216–20.
14. Bergkvist G, Koh K-J, Sahlholm S, Klintstrom E, Lindh C. Bone Density at Implant Sites and Its Relationship to Assessment of Bone Quality and Treatment Outcome. *Int J Oral Maxillofac Implants.* 2010;25(2):321–8.

© 2022 Jha et al.; This is an Open Access article distributed under the terms of the Creative Commons Attribution License (<http://creativecommons.org/licenses/by/4.0>), which permits unrestricted use, distribution, and reproduction in any medium, provided the original work is properly cited.

Peer-review history:

The peer review history for this paper can be accessed here:
<https://www.sdiarticle5.com/review-history/82566>