



Effect of *Cymbopogon citratus* (Lemon Grass) Extract and Diminazene Aceturate (Berenil) on *Trypanosoma brucei brucei* In vivo

P. O. Rume ^a, T. M. Preye ^{a*}, B. C. Iwuoha ^a, J. J. Okeke ^b and J. A. Wahedi ^c

^a Department of Trypanosomiasis Research, Nigerian Institute for Trypanosomiasis Research, South-South Zone, Asaba, Delta State, Nigeria.

^b Department of Zoology, Nnamdi Azikiwe University Awka, Anambra State, Nigeria.

^c Department of Biological Sciences, Federal University of Health Sciences Otukpo, Benue State, Nigeria.

Authors' contributions

This work was carried out in collaboration among all authors. All authors read and approved the final manuscript.

Article Information

Open Peer Review History:

This journal follows the Advanced Open Peer Review policy. Identity of the Reviewers, Editor(s) and additional Reviewers, peer review comments, different versions of the manuscript, comments of the editors, etc are available here: <https://www.sdiarticle5.com/review-history/84979>

Received 22 January 2022

Accepted 26 March 2022

Published 20 April 2022

Original Research Article

ABSTRACT

The effect of *Cymbopogon citratus* (lemon grass) extract and berenil was investigated on albino rats, infected with *Trypanosoma brucei brucei* in the Laboratory. A total of thirty five (35) rats were used, 8 - 10 weeks old weighing between 120 to 180grams were allowed to acclimatize for a period of one week. These were divided into seven groups (A and B controls, while C, D, E, F and G groups were infected and treated with 0.5ml and 0.2ml of the aqueous extract of *C. citratus* and berenil respectively. One milliliter (1ml) of *T.b. brucei* infected blood was diluted with phosphate buffered saline and was inoculated via the intra-peritoneal route; parasite was detected by wet film method and examined under the light microscopic field using X40 magnification to check the wriggling movement of trypanosomes. Treatment C. had the highest mean PCV (52.93±4.23%) while B. had the least (49.60±4.611%). A. had the highest mean white blood cell value (9.21±1.959x10⁹/L) while D. had the least (8.56±2.915X10⁹/L). Treatment A. also had the highest mean red blood cell value (2.58±1.959X10⁹/L), G. (2.50±3.615X10⁹/L), while C. had the least (2.38±3.869X10⁹/L). Treatment B. had the highest mean weight gain (3.99±0.201g), A. (2.73±0.462g) while E. had the least (0.20±0.346g). Group B. had the highest mean parasitaemia count (77.75±36.130), C. (35.75±40.419) while A. and D. had the least (0.00±0.000). Mortality rate was higher in group B.

*Corresponding author: E-mail: memberpreye@gmail.com;

(3.67±1.506) and F. (2.50±1.049) while A, D, E and G. had the least (0.00±0.000). There was significant difference (P = 0.00) in the mortality rate among the groups. The ability of lemongrass extract to increase the lifespan of the infected rats in this study may be due to phytochemical contents of the extract. It is therefore recommended that lemon grass extract be used as anti-trypanosomal agent.

Keywords: *Cymbopogon citratus*; liver; berenil; albino-rats; *Trypanosoma brucei*.

1. INTRODUCTION

African trypanosomiasis is a vector - borne parasitic disease. They are transmitted through the bite of tsetse fly (*Glossina*). Their infection can be acquired from humans or animals harboring the pathogenic parasites. It is a potentially fatal disease of humans and domestic animals, exclusively found in tropical region of Africa. This disabling and fatal disease belongs to the most Neglected Tropical Diseases (NTDs) and has been shown to promote rural underdevelopment [1].

Animal African trypanosomiasis (AAT) is a disease of livestock [2]. The disease comes with huge annual economic losses. The distribution of trypanosomiasis in Africa corresponds to the range of tsetse flies and comprises currently an area of 8 million km² between 14 degrees north and 20 degrees South latitude [2]. Trypanosomiasis and drought are major limiting factors for cattle production [3]. The economic impacts of the disease affect milk and meat production, reduce birth rate and increase abortion as well as mortality rate in animals [3].

A high tsetse - trypanosome burden constrains the use of land for livestock production, with farmers in these areas often being more reliant on crop farming [4]. However, trypanosomiasis also compromises crop production by reducing the availability of draft animals to plough fields and provide manure for fertilizer [5].

A lot of revenue is lost annually due to the high mortality rate and low productivity of trypanosome infected livestock in many parts of Africa. Over US \$1.3 billion loss is incurred annually in Africa directly from cattle death, reduced meat and milk production [6]. It is currently estimated that about 48 million cattle are at risk of contracting African trypanosomiasis [7]. Millions of cattle herds harbor this disease and about 3 million deaths are recorded annually [8].

Several plants have been used traditionally in Nigeria for the treatment of trypanosomiasis. Nigeria's biodiversity is rich in medicinal plants; over 25% of our common medicines contain at least some compounds obtained from plants [8]. Such medicinal plants are easily accessible and more affordable when compared with biochemical drugs, hence the search for medicinal plants.

Cymbopogon citratus is a plant of considerable economic importance, in Nigeria, as in many other African countries, herbal treatment of various diseases is still common, the potential anti-trypanosomal activities of some of these have been evaluated scientifically; the antiprotozoal activity of lemon grass has been tested on strains of *Crithidia deanei* [9]. The anti-proliferative effect of the essential oil of *C. citratus* has also been tested on *Trypanosoma cruzi* (Chagas disease). The results indicated that the essential oils can be promising anti-parasitic agents, opening perspectives to the discovery of more effective drugs of vegetal origin for treatment of parasitic diseases [10].

Lemongrass (*Cymbopogon citratus*) essential oil has been shown to be effective against the amastigote and trypomastigote forms of *Trypanosoma cruzi*, the American form of trypanosomiasis [11]. Therefore, this study was designed to investigate the effects of lemon grass extract on *Trypanosoma brucei brucei*.

The significance of this study was to demonstrate the prophylactic and chemotherapeutic effect of lemon grass, due to increasing rate of trypanocidal resistance. The target audience are, students, farmers, hunters, rural dwellers and the herbal-pharmaceutical community.

2. MATERIALS AND METHODS

2.1 Collection of Plant Materials

Fresh leaves of *Cymbopogon citratus* were collected from Dr. Amatu's farm in Asaba, Delta State. These subsequently identified by the

resident plant taxonomist in Nigerian Institute for Trypanosomiasis Research south-south zonal office Asaba Delta State, Nigeria.

2.2 Preparation of Aqueous Extract of *Cymbopogon citrates*

The fresh leaves of the lemongrass were carefully washed with tap water and cut into tiny pieces, air – dried at room temperature to avoid the reduction of the phytochemical components. The dried leaves were grounded into powder using Model 8120 warring blender. One kilogram (1kg) was weighed and mixed with one liter of distilled water and sieved through a Buchner funnel to remove debris [12].

2.3 Experimental Animal

A total of thirty five (35) albino wistar rats, 8-10 weeks old weighing between 120-180grams were obtained from Chiagoziem Azubuike farm at Asaba, Delta State. The rats were transported to the Nigerian Institute for Trypanosomiasis Research (NITR) Laboratory in a transportation box measuring 40 x 20 x 20cm to ensure adequate ventilation. The rats were acclimatized for a period of one week before the experiment. They were housed in fly proof cages in the animal house of NITR, Asaba and were maintained on commercial animal care feed (starters feed) (Wheat, Corn, Sorghum, Barley, Rye, Triticale, Oats and Water) periodically. The transportation of the rats was done in the morning to minimize stress. Prior to infection the rats were screened for blood parasites in the laboratory of NITR, Asaba zonal office and all the rats were free of infection.

2.4 Experimental Design

Trypanosoma brucei parasite was obtained with permission from the trypanosome bank of NITR, head office, Kaduna. It was then inoculated into some rats and transported down to Asaba. The animals were randomly stocked into seven fly proof cages containing five rats each and labeled as follows: Group A control (uninfected, untreated). Group B control (infected untreated). Group C infected and treated with 0.2ml and 0.5ml of the *C. citratus* extract (orally) prior infection; Group D treated with 0.2ml berenil (intramuscularly) prior infection; Group E was treated after infection with extracts of *C. citratus* 0.5ml and 0.2 berenil, respectively; Group F was infected and treated with 0.5ml extract of *C. citratus* and berenil after infection orally; and

Group G was treated after infection with 0.5 ml berenil (Intramuscularly).

2.5 Inoculation

One milliliter (1ml) of *T.b. brucei* infected blood was taken from the donor rat and diluted with phosphate buffered saline. The diluted blood containing approximately 1.25×10^6 parasites was inoculated via the intraperitoneal route [13,14] into the rats in groups B-G. This was done on the third day after infection was seen in the donor rat. Inoculation was done intraperitoneally. Parasitaemia was estimated using blood from the tail and checked microscopically [15]. Parasitaemia was determined on the third day.

2.6 Parasitaemia Count

Parasite was detected by wet film method from the tail blood collected from each rat in each of the test groups. When fresh infected blood from each rat was placed on a microscopic slide, a cover slip was placed over and examined under the light microscopic field using X40 magnification to check the wriggling movement of trypanosomes. This movement was observed between the blood cells [16].

2.7 Histological Analysis

Necropsy (using the paraffin method) was done on representative of the control rats and from all the tests groups, when dissected, the liver was removed and stored in 10% formalin, it was taken to the histopathology laboratory of the Federal Medical Centre, Asaba to check the level of infection and damage of the organ.

2.8 Statistical Analysis

Data collected were subjected to analysis of variance (ANOVA) using SPSS version 21. The Least Significant Difference (LSD) was used to separate mean differences between the treatments at 5% significant level [17].

3. RESULTS

Table 1 showed the Mean Pack Cell Volume of albino rats infected with *T. brucei* exposed to lemon grass and berenil. The result revealed that treatment C had the highest mean final PCV ($52.93 \pm 4.234\%$), which was significantly different from treatment A, while treatment B had the least ($49.60 \pm 4.611\%$) which was also not significantly different from the other treatments. There was no significant difference ($P=0.14$) in the PCV loss among the treatments.

Table 1. Mean Pack Cell Volume of albino rats infected with *Trypanosoma brucei brucei* when exposed to lemon grass and berenil

Treatments	Mean PCV \pm (%)
Treatment A	51.80 ^a \pm 2.111
Treatment B	49.60 ^{ab} \pm 4.611
Treatment C	52.93 ^b \pm 4.234
Treatment D	50.53 ^{ab} \pm 3.399
Treatment E	50.80 ^{ab} \pm 3.668
Treatment F	50.93 ^{ab} \pm 2.120
Treatment G	51.47 ^{ab} \pm 2.503

Columns sharing similar superscripts are not significantly different at $P>0.05$

Table 2. Mean Weight Gain of albino rats infected with *Trypanosoma brucei brucei* when exposed to lemon grass and berenil

Treatments	Before experiment	After experiment	Weight gain
Treatment A	127.73 \pm 3.474	130.47 \pm 4.068	2.73 ^c \pm 0.462
Treatment B	127.13 \pm 5.235	131.20 \pm 5.226	3.99 ^d \pm 0.201
Treatment C	131.2 \pm 6.167	132.13 \pm 5.604	1.07 ^{ab} \pm 1.137
Treatment D	131.33 \pm 7.188	133.53 \pm 6.896	2.36 ^c \pm 0.661
Treatment E	130.67 \pm 7.287	130.67 \pm 7.158	0.20 ^a \pm 0.346
Treatment F	130.00 \pm 7.319	131.67 \pm 7.490	2.28 ^c \pm 0.139
Treatment G	128.67 \pm 8.121	130.67 \pm 8.466	1.87 ^{bc} \pm 0.115

Columns sharing similar superscripts are not significantly different at $P>0.05$

Table 3. Mean Parasitemia count in albino rats infected with *Trypanosoma brucei brucei* when exposed to lemon grass and berenil

Treatments	Mean Parasitaemia count at various days after inoculation				Mean Parasitaemia count \pm SD
	3	4	5	6	
Treatment A	0.00 \pm 0.000	0.00 \pm 0.000	0.00 \pm 0.000	0.00 \pm 0.000	0.00 ^a \pm 0.000
Treatment B	31.93 \pm 2.251	57.47 \pm 6.556	97.33 \pm 4.938	124.27 \pm 3.081	77.75 ^c \pm 36.130
Treatment C	0.00 \pm 0.000	0.00 \pm 0.000	46.27 \pm 5.873	96.73 \pm 2.915	35.75 ^b \pm 40.419
Treatment D	0.00 \pm 0.000	0.00 \pm 0.000	0.00 \pm 0.000	0.00 \pm 0.000	0.00 ^a \pm 0.000
Treatment E	27.67 \pm 4.402	0.00 \pm 0.000	0.00 \pm 0.000	0.00 \pm 0.000	6.92 ^a \pm 12.270
Treatment F	0.00 \pm 0.000	0.00 \pm 0.000	46.73 \pm 5.049	93.80 \pm 2.731	35.13 ^b \pm 39.303
Treatment G	22.73 \pm 1.831	0.00 \pm 0.000	0.00 \pm 0.000	0.00 \pm 0.000	5.68 ^a \pm 9.969

Columns sharing similar superscripts are not significantly different at $P>0.05$

Table 4. Mean mortality count in albino rats infected with *Trypanosoma brucei brucei* when exposed to lemon grass and berenil

Treatments	7 days after inoculation	8 days after inoculation	Mean Mortality of rats \pm SD
Treatment A	0.00 \pm 0.000	0.00 \pm 0.000	0.00 ^a \pm 0.000
Treatment B	2.33 \pm 0.577	5.00 \pm 0.000	3.67 ^c \pm 1.506
Treatment C	1.33 \pm 0.577	3.33 \pm 0.577	2.33 ^b \pm 1.211
Treatment D	0.00 \pm 0.000	0.00 \pm 0.000	0.00 ^a \pm 0.000
Treatment E	0.00 \pm 0.000	0.00 \pm 0.000	0.00 ^a \pm 0.000
Treatment F	1.67 \pm 0.577	3.33 \pm 0.577	2.50 ^b \pm 1.049
Treatment G	0.00 \pm 0.000	0.00 \pm 0.000	0.00 ^a \pm 0.000

Columns sharing similar superscripts are not significantly different at $P>0.05$

Table 3 shows the mean parasitaemia count in albino rats infected with *T. brucei brucei* when treated with lemon grass and berenil. The results revealed that treatment B had the highest mean parasitaemia count (77.75 ± 36.130) which was significantly different followed by treatment C (35.75 ± 40.419) while treatment A and D had the least (0.00 ± 0.000). There was significant difference ($P=0.00$) in the parasitaemia count among the treatment groups.

And in Table 4, the mean mortality count in albino rats infected with *T. brucei brucei* when exposed to lemon grass and berenil. The results revealed that treatment B had the highest mean mortality (3.67 ± 1.506) and was significantly different, followed by treatment F (2.50 ± 1.049) while treatment A, D, E and G had the least (0.00 ± 0.000). There was significant difference ($P=0.00$) in the mortality among the treatments.

Plate 1: Group B, Infected and Untreated.

A cross section of liver showing marked congestion, the red pulp is filled with red blood

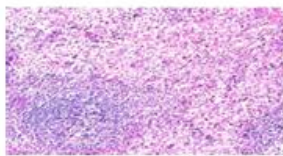


Plate 1

cells (a) and follicular hyperplasia and formation of giant cells (b) in group which is quite different from the control group A where the red pulp is surrounded by dense connective tissue. There is also pronounced enlargement of white pulp (c), there is extensive hemorrhage and presence of hemosiderin pigments.

Plate 2: Group C, treated with extract before infection.

A section of liver from group treated with aqueous extract *Cymbopogon citratus* showing numerous scattered parasites in splenic red pulp in (a), extensive haemorrhage (b) and presence of hemosiderin pigments (c) as a result of the altered structure of the spleen. This is marked by the blue marker.

Plate 3: Group D, treated with berenil before infection.

A section of liver from the group treated before infection showed no difference in the spleen from that of the control or that of the infected rats.

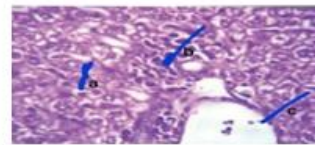


Plate 2

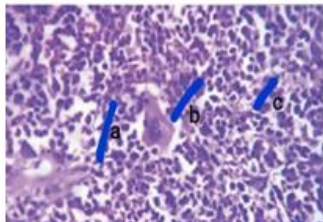


Plate 3

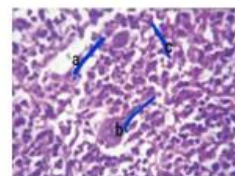


Plate 4

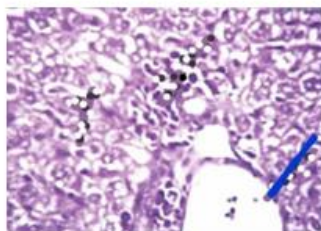


Plate 5

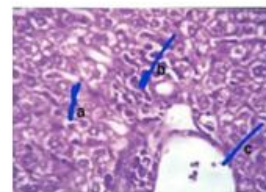


Plate 6

Plate 4: Group E, treated with extract and berenil after infection.

A cross section of liver from Group E showing macrophages (a), increased number of apoptotic cells (b) and mild congestion (c) was found in this group and marked by the blue marker. There was also a marked absence of parasites from this group.

Plate 5: Group F, treated with extract after infection.

A section of liver from group treated with extract after infection showing marked congestion (a), extensive hemorrhage (b) and the presence of numerous parasites (c), this plate is similar to the group C which was treated with extract before infection and also similar to the second control.

Plate 6: Group G, treated with berenil after infection.

A section of liver showing enlargement of white cells marked by blue marker. There was a marked absence of parasites as the drugs cleared out all the parasites but damage had already occurred in the liver.

4. DISCUSSION

The plant *Cymbopogon citratus* has a trypanostatic effect, which suppresses the ability of the parasite thereby sustaining the life of the rats when compared to the infected and untreated control group, it is worthy to mention that some plants have already been investigated for their antitrypanosomal activities in other studies for instance, water, methanol and dichloromethane extracts of the leaves of *T. avicenioides* have been tested but only methanolic extracts were active on *T. b. brucei* [18]. Stem bark extracts of the same plant species has shown invitro effects against *T. b. brucei* [19]. Examination of wet blood films (WBF) revealed presence of trypanosomes at 72 hours postinfection in rats from group B, E, F & G. whereas motile trypanosomes were observed in WBF at 120 hours post infection in group C and there was a high parasitaemia (teaming) at approximately 148 hours post-infection. Rats from uninfected control group A remained negative for trypanosome till sacrificed at 240 hrs. Rats belonging to group B (second control) showed a typical pattern of infection and death with trypanosome infection, with obvious decrease in PCV and weight loss as seen in

Tables 1 and 2. Due to pretreatment with berenil, group D had no infection (till the end of the experimental period). The delay of parasitaemia in group C shows that the extracts mostly had an effect on the onset of parasitaemia by probably boosting the immune system of the host. This is in agreement with some earlier reports that *Cymbopogon citratus* play a role in peroxidation by inhibiting free radical attacks on biomembranes Calsamiglia et al., [20,21] especially the red blood cells, and are not likely to pose any health risk Bankole and Joda [22]. The extract also appeared to have no effect on the PCV of the rats treated before infection. This was however, statistically insignificant. The extracts appear to have extended the life span of the rats in group F (treated with the extract) also showed a steady and stable white blood cell count. This is in agreement with earlier report by Nathan et al., [23] that *Cymbopogon citratus* had a greater effect of decreasing parasitic number more than EC, CS and ED and decreased cell number of *trypanosoma brucei brucei* and *T. evansi* in a dose dependent pattern. However, this was not the case with group G treated with berenil after infection, where parasites were cleared and no death recorded till the end of the experiment, with high blood cell count, as shown in Table 3. This is in agreement with the findings of Shamaki et al. [24] who reported significant ($P > 0.05$) difference in the white blood cell (WBC) count (lymphocytes) of infected rats. Shamaki et al. [24] also noted that the WBC count was observed to be higher in treated rats than in negative control rats. Lymphocytes are active cells that provide fast and powerful defense against foreign bodies and pathogens that cause infection. This is also in agreement with the findings of Wasser et al. [25] who reported significant ($P < 0.5$) difference in WBC count of rats treated with some tropical plants. The liver of group B rats showed pronounced enlargement of white pulp, extensive hemorrhage presence of hemosiderin pigment and large presence of parasites. Pathological examination of the liver of group C was similar to that of B. There was no difference in the lives of group D compared to that of A, group E showed free fatty vacuolar degeneration and lesser necrosis. F showed dilated and congested central vein containing scattered parasites surrounded by inflammatory cells and degenerated hepatocytes. The present study demonstrated that the aqueous extract of the *Cymbopogon citratus* used significantly inhibited *T. b. b.* organism, similar results were recorded by Adamu et al. [26] using garlic.

5. CONCLUSION

In conclusion, lemon grass extract has great potential in the treatment of trypanosomal infections. The ability of lemongrass extracts to increase the life span of infected rats can be attributed to high phytochemical contents of the extracts. However, pharmacological companies should focus more on research into medicinal herbs that have shown trypanocidal properties and more work should be done on lemongrass to determine its full trypanocidal properties.

DISCLAIMER

The products used for this research are commonly and predominantly use products in our area of research and country. There is absolutely no conflict of interest between the authors and producers of the products because we do not intend to use these products as an avenue for any litigation but for the advancement of knowledge. Also, the research was not funded by the producing company rather it was funded by personal efforts of the authors.

ETHICAL STATEMENT

This Study was approved by the ethics committee, from the Nnamdi Azikiwe University, Awka, Anambra State, Nigeria.

COMPETING INTERESTS

Authors have declared that no competing interests exist.

REFERENCES

1. Simmaro PP, Diarra A, RuizPostigo JA, Franco JR, Jannin JG. The Human African Trypanosomiasis Control and Surveillance Programme of the World Health Organization 2000-2009: The way forward. *PLOS Neglected Tropical Diseases*. 2011;5:1007.
2. WHO. Accelerating work to overcome neglected tropical diseases: a road map for implementation. Geneva: World Health Organization; 2012.
3. Mersha C, Chemirew A, Basaznew B. Hematopathology and Hematological Parametric Alterations in indigenous cattle Due to Trypanosomosis. *Global Veterinaria*. 2012;9(5):546-551.
4. Meyer A, Holt NR, Selby R, Guitian J. Past and Ongoing Tsetse and Animal Trypanosomiasis Control Operations in Five African Countries: A Systematic Review. *PLoS Neglected Tropical Diseases*. 2016;10(12):0005247.
5. Holt HR, Selby R, Mumba C, Napier GB, Guitian J. Assessment of animal African Trypanosomiasis (AAT) vulnerability in cattle-owning communities of sub – saharan Africa. *Parasites and Vectors*. 2016;9(53)
6. Shaw APM, Giuliano C, William W, Mattioli RC, Timothy PR. Mapping the economic benefits to livestock keepers of intervening against bovine trypanosomosis in Eastern Africa. *Preventive Veterinary Medicine*. 2013;113(2):1016.
7. Samdi SM, Fajinm AO, Kalejaye JO, Wayo B, Haruna MK. periodic variation in *Trypanosoma* infection rates in trade small ruminants at slaughter in Kaduna Central Abattoir. *Research Journal of Veterinary Science*. 2010;3:189-19.
8. Nwodo NJ, Ibezim A, Ntie-Kang F, Adikwu MU, Mbah CJ. Anti-trypanosomal activity of Nigerian plants and their constituents. *Public Medicine Journal*. 2015;20(5): 7750 – 71.
9. Pedroso RB, Nakamura TU, Filho BPD, Cortez DAG, Cortez LER, Morgadodiaz JA, Nakamura, CV. Biological Activities of - 7 – Essential oil obtained from *Cymbopogon citratus* on Crithidiadeanei. *International Journal of Herbal Medicine*. 2006;45:231 – 240.
10. Santoro GF, Cardoso MG, Guimaraes LG, Freire JM, Soares MJ. Anti- proliferative effect of the essential oil of *Cymbopogon citratus* (lemon grass) on intracellular amastigotes bloodstream trypomastigotes and culture epimastigotes of *Trypanosomacruzi*. *Parasitology*. 2007;134(11): 1649-56.
11. Gerson ZJ, Miyoko M, Ana PT, Teston M, Alexandre TM, Max Jean OT. Efficiency of some essential oils in mice infected with *Trypanosomacruzi*. *Tropical Journal of Pharmaceutical Research*. 2017;16(6):1307-1316
12. Hindumathy CK. Invitro study of antibacterial activity of *Cymbopogon citratus*. *World Academy of Science. Engineering and Technology International Journal of Bio-technology and Bio Engineering*. 2011;5(2):1-5

13. Onyeyili PA, Onwualu JE. Efficacy of combination of DFMO and diminazeneaceturate in rats. *Tropical Medical Parasitology*. 1999;42:143 – 145.
14. Dina OA, Asaba A, Adedapo A, Akinyemi AO, Ombowale TO. Comparative efficacy study of Homidium bromide, Diminazeneaceturate and their combination in New Zealand white Rabbits experimentally infected with *Trypanosoma congolense*. *Tropical Veterinaria*, 2002;20(3):4314. DOI: 10.4314/tv.v20i3.4495
15. Herbert WJA, Lumsden WHR. *Trypanosomabrucei*: a rapid matching method for estimating the hosts' parasitaemia. *Experimental Parasitology*. 1976;40:427-443.
16. Boyt WP. A field guide for diagnosis, treatment and prevention of African animal trypanosomiasis. FAO. Rome; 1984.
17. Okeke JJ, Mogbo TC. Comparative study of growth performances of grass cutter fed on diverse food stuff in captivity. *International Journal of Advanced Biological Research*. 2013;3(1):85 – 89.
18. Bizimana N, Tietsen U, Zessin KH, Diallo D, Djibril C, Melzig MF, Clausen PH. Evaluation of medicinal plants from Mali for their invitrotrypanocidal activities. *Journal of Ethnopharmacology*. 2006;103(3): 350 – 356.
19. Shuaibu MN, Wuyep PTA, Yanagi T, Hirayama K, Ichinose A, Tanaka T, Kouno I. Trypanocidal activity of extracts and compounds from the stem bark of *Anogeissus leiocarpus* and *Terminalia avicennioides*. *Parasitology Research*. 2008;102(4):697–703.
20. Calsamiglia S, Busquet M, Cardozo PW, Castillejos L, Ferret A. Invited review; essential oils as modifiers of rumen microbial fermentation. *Journal of Dairy Science*. 2007;90(6):2580-2595.
21. Ojo OO, Kabutu FR, Bello M, Babayo U. Inhibition of paracetamol induced oxidation stress in rats by extracts of lemon grass (*Cymbopogon citratus*) and green tea (*Camellia sinensis*) in rats. *African Journal of Biotechnology*. 2006;5(12):1227-1232.
22. Bankole SA, Joda AO. Effect of lemon grass (*Cymbopogon citratus Stapf*) powder and essential oils on mould deterioration and aflatoxin contamination of melon seeds (*Colocynthis citrullus L*) . *African Journal of Biotechnology*. 2004;3(1):52- 59
23. Nathan H, Abel S, Agbaji SA, Zakari L, Isaac AB, Emmanuel H, Monday AD, Taofiq OA. Evaluation of in vitro Activity of Essential Oils against *Trypanosoma brucei brucei* and *T. evansi*. *Journal of Parasitology Research*. 2010(10):5
24. Shamaki BU, Ogbé AO, Abdulrahman FI, Sandabe UK. Haematological parameters in normal albino rats following oral administration of methanolic extract of wild *Ganoderma* sp. *International Journal of pharmacological Screening Methods*. 2014;4(2):94 – 99.
25. Wasser SP, Reishi L. *Ganoderma lucidum*. Institute of Evolution press, university of Haifa, mt. camel, Haifa Isreal. 2005:603 – 622.
26. Adamu M, Nwosu CO, Igbokwe IO. Toxicity and phytochemicals constituents of aqueous extract of *Ocimum gratissimum* leaf. *Nigerian Veterinary Journal*. 2008; 29(3):48–57.

© 2022 Rume et al.; This is an Open Access article distributed under the terms of the Creative Commons Attribution License (<http://creativecommons.org/licenses/by/4.0>), which permits unrestricted use, distribution, and reproduction in any medium, provided the original work is properly cited.

Peer-review history:
The peer review history for this paper can be accessed here:
<https://www.sdiarticle5.com/review-history/84979>