



Isolated Heterotopic Pancreas in a Child Presenting With Jejunal and Ileal Intussusception: An Atypical Manifestation

Anusha Taarinie Jha ^{a*} and Avinash Odugoudar ^a

^a Manipal Academy of Higher Education, Kasturba Medical College, Manipal, Karnataka, India.

Authors' contributions

This work was carried out in collaboration between both authors. Both authors read and approved the final manuscript.

Article Information

Open Peer Review History:

This journal follows the Advanced Open Peer Review policy. Identity of the Reviewers, Editor(s) and additional Reviewers, peer review comments, different versions of the manuscript, comments of the editors, etc are available here: <https://www.sdiarticle5.com/review-history/85457>

Received 25 January 2022

Accepted 01 April 2022

Published 05 April 2022

Case Study

ABSTRACT

Background: Heterotopic pancreas is most commonly found in the upper gastrointestinal tract, and is often asymptomatic and detected incidentally. A uncommon disorder known as intussusception with heterotopic pancreatic tissue occurs when a part of the colon telescopes into a neighbouring segment, with intraluminal pancreatic tissue as the lead point. In children aged 6 months to 6 years, it is the most prevalent cause of intestinal blockage.

Case Presentation: Here we describe a case of heterotopic pancreas presenting with intussusception. Isolated heterotopic pancreas acted as a lead point for intussusception in this child which is a rare occurrence. The child underwent laparotomy and resection of the ischaemic bowel and made a complete recovery post-operatively.

Conclusion: To the best of our knowledge, very few cases with such a unique presentation have been reported to date. We emphasize the early recognition and treatment of this condition to ensure the best possible prognosis.

Keywords: Heterotopic; pancreas; intussusceptions; intestine.

ABBREVIATION

HP : Heterotopic Pancreas

*Corresponding author: E-mail: anushajha99@gmail.com;

1. INTRODUCTION

Heterotopic pancreas (also known as auxiliary pancreas, aberrant pancreas, pancreatic heterotopia, or pancreatic rest) is a rare embryonic aberration in which pancreatic tissue grows on ectopic sites that lack anatomic and circulatory continuity with the pancreas' main body. The telescoping of one segment of the gastrointestinal tract into another is known as intussusception. It is the most prevalent and typically idiopathic cause of intestinal blockage in children aged 6 months to 6 years.

The presence of heterotopic pancreas (HP) is unusual but not rare with an estimated incidence of 0.2% of upper abdominal operations. Although it can occur throughout the gastrointestinal tract, the majority of cases involve the stomach, duodenum and jejunum, and ileum.

Cases of HP are predominantly asymptomatic and discovered incidentally. In this case, however, the ectopic pancreatic tissue acted as a lead point for intussusception, which resulted in the patient presenting initially with pain abdomen.

2. CASE REPORT

A 12-year-old boy presented to the surgical emergency department with acute onset pain abdomen. The child was crying and in distress. He pointed to the epigastric region when he was asked to localize the pain. His past medical history was unremarkable.

On examination, his vitals were stable. Abdominal examination revealed a sausage-shaped mass in the abdomen. Initial investigations included a complete blood count, erythrocyte sedimentation rate, renal and liver function tests, all of which were normal.

A loop of aberrant bowel in the pelvis reaching to the right iliac fossa was discovered by abdominal ultrasonography. The ultrasound probe placed on the right iliac fossa caused significant discomfort in the patient. Concentric rings of high and low echogenicity were found in the intestinal loop, indicating a small bowel intussusception. There was no evidence of proximal dilatation. On this basis, the patient was initially managed conservatively with a pneumatic reduction. When conservative management failed, the patient was taken up for laparotomy.

During laparotomy, a long segment of ileal intussusception, measuring (80x45x50mm) was noted. Three small jejunal intussusceptions were also found. The jejunal intussusceptions were reduced. The bowel surrounding the ileal intussusception was found to be markedly ischemic. Thus the ileal intussusception was resected and a primary anastomosis was performed.

A thorough inspection was done to look for a Meckel's diverticulum, which was not found. However, a round polypoid mass measuring (20x20x5.5mm) was noted proximal to the intussusception (Fig. 1). On histopathology, ectopic pancreatic tissue was seen in the small bowel (Fig. 2).

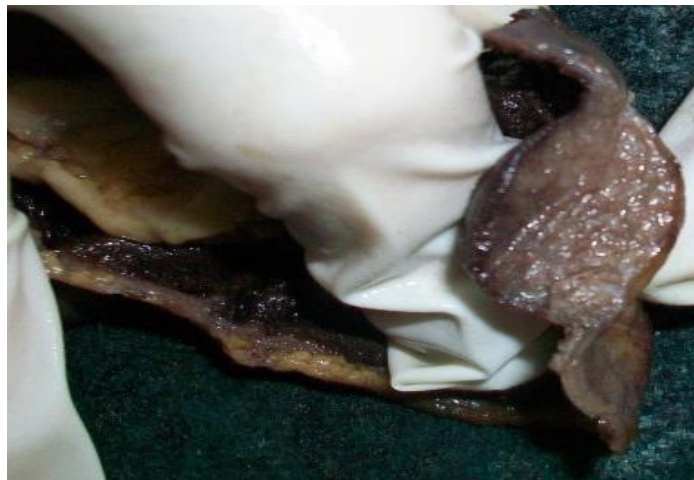

Fig. 1. A round polypoid mass was noted proximal to the intussusception

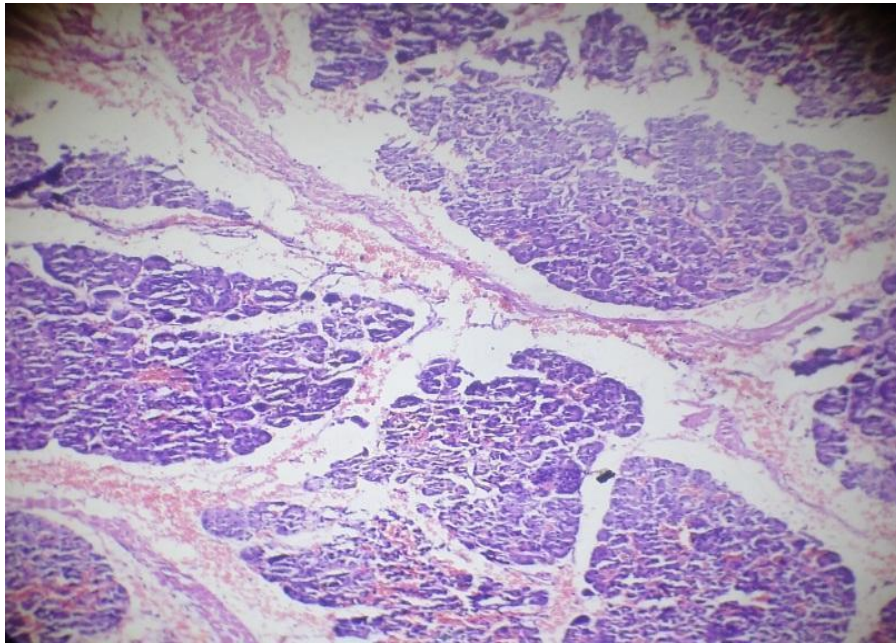


Fig. 2. Heterotopic pancreatic tissue is seen on histopathology

The child was kept under observation postoperatively and was discharged. He was symptom-free on follow-up visits and made a complete recovery.

3. DISCUSSION

Intussusception is largely a child's condition, with adults accounting for just around 5% of cases [1]. Klob [2] characterised the histological appearance of heterotopic pancreas for the first time. Heterotopic pancreas is expected to occur for per 500 upper abdominal procedures and in up to 5% of autopsy cases [3,4].

The embryological origins of the heterotopic pancreas have been thoroughly documented [5]. Several primordial endodermal evaginations of the original duodenal wall create the pancreas. The body and tail of the pancreas are formed by the dorsal diverticulum, whereas the head is formed by the ventral part. If one or more of these evaginations stay within the bowel wall, they can be transported along with the intestine's longitudinal growth, resulting in ectopic tissue everywhere from the stomach to the jejunum or ileum (least common). HP is generally accompanied with a Meckel's diverticulum in the latter.

Heterotopic pancreas is difficult to diagnose pre-operatively and is usually asymptomatic. If the ectopic pancreas acts as a nidus for bowel

obstruction, it would present with vague abdominal pain, nausea, and vomiting [6]. Bowel obstruction occurring in association with gastrointestinal bleeding is even rarer and has been described in a case series in which all the patients presented with abdominal pain and melena [7]. In our case, the distressed child presented with acute onset abdominal pain.

Intussusception caused by HP is rare but has been described previously [3,8,9]. Most cases have been described in the upper gastrointestinal tract, namely the stomach, duodenum, and jejunum. Cases occurring in the ileum are very rare [10,11]. In our case, the child was found to have three jejunal intussusceptions and one ileal intussusception.

In adults, effective management of intussusception from any origin requires excision of the lead-point tissue and, in some cases, segmental resection of the implicated intestine [11]. Because of the higher risk of malignancy, surgical resection is frequently indicated for large bowel intussusception. Despite a lower reported prevalence, this option should be considered in cases of small bowel intussusception.

4. CONCLUSION

To summarize, heterotopic pancreas of the small bowel is rare, and it is usually associated with Meckel's diverticulum. Isolated heterotopic

pancreas of the small bowel is very rare and is usually asymptomatic. In this case, the isolated heterotopic pancreas acted as a lead point for intussusception in the child, who presented acutely with abdominal pain.

After an extensive literature review, it was found that very few cases with such a unique presentation have been reported to date. Most of the cases of intussusception with a pathological lead point were reduced with a barium enema. In this case, the child was diagnosed preoperatively with abdominal ultrasound and was initially managed conservatively with pneumatic reduction. After conservative management was unsuccessful, the patient was taken for a laparotomy and the ischemic bowel was resected.

The child was symptom-free post-operatively and remained symptom-free at follow-up. We reiterate that early recognition and treatment of this condition are imperative to ensure the best possible prognosis.

It is important to palpate the bowel after manual reduction of the intussusception to look for submucosal heterotopic pancreas which may not be visible grossly, as was observed in this case [12]. Intussusception in the pediatric population is commonly associated with Meckel's diverticulum, which should also be looked for. If submucosal ectopic tissue is found, it is removed with a simple excision, which prevents recurrence and further sequelae [13]. The possibility of malignant disease should also be kept in mind while planning surgery and should be ruled out after a thorough workup.

Thus, heterotopic pancreas should be considered among the differentials for intussusception in the pediatric population. Early recognition and prompt treatment are vital to ensure the best possible prognosis [14].

CONSENT

Written informed consent was taken from the patient for the purpose of publishing this case

ETHICAL APPROVAL

As per international standard or university standard written ethical approval has been collected and preserved by the author(s).

COMPETING INTERESTS

Authors have declared that no competing interests exist.

REFERENCES

1. Intussusception in infants and adults. *Surg Gynecol Obstet.* 1967;124:99-105. [PMID: 6015799]
2. Pancreas accessorium. *Zeitschrift der Kaiserl. Königl. Gesellschaft der Aerzte zu Wien.* 1859;15:732.
3. The clinical significance of heterotopic pancreas in the gastrointestinal tract. *Br J Surg.* 1981;68:384-7. [PMID: 7237066]
4. Pancreatic heterotopia. Review of the literature and reports of 41 authenticated surgical cases, of which 25 were clinically significant. *Surg Gynecol Obstet.* 1946; 82:527-42.
5. Aberrant pancreas in the gastric wall. *Radiology.* 1963;81:107-11. [PMID: 14022897]
6. Monier A, Awad A, Szmigielski W, et al. Heterotopic pancreas: a rare cause of ileo-ileal intussusception. *Pol J Radiol.* 2014; 79:349-351. Published 2014 Oct 4. DOI: 10.12659/PJR.890913
7. Cao L, Wu W, Chen D, Hong J, Wu J, Zheng S. Ileo-ileal intussusception and gastrointestinal bleeding caused by incidental heterotopic pancreas: four case reports. *Ann Transl Med.* 2021;9(3):272. DOI: 10.21037/atm-20-2294
8. Isolated heterotopic pancreas causing intussusception. *Eur J Pediatr Surg.* 2000; 10:197-200. [PMID 10982052]
9. Nasser HA, Sleiman YA, Hassoun ZA, et al. Bowel obstruction secondary to an ectopic pancreas in the small bowels: About 2 cases. *Int J Surg Case Rep.* 2017; 31:72-74. DOI: 10.1016/j.ijscr.2017.01.019
10. Hamada Y, Yonekura Y, Tanano A, et al. Isolated heterotopic pancreas causing intussusception. *Eur J Pediatr Surg.* 2000;10(3):197-200. DOI: 10.1055/s-2008-1072357
11. Nagorney DM, Sarr MG, McIlrath DC. Surgical management of intussusception in the adult. *Ann Surg.* 1981;193(2):230-236. DOI: 10.1097/00000658-198102000-00019

12. Jacobz A, Nawaz A, Matta H, Al Salem A. Intussusception secondary to isolated heterotopic pancreas of the ileum: case report and review of the literature. *Ann Saudi Med.* 2002;22(3-4):213-5. DOI: 10.5144/0256-4947.2002.213. [PMID: 17159398]
13. Samiee-Rad, F., Farajee, S. Heterotopic pancreas presentation as a fundal submucosal mass, a case report. *Eur Surg.* 2020;52:43–47. Available:<https://doi.org/10.1007/s10353-019-00618-y>
14. Tanaka K, Tsunoda T, Eto T, et al. Diagnosis and management of heterotopic pancreas. *International Surgery.* 1993; 78(1):32-35. [PMID: 8473080].

© 2022 Jha and Odugoudar; This is an Open Access article distributed under the terms of the Creative Commons Attribution License (<http://creativecommons.org/licenses/by/4.0>), which permits unrestricted use, distribution, and reproduction in any medium, provided the original work is properly cited.

Peer-review history:
The peer review history for this paper can be accessed here:
<https://www.sdiarticle5.com/review-history/85457>