

Importance of Percutaneous Vertebroplasty in the Management of Spinal Metastases

Mohamed Seddik Eddine Akremi ^{a*}, Mehdi Bellil ^a, Souha Bennour ^a,
Senda Bellila ^a, Walid Balti ^a and Mohamed Ben Salah ^a

^a Orthopaedic Surgery Department, Charles Nicolle Hospital, Tunis, Tunisia.

Authors' contributions

This work was carried out in collaboration among all authors. All authors read and approved the final manuscript.

Article Information

Open Peer Review History:

This journal follows the Advanced Open Peer Review policy. Identity of the Reviewers, Editor(s) and additional Reviewers, peer review comments, different versions of the manuscript, comments of the editors, etc are available here: <https://www.sdiarticle5.com/review-history/87648>

Original Research Article

Received 08 April 2022
Accepted 10 June 2022
Published 14 June 2022

ABSTRACT

Introduction: Vertebral metastases are clinically manifested by severe pain, pathologic fracture, life threatening hypercalcemia, spinal cord compression and impaired quality of life. Therapeutical strategy depends on several factors such as: life expectancy, general condition of the patient and the number of spinal lesions. Vertebroplasty techniques, especially kyphoplasty, are becoming an increasingly important option for spinal metastases. Recent studies have shown the effect of vertebroplasty on postoperative pain of metastatic origin without prolonged follow-up.

The aim of our work is highlighting the short-term effect of vertebroplasty in the treatment of pain related to vertebral metastases and to study the effect on vertebral stability.

Methods: We conducted a single-centered retrospective study over a period of 4 years including 30 patients affected by spinal metastases without neurological signs with a total of 46 vertebroplasties.

Results: The mean age of our patients was 55.13 years. The average preoperative visual analogue scale (VAS) was 8.46 and reached an average of 2.73 maintained until the last follow-up of 2 years, attesting to the significant decrease in spinal pain ($p < 0.05$).

The average Beck index increased from 0.58 preoperatively to 0.84 postoperatively, with a significant difference ($p < 0.05$).

Angular kyphosis significantly decreased from a mean of 17.8° preoperatively to 7.3° postoperatively at the last follow-up ($p < 0.05$).

Three cases of polymethacrylate (PMMA) cement leakage were noted, with no neurological compromise.

Conclusion: Spinal vertebroplasty techniques are reliable, effective and reproducible in the management of vertebral metastatic lesions, enabling stability with pain control.

Keywords: Metastasis; spine; vertebroplasty.

1. INTRODUCTION

In general, metastases are mainly observed in lungs; liver and bone [1].

When it comes to bony metastasis the spine is the most frequently involved [2]. These metastatic locations manifest essentially with extreme pain deteriorating the quality of life. Pathological fractures associated with neurological compromise may also occur [3]. Vertebroplasty is a minimally invasive procedure consisting in injecting the vertebral body with Poly-Methyl-Methacrylate (PMMA) obtaining pain relief and restoration of vertebral height at the same time [4-5].

The aim of this study was to evaluate the outcome of vertebroplasty in the treatment of metastatic spine lesions:

2. METHODS

We conducted a monocentric retrospective study over a period of 4 years including 30 patients with vertebral metastasis. Inclusion criteria were severe back pain resistant to traditional therapies. Patients with neurological compromise were excluded from this study because spinal decompression surgery was also indicated. Diagnostic criteria for spinal metastasis were based on clinical examination and neuroradiology findings. Vertebroplasty was realized under general anesthesia with a patient in a prone position. Injection of cement was conducted under fluoroscopy until the lesion was fully opacified or the cement has reached the posterior wall. In case of loss of vertebral height we proceeded with a kyphoplasty: A technique allowing the restoration of vertebral height by dilating the vertebral body via a balloon catheter. All patients received post-operative pain relief and hourly neurological supervision was conducted for 12 hours in order to detect radical nerve compression. Physical exam was conducted pre operatively; at 1 Month, 6 months 1 year and 2 years post-surgery. Post-operative evaluation was based on the visual analogue scale (VAS). Radiological findings collected and evaluated were the followings: location of the lesion; number of lesions; type of lesion (lytic,

sclerotic or mixed); vertebral height through the Beck index and the local kyphotic deformity [6].

Spinal stability was analysed via the Kostuik score pre and post operatively.

A score of three or more is in favour of instability while a score of less than 3 is in favour of spinal stability [7].

The data collected was analysed using the SPSS (The Statistical Package for the Social Sciences) software.

3. RESULTS

A total of 46 vertebroplasty were performed in the period between 2015 and 2018 on 30 patients. The Patient group was composed of 12 males and 18 females and the mean age was 55.13 with extremes from 20 to 66. Primary cancers were Multiple myeloma (n=12) lung cancer (n=8), breast cancer (n=6) renal carcinoma (n=2) and papillary thyroid carcinoma (n=2). The average number of lesions per patient was 1.53 with an extreme up to 3 vertebral levels. Lesions were found mainly the thoracolumbar spine. Results are illustrated in the Table 1.

The Fig. 1 shows a patient who benefited from a vertebroplasty for a vertebral metastasis at L1 level.

No complications related to anesthesia or the procedure were noted. None of our patients had a local recurrence. The mean pre op VAS was at 8.46 with a mean of 2.73 in the post-operative evaluation. This difference was found to be statistically significant. All of our patients stopped taking group 3 analgesics for their back pain. Three of our patients presented with cement leakage with no neurological compromise as shown in Fig. 2.

Post-operative imaging showed an 80% restoration of the anterior wall height in all of our patients ; the beck index going from a mean of 0.58 to a mean of 0.84 post operatively which is statistically significant with a $p < 0.05$.

Local kyphosis went from a mean of 17.8 to a mean of 7.3 degrees; this difference was also

Table 1. Result analysis of 30 patients with spinal metastasis treated with vertebroplasty

Sex of the patient	Male	36%
	Female	54%
Mean age	Mean Age	55.13
Age groups	<30	1
	30-39	2
	40-49	14
	50-59	9
	60-69	4
Primary cancer	Myeloma	12
	Pulmonary Carcinoma	8
	Breast papillary carcinoma	6
	Renal carcinoma	2
	Thyroid papillary carcinoma	2
Number of levels treated	Total	46
	Cervical	1
	Dorsal	21
	Lumbar	22
	Sacral (Fig. 2)	2
Number of levels per patient	1	4
	2	10
	3	6
	4	1
Type of lesion	Lytic	41
	Sclerotic	0
	Mixed	5

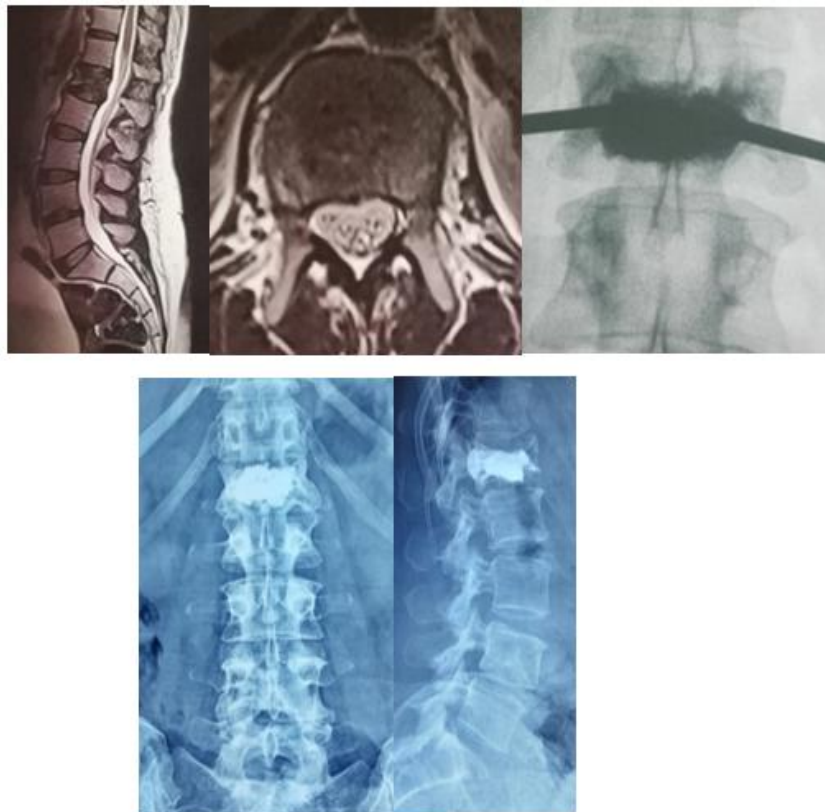


Fig. 1. Vertebroplasty for a vertebral metastasis at L1 level

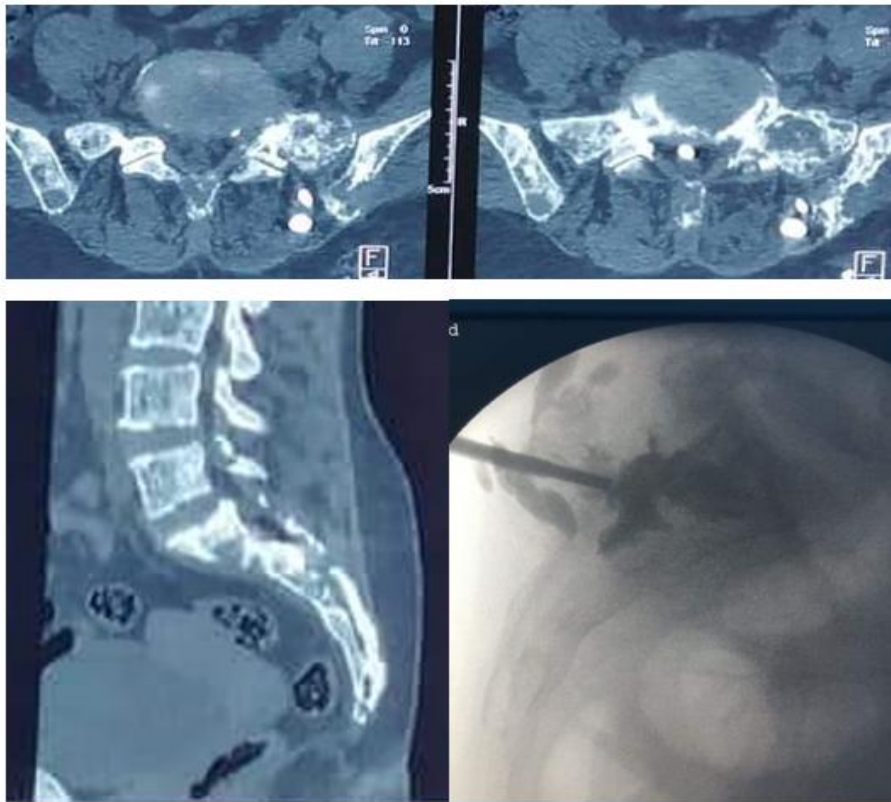


Fig. 2. Clinical case showing a sacroplasty for a vertebral metastasis with cement leakage with no neurological compromise. There were no skin or soft tissue damage

Table 2. Comparison of pre and post-operative results

	Pre-operative average	Post-operative average	The chi square test
VAS	8.46	2.73	p<0.05
Beck Index	0.58	0.84	P<0.05
Angular kyphosis	17.8 degrees	7.3 degrees	P<0.05

found to be statistically significant with a $p < 0.05$ in favour of the effect of vertebroplasty in reducing the vertebral deformity as shown in Table 2.

The post-operative evaluation according to the Kostuik score showed a score of less than 3 in 91% of the vertebrae compared to 82 % with a score of 3 or more in the preoperative evaluation.

4. DISCUSSION

Management of spinal metastasis gained a lot of interest with the extension of life expectancy of cancer patients.

The Main symptom of spinal metastases is a debilitating back pain with a high functional

impact and resistance to the usual analgesic treatments.

In other cases; lesions could be asymptomatic, discovered only at the stage of complications such as spinal cord compression or pathological fractures [8] . Non-surgical treatments seem to have very limited results and radiotherapy although it showed short term success when it comes to improving the quality of life, it has many side effects and cannot prevent pathological vertebral fractures with risk of spinal cord compression [9].

Vertebroplasty techniques which have recently gained interest in treatment of secondary lesions seem to be a reliable surgical alternative in lowering pain levels due to spinal metastasis: the

reduction of the VAS between the pre and post-operative assessment in our study correlated significantly with the published data by Lei and al. who conducted a meta-analysis of 22 studies that confirmed a significant decrease of pain post vertebroplasty [10-11]. In some cases of osteoblastic lesion, injecting PMMA to nonblastic side could treat the pain resulting from the asymmetric mechanical structure [12].

In terms of histological findings an antitumoral effect of PMMA has been proposed: This effect is related to the heat production during the polymerization process destroying the local micro circulation. This exothermic reaction may also be involved in the intra osseous nociceptive neural ablation explaining in part the analgesic effect of cementoplasty [13]. In radiological findings: the kyphoplasty technique allows a restitution of the vertebral height and reduction of the vertebral kyphotic deformity [14]. PMMA cement leakage is a considerable complication especially if the vertebral wall was disrupted [15]. A meticulous technique may prevent this complication. no severe systemic complications occur following percutaneous vertebroplasty in patients with osteoblastic spinal metastases.

5. CONCLUSION

Vertebroplasty techniques seem to be reliable, reproducible and effective when it comes to the management of pain, instability related to spinal metastasis and preventing further local kyphotic deformity. A possible antitumor effect reinforces the interest in these techniques. This rising interest is also explained by the low incidence of complications related to vertebroplasty.

CONSENT

As per international standard or university standard, patients' written consent has been collected and preserved by the author(s).

ETHICAL APPROVAL

As per international standard or university standard written ethical approval has been collected and preserved by the author(s).

COMPETING INTERESTS

Authors have declared that no competing interests exist.

REFERENCES

1. Qian Z, Sun Z, Yang H, Gu Y, Chen K, Wu G. Kyphoplasty for the treatment of malignant vertebral compression fractures caused by metastases. *J Clin Neurosci.* 2011;18(6):763-7.
2. Mesfin A, Buchowski JM, Gokaslan ZL, Bird JE. Management of Metastatic Cervical Spine Tumors. *J Am Acad Orthop Surg.* 2015;23:38-46.
3. Dalbayrak S, Önen MR, Yılmaz M, Naderi S. Clinical and radiographic results of balloon kyphoplasty for treatment of vertebral body metastases and multiple myelomas. *J Clin Neurosci.* 2010;17:219-24.
4. Tseng Y-Y, Lo Y-L, Chen L-H, Lai P-L, Yang S-T. Percutaneous polymethylmethacrylate vertebroplasty in the treatment of pain induced by metastatic spine tumor. *Surg Neurol.* 2008;70:78-83.
5. Wardak Z, Bland R, Ahn C, Xie X-J, Chason D, Morrill K, et al. A Phase 2 Clinical Trial of SABR Followed by Immediate Vertebroplasty for Spine Metastases. *Int J Radiat Oncol.* 2019;104:83-9.
6. Afathi M, Mansouri N, Farah K, Benichoux V, Blondel B, Fuentes S. Use of Cement-Augmented Percutaneous Pedicular Screws in the Management of Multifocal Tumoral Spinal Fractures. *Asian Spine J.* 2019;13:305-12.
7. Amoretti N, Diego P, Amélie P, Andreani O, Foti P, Schmid-Antomarchi H, et al. Percutaneous vertebroplasty in tumoral spinal fractures with posterior vertebral wall involvement: Feasibility and safety. *Eur J Radiol.* 2018;104:38-42.
8. Ahn H, Mousavi P, Roth S, et al. Stability of the metastatic spine pre and post vertebroplasty. *J Spinal Disord Tech.* 2006;19:178-82.
9. Jawad MS, Fahim DK, Gerszten PC, Flickinger JC, Sahgal A, Grills IS, et al. Vertebral compression fractures after stereotactic body radiation therapy: A large multi-institutional multinational evaluation. *J Neurosurg Spine.* 2016;24:928-36.
10. Chi JH, Gokaslan ZL. Vertebroplasty and kyphoplasty for spinal metastases. *Curr Opin Support Palliat Care.* 2008;2:9-13.
11. Qi L, Li C, Wang N, Lian H, Lian M, He B and Bao G: Efficacy of percutaneous

- vertebroplasty treatment of spinal tumors: A meta analysis. *Medicine (Baltimore)* 97: e9575, 2018.
12. Wang Y, Liu H, Pi B, Yang H, Qian Z and Zhu X. Clinical evaluation of percutaneous kyphoplasty in the treatment of osteolytic and osteoblastic metastatic vertebral lesions. *Int J Surg* 2016;30:161-165.
 13. Yang HL, Sun ZY, Wu GZ, et al. Do vertebroplasty and kyphoplasty have an antitumoral effect? *Med Hypotheses*. 2011;76:145-6.
 14. Zou J, Mei X, Gan M, et al. Is kyphoplasty reliable for osteoporotic vertebral compression fracture with vertebral wall deficiency? *Injury*. 2010;41:360-4.
 15. Chen JF, Lee ST. Percutaneous vertebroplasty for treatment of thoracolumbar spine bursting fracture. *Surg Neurol*. 2004;62:494-500.

© 2022 Akremit et al.; This is an Open Access article distributed under the terms of the Creative Commons Attribution License (<http://creativecommons.org/licenses/by/4.0>), which permits unrestricted use, distribution, and reproduction in any medium, provided the original work is properly cited.

Peer-review history:

The peer review history for this paper can be accessed here:
<https://www.sdiarticle5.com/review-history/87648>