



---

## **Thyroid Follicular Carcinoma with Distant Metastasis to the Calvaria**

**Kwesi Agyen-Mensah <sup>a\*</sup>, Asante-Bremang Moses <sup>a</sup>,  
Richmond Hagan <sup>a</sup> and Bin Alhassan <sup>a</sup>**

<sup>a</sup> *Cape Coast Teaching Hospital, Ghana.*

### **Authors' contributions**

*This work was carried out in collaboration among all authors. Author ABM literature search and putting together the entire manuscript. Author KAM proofreading and editing all presented facts. Author RH Put together case report from the case notes. Author BA managed the Literature search. All authors read and approved the final manuscript.*

### **Article Information**

#### **Open Peer Review History:**

This journal follows the Advanced Open Peer Review policy. Identity of the Reviewers, Editor(s) and additional Reviewers, peer review comments, different versions of the manuscript, comments of the editors, etc are available here: <https://www.sdiarticle5.com/review-history/55235>

**Case Report**

**Received 02 March 2020**  
**Accepted 04 May 2020**  
**Published 15 January 2022**

---

### **ABSTRACT**

A case of thyroid follicular carcinoma with distant metastasis to the calvaria at initial presentation and its management in a resource-constrained environment.

A 69-year-old woman who presented with an anterior neck mass, scalp swelling and right eye proptosis and was diagnosed with thyroid follicular cancer with metastasis to the skull and right eye.

Thyroid cancer (TC) is the most common endocrine cancer worldwide, accounting for 567,000 cases and 41,071 deaths in 2018. The commonest type of TC is papillary thyroid cancer (75- 85%) followed by follicular thyroid cancer (10- 20%). Although distant metastasis of TC to the lung and bones are common, metastasis to the calvaria is less common and relatively few cases have been reported in the medical literature.

Metastasis of thyroid cancer (TC) to the calvaria and by extension to other infrequently reported areas is a relatively rare but possible complication of TC.

**Keywords:** *Thyroid cancer; follicular thyroid cancer; metastasis; distant metastasis; cranial; scalp and calvaria.*

## 1. INTRODUCTION

Thyroid Cancer (TC) is the most common endocrine cancer worldwide with 567,000 new cases and 41,071 estimated deaths reported by GLOBOCAN in 2018 alone ref. The global incidence rate of TC was 10.2 per 100,000 women and 3.1 per 100,000 men for the same year [1,2]. Though prevalence and incidence are high, it is thought that TC has a relatively good survival. The 5-year survival rate of TC among the United States population (2009-20015) is stated as 98.2% by the National Cancer Institute Surveillance ref. There are however wide discrepancies in the figures reported worldwide, and this may be generally attributed to factors such as the types of TCs common in different populations around the world, the stage of the TC at time of diagnoses and the quality of treatment modalities available [3].

Worldwide, the commonest type of thyroid cancer is papillary thyroid cancer (PTC) (75-85%) followed by follicular thyroid cancer (FTC) (10-20%) [4]. The trend is similar on the African continent with PTC and FTC accounting for 6.7- 72.1% and 4.9-68% of TC cases respectively, whilst medullary and anaplastic thyroid cancers account for 2.6-13.8% and 5-21.4% of cases respectively [5]. In a 15-year histopathologic review of TC in South-eastern Nigeria, females accounted for 51 cases and males for 10 cases giving a female to male ratio of 5.1:1 and a mean age of 45.9 years for cases reported. [6] A 20-year retrospective histopathological review of trends in thyroid malignancy in the Korle- Bu Teaching Hospital (KBTH), Accra, Ghana also showed the commonest diagnosed TC is PTC with a mean age of diagnosis of thyroid malignancy in women at 40.7 years as opposed to 43.0 years in males [7]. TCs were generally more common in females than males of similar age, but males were more likely to present with the systemic disease at the time of diagnosis as compared to females (51.0% versus 42.0%) [7].

Although uncommon, both FTC and PTC may metastasize. About 30% of patients with the diagnosis of TC may have cancer spreading to only lymph nodes in the neck and 1-4% may have cancer spreading to more distant sites [8]. In a study involving a comprehensive search through the Memorial Sloan- Kettering Institutional database, it was found that TC spread to single organs occurred in 93

patients with 32 patients developing multi-organ spread. It was also found that 70% of these patients had metastasis to lymph nodes in the neck and 57% had metastasis outside the neck, with the major site of distant metastasis being the lungs (84%) [9]. Although bone metastasis of TC is quite common, second only to lung metastasis, TC metastasis to the calvarium is thought to be rare and relatively few cases have been presented in the medical literature. Herein we present a case of FTC metastasis to the calvarium in a 69-year old woman.

## 2. CASE REPORT

A 69-year-old woman presented to the general surgery outpatient clinic with an anterior neck mass of 18 years, scalp swelling of 8 months and right eye proptosis of 6 months duration. After physical examination and investigations, a diagnosis of thyroid cancer with metastasis to the skull and right eye was made. She had a total thyroidectomy 3 months later and histology report revealed follicular thyroid cancer. She was subsequently referred to the neurosurgery outpatient clinic.

On her first neurosurgery clinic visit post thyroidectomy, she was found on examination to have a right frontal scalp swelling which was a firm, non-tender and not attached to the overlying skin. It was immobile at its base, non-collapsible and non-pulsatile, and measured 7cm x 6cm. She was noted to have right eye proptosis with complete loss of vision, but no other focal neurologic deficit. She was fully conscious, afebrile, and not pale. The left eye was normal on examination. Contrast-enhanced computed tomography (CT) scan of the head showed a right frontal mass which enhanced homogeneously with contrast with osteolytic effect on the skull beneath and intracranial extension which did not breach the dura. The surrounding skull bone looked hyperostotic. There was also a similar lesion in the right sphenoid ridge extending anteriorly and displacing the right eye anteriorly (Fig. 1 and Fig. 2).

The patient was counselled for palliative care and the possibility of excision of the frontal and temporal masses as part of palliation. During the next neurosurgery clinic visit, the frontal mass had increased in size and the patient consented to excision of the frontal mass based on cosmesis and as part of palliation.

Excision of the frontal mass and cranioplasty with titanium mesh was done and findings were as follows: Huge frontal mass which had eroded through the frontal bone into the extradural space creating a skull defect of 8x10cm, with a significant intracranial portion (Fig. 3). The mass was hypervascular and firmly adhered to the dura. The skull bone around the mass was hyperostotic and soft.

The immediate post-operative period was uneventful and the patient was discharged on day five. Two weeks after surgery, the patient developed a surgical site infection and was readmitted for removal of the titanium mesh for the wound to heal whilst the patient was treated with antibiotics. The patient opted against a subsequent cranioplasty and external beam radiotherapy and was successfully discharged home with a protective helmet.

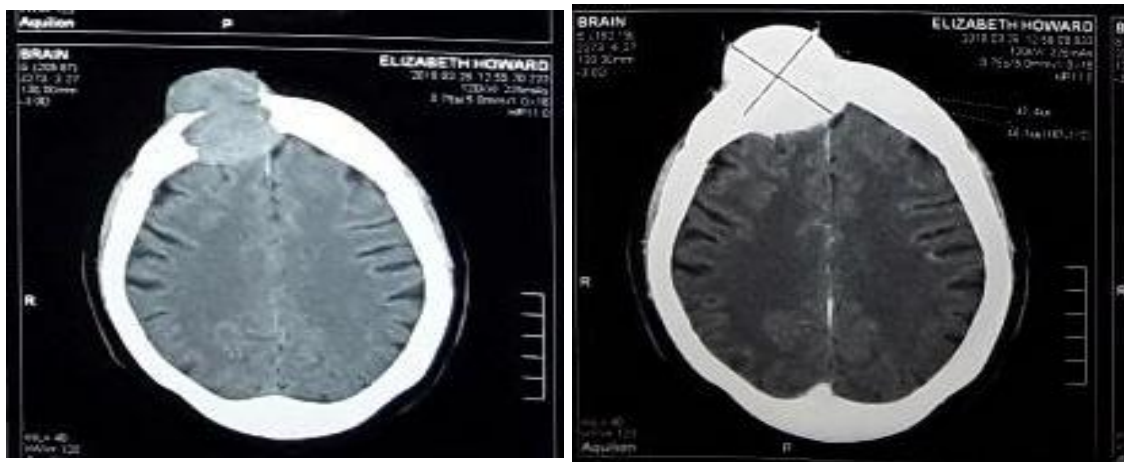


Fig. 1. Pre-contrast (left) and post-contrast (right) CT scan of frontal mass

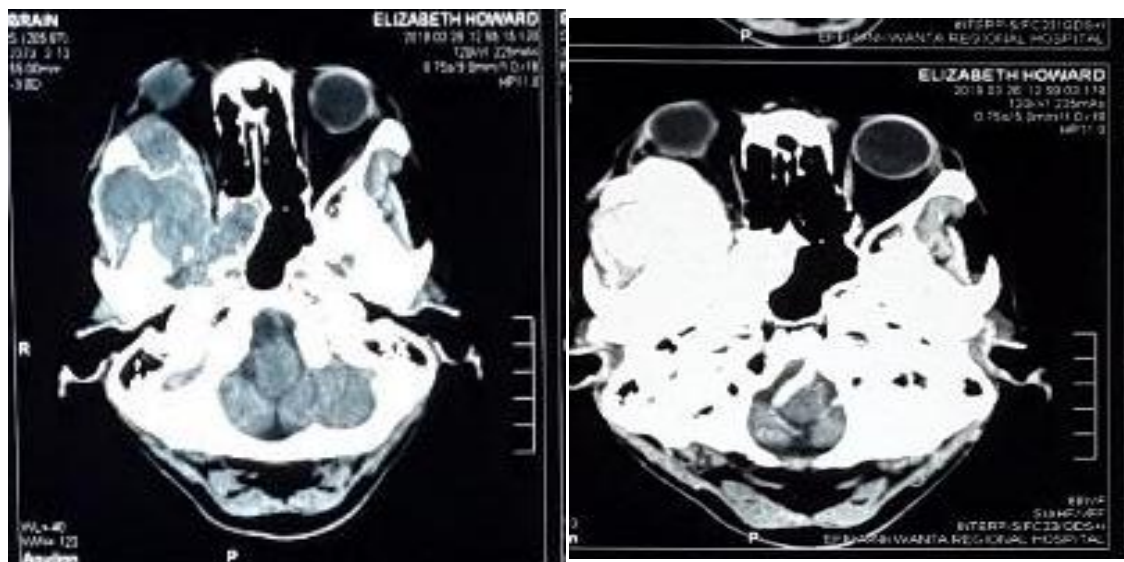
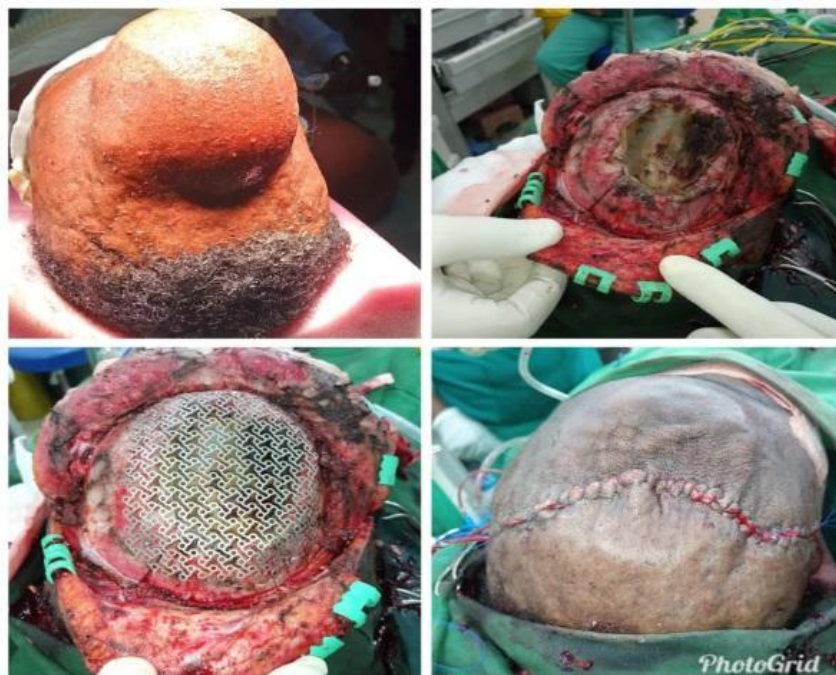
Fig. 2. Pre-contrast (left) and post-contrast (right) CT scan of sphenoid ridge mass



**Fig. 3. Showing pre-operative (upper left) intra-operative (upper right and lower left) and post excision (lower right) photos of the tumour**

### 3. DISCUSSION

TC is a relatively uncommon cancer worldwide and the American Cancer Society estimates there would be 52,890 new cases of TC in the United States representing 2.9% of the estimated total number of new cancer cases for the year 2020 [10]. TC has a disproportionate preponderance for women compared to men with the women being 3 times more likely to develop thyroid cancer as compared to men [1,2,10]. Overall, TC accounts for approximately 1.5% of all cancers in women and 0.5% of cancers in men respectively.

Although both FTC and PTC may metastasize, FTC is more likely to invade blood vessels and cause more distant metastasis to the lungs and bones compared to PTC which is more likely to spread via the lymphatic channels to regional lymph nodes [11-13].

Few patients may develop distant metastasis of TC and this may sometimes be the reason for presentation to the hospital as reported by Parameswaran *et al*, in 60% of patients in a cohort study carried out between 2000- 2001 [14]. A review of an institutional database of 3664 patients by Wang LY *et al* showed one hundred and twenty-five patients (3.4%)

developed single organ distant metastasis as opposed to Multi-organ distant metastasis which occurred in 93 patients [8]. Multi-organ distant metastasis was associated with a poorer survival prognosis compared to single organ distant metastasis and thyroglobulin level >30ng/mL at the time of first distant metastases was associated with a fivefold risk of having a multi-organ distant metastasis at the time of follow-up [8].

Treatment of patients with metastatic differentiated thyroid cancer (DTC) includes total thyroidectomy, excision of metastatic lesions, administration of radioactive iodine therapy, thyroid-stimulating hormone (TSH) suppression (thyroxine hormone) therapy with the treatment of areas of distant spread that does not respond to radioactive iodine therapy with external beam radiotherapy, targeted therapy or chemotherapy [15-18].

For our patient who presented at a late stage in a resource-constrained environment with distant metastasis of TC to the calvaria as the main reason for presentation, the treatment offered included a total thyroidectomy and an excision of the skull tumours without administration of radioactive iodine therapy, TSH suppression or external beam radiotherapy.

Most authors widely support thyroidectomy followed by administration of radioactive iodine therapy and TSH suppression therapy as part of management. The 5-year survival rate in these patients may be as high as 78% for metastatic papillary cancer and 56% for metastatic follicular thyroid cancer respectively [19].

#### 4. CONCLUSION

Metastasis of TC to the calvaria and by extension to other infrequently reported areas is a relatively rare but possible complication of TC. The scope of screening of TC patients should be broader and guided by a higher index of suspicion of possible distant spread to all possible areas including the calvaria.

#### CONSENT

It is not applicable.

#### ETHICAL APPROVAL

It is not applicable.

#### COMPETING INTERESTS

Authors have declared that no competing interests exist.

#### REFERENCES

1. Wells S. Progress in Endocrine Neoplasia. *Clinical Cancer Research*. 2016;22(20):4981-4988.
2. Bray F, Ferlay J, Soerjomataram I, Siegel R, Torre L, Jemal A. Global cancer statistics 2018: GLOBOCAN estimates of incidence and mortality worldwide for 36 cancers in 185 countries. *CA: A Cancer Journal for Clinicians*. 2018;68(6):394-424.
3. National cancer institute, SEER. Cancer of the Thyroid - Cancer Stat Facts [Internet]. SEER. 2017 [cited 27 November 2019]. Available: <https://seer.cancer.gov/statfacts/html/thyro.html>.
4. Oertel Y.C., Oertel J.E. Papillary Carcinoma. *Thyroid Cancer*. Springerlink. 2006;978-1-59259-995-0.
5. Ogbera A, Kuku S. Epidemiology of thyroid diseases in Africa. *Indian Journal of Endocrinology and Metabolism*. 2011;15(6):82.
6. Ukekwe F. Patterns of Thyroid Cancers in Southeastern Nigeria: A 15 Year Histopathologic Review (2000-2014). *Journal of Clinical and Diagnostic Research*. 2017 Aug; 11(8): EC16–EC19. DOI: 10.7860/JCDR/2017/26971.10418
7. EM D, Y T, RK G, EK W. Trends in Thyroid Malignancies in Accra Ghana: A Retrospective Histopathological Review in the Department of Pathology (1994-2013), Korle-Bu Teaching Hospital. *Journal of Cancer science and Clinical Oncology*. 2018;5(1).
8. Wang L, Palmer F, Nixon I, Thomas D, Patel S, Shaha A et al. Multi-Organ Distant Metastases Confer Worse Disease-Specific Survival in Differentiated Thyroid Cancer. *Thyroid*. 2014;24(11):1594-1599.
9. Farwell A. THYROID CANCER Survival prognosis in metastatic thyroid cancer [Internet]. *Thyroid.org*. 2015 [cited 18 November 2019]. Available from: [https://www.thyroid.org/wp-content/uploads/publications/ctfp/volume8/issue4/ct\\_public\\_v84\\_11.pdf](https://www.thyroid.org/wp-content/uploads/publications/ctfp/volume8/issue4/ct_public_v84_11.pdf)
10. Siegel R, Miller K, Jemal A. Cancer statistics, 2020. *CA: A Cancer Journal for Clinicians*. 2020;70(1):7-30.
11. Rahman G, Abdulkadir A, Olatoke S, Yusuf I, Braimoh K. Unusual cutaneous metastatic follicular thyroid carcinoma. *Journal of Surgical Technique and Case Report*. 2010;2(1):35.
12. Landis S, Murray T, Bolden S, Wingo P. Cancer statistics, 1998. *CA: A Cancer Journal for Clinicians*. 1998;48(1):6-29.
13. Schmid K. Lymph node and distant metastases of thyroid gland cancer. *Metastases in the thyroid glands*. *Pathologie*. 2015;36(S2):171-175
14. Parameswaran R, Shulin Hu J, Min En N, Tan W, Yuan N. Patterns of metastasis in follicular thyroid carcinoma and the difference between early and delayed presentation. *The Annals of The Royal College of Surgeons of England*. 2017;99(2):151-154.
15. Rajesh Kunadharaju P. New Treatment Options for Metastatic Thyroid Cancer [Internet]. *PubMed Central (PMC)*. 2015 [cited 12 February 2020]. Available: <https://www.ncbi.nlm.nih.gov/pmc/articles/PMC6375431/>
16. Treatment of Thyroid Cancer, by Type and Stage [Internet]. *Cancer.org*; 2019. [cited 9 January 2020]

- Available:<https://www.cancer.org/cancer/thyroid-cancer/treating/by-stage.html>
17. Cupisti K, Ramp U, Raffel A, Krausch M, Rehders A, Knoefel W. Multiple giant scalp metastases of a follicular thyroid carcinoma. *World Journal of Surgical Oncology*. 2008;6(1).
  18. Durante C, Haddy N, Baudin E, Leboulleux S, Hartl D, Travagli J et al. Long-Term Outcome of 444 Patients with Distant Metastases from Papillary and Follicular Thyroid Carcinoma: Benefits and Limits of Radioiodine Therapy. *The Journal of Clinical Endocrinology & Metabolism*. 2006;91(8):2892-2899
  19. Thyroid Cancer - Statistics [Internet]. Cancer.Net. 2019 [cited 7 January 2020] Available: <https://www.cancer.net/cancer-types/thyroid-cancer/statistics>

© 2022 Agyen-Mensah et al.; This is an Open Access article distributed under the terms of the Creative Commons Attribution License (<http://creativecommons.org/licenses/by/4.0>), which permits unrestricted use, distribution, and reproduction in any medium, provided the original work is properly cited.

*Peer-review history:*

*The peer review history for this paper can be accessed here:*  
<https://www.sdiarticle5.com/review-history/55235>