



# Linac Based Stereotactic Radiosurgery as Salvage Treatment in Primary Central nervous System Lymphoma- a Case Report

Manishi Bansal<sup>a†</sup>, Ankush Jindal<sup>b#</sup>, Anupam Jindal<sup>c<sup>o</sup></sup>,  
Palanisamy Mohandass<sup>a‡</sup>, Saloni Rani Kumar<sup>b<sup>¥</sup></sup> and Adhish Beri<sup>b<sup>¥</sup></sup>

<sup>a</sup> Fortis Hospital, Mohali, India.

<sup>b</sup> Government Medical College and Hospital, Chandigarh, India.

<sup>c</sup> Additional Director Neurosurgery, Fortis Hospital, Mohali, India.

## Authors' contributions

This work was carried out in collaboration among all authors. Author MB did the conception and design of the manuscript. Authors MB, Anupam Jindal and Ankush Jindal did the data collection of the manuscript. Authors MB, Ankush Jindal and PM did the manuscript writing. Authors MB, Anupam Jindal, Ankush Jindal and PM approved the final manuscript.

## Article Information

### Open Peer Review History:

This journal follows the Advanced Open Peer Review policy. Identity of the Reviewers, Editor(s) and additional Reviewers, peer review comments, different versions of the manuscript, comments of the editors, etc are available here: <https://www.sdiarticle5.com/review-history/86840>

Case Study

Received 04 March 2022

Accepted 08 May 2022

Published 12 May 2022

## ABSTRACT

Primary central nervous system lymphoma (PCNSL) is a rare form of extranodal non-hodgkin lymphoma that is confined to the central nervous system. The treatment includes induction chemotherapy followed by whole brain radiation. However, the prognosis is dismal and residual or refractory disease is very common with not many options available to treat such cases. Stereotactic radiosurgery (SRS) is evolving to salvage small volume tumors in younger age and good performance status patients. With the limited facility and experience of linac based or Gamma knife SRS, there are sparse reports for such cases from the Indian sub-continent. We report our first case from our institution treated by linac based SRS in a case of refractory PCNSL.

**Keywords:** Primary central nervous system lymphoma; stereotactic radiosurgery; salvage.

<sup>†</sup>MD Radiation Oncology, Senior Consultant Radiation Oncology;

<sup>#</sup>Intern MBBS;

<sup>o</sup>Mch Neurosurgery;

<sup>‡</sup>Senior Medical Physicist;

<sup>¥</sup>Final Year MBBS Student

\*Corresponding author: E-mail: manishi1@yahoo.com;

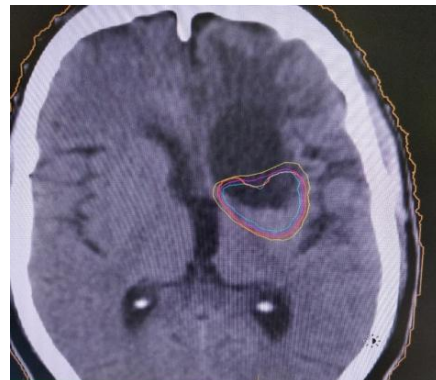## 1. INTRODUCTION

Primary central nervous system lymphoma (PCNSL) is a rare form of extranodal non-hodgkin lymphoma that is typically confined to the brain, eyes and cerebrospinal fluid without evidence of systemic spread [1]. After histopathological confirmation, treatment includes induction chemotherapy followed by whole brain radiation. The prognosis is dismal, about one-third patients are primarily refractory to treatment and more than 50% patients experience a relapse [2]. Management of relapses is very challenging as no well established guidelines are available and penetration of chemotherapy across blood brain barrier is a limitation. In such a scenario, re-irradiation to focal refractory or recurrent disease can be an option due to the radio responsiveness of the tumor [3]. We present a case of refractory PCNSL treated by linac based Stereo-tactic radiosurgery (SRS) after chemotherapy and whole brain radiation (WBRT) with complete radiological response at 8 months post SRS.

## 2. CASE REPORT

A 37 year old male presented with complaints of headache and vertigo. He was subsequently investigated for the same. A brain MRI with contrast revealed a space occupying lesion measuring 5.5x 3.2 cm in the left frontal lobe along with midline shift of 8.9mm. Craniotomy and tumor excision was done. On per-operative examination, a firm, fibrous, suckable and moderately vascular tumor was seen and removed. Histopathology revealed tumor arranged in sheets consisting of large sized round cells and brisk mitosis. On Immunohistochemistry, the tumor cells were positive for LCA, CD-20 and PAX-5 while negative for CD 30 and CD 10. Bcl-6 and MUM1 expression was significant and Ki 67 index was >90%. Overall features were of a non-hodgkin lymphoma – diffuse large B cell type. Whole body PET CT scan showed no evidence of disease elsewhere. MRI whole spine and CSF cytology was negative for tumor cells. A final diagnosis of PCNSL high grade was made and the patient was started on induction chemotherapy with R-MPV regimen. After 7 cycles of chemotherapy, repeat MRI brain showed 2.6x 1.5 cm ill-defined altered signal intensity lesion in left putamen nucleus along the posterior aspect of the lesion, likely residual disease. He was then given whole brain radiation 36 Gy in 20 fractions followed by a boost to left

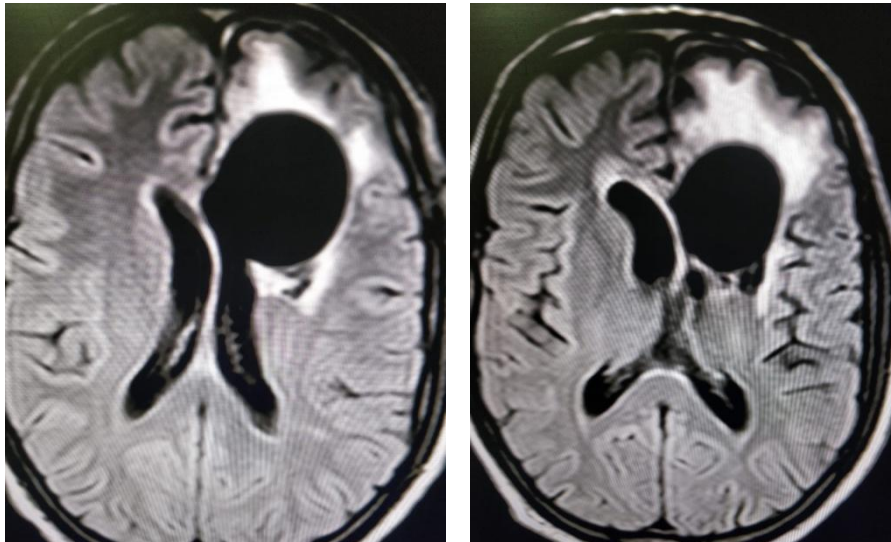
frontal area 9 Gy in 5 fractions by IMRT technique. His MRI brain showed an ill-defined lesion measuring 0.5x 0.2 cm in the left putamen nucleus suspicious of residual lesion. In view of clinical improvement, he was further given consolidation chemotherapy with 2 cycles of cytarabine. Repeat MRI brain was done after 3 months which revealed an ill-defined altered signal intensity area measuring 0.5x 0.2 cm in the left putamen nucleus, showing diffusion restriction and mild post contrast enhancement, likely residual disease. In view of small residual disease, young age and good performance status, he was advised focal radiation by SRS technique. He was treated with linac- based SRS to the residual lesion to a mean dose of 13 Gy in single fraction at 85% prescription dose to the planning target volume (Fig. 1). The tumor volume was 16.89 cc. He was followed up with MRI brain every 3 monthly and the last scan done after 8 months post SRS showed no evidence of disease (Fig. 2a and 2b).



**Fig. 1. Axial image of CT scan showing isodose curves, yellow line shows 85% coverage**

## 3. DISCUSSION

In the 1970s, PCNSL was treated with radiotherapy as a single-modality treatment. Presently, patients with good performance status are treated with induction methotrexate based chemotherapy followed by WBRT resulting in a median survival of 6 years [4]. However, patients with poor performance status and old age are still managed with WBRT alone resulting in inferior survival rates [5]. Unfortunately, management of refractory and relapsed disease is challenging as no well established guidelines are available and penetration of chemotherapy across blood brain barrier is a limitation resulting in a heterogeneity of treatment options [6].



**Fig. 2. a) 0.5x0.2cm residual tumor in left putamen nucleus (Pre SRS)  
b) no residual tumor (Post SRS)**

Recently, with the advent of gamma knife, CyberKnife, or a linac-based radiosurgery system, SRS has been used by some groups as a salvage treatment of PCNSL with the rationale of favourable therapeutic ratio and a potentially low risk of treatment-induced neurotoxicity [5,6]. Radiation doses may be determined on a case-by-case basis. The results of radiosurgical treatment for recurrent PCNSL indicate acceptable toxicity, modest survival time and favourable local control [7,8]. The largest study was published by Shin et al in 2017 where 23 PCNSL patients underwent SRS for relapsed and refractory disease [9]. Ten patients had received prior WBRT to a median dose of 43 Gy. The median tumor volume was 4 cm<sup>3</sup> and the median margin dose was 15 Gy (range 8-20 Gy). Out of 23 patients, 12 patients had complete response and local control rates was 75% at one year post SRS. According to a study by Kumar et al, factors predicting favourable response to SRS are younger age, good performance status, small volume of tumor (<4 cm<sup>3</sup>), limited disease and time interval between WBRT and SRS [10]. Our patient had also received WBRT followed by SRS to a mean dose of 13 Gy.

Gamma knife or a linac-based radiosurgery systems have been widely used in the western countries since two decades for various cancers. However their use in developing countries like India is limited to higher centres only. Secondly, due to higher cost of SRS treatment, not all patients are able to afford it. Therefore, SRS use in the salvage treatment of PCNSL is not

very common and not frequently reported as well. Hence our report is a rare publication from India.

Radiation has a greater effect on local tumor control than chemotherapy with less side-effects [11,12]. Therefore, the re-irradiation to a smaller volume of brain by stereotactic radiosurgery can be used as part of multimodality management for patients with refractory or relapsed PCNSL. However, there is a need to address the standardized dose fractionations to be used in SRS through prospective trials [13,14].

#### **4. CONCLUSION**

Linac-based stereo-tactic radiosurgery is a feasible option to salvage small volume primary central nervous system lymphomas especially in younger age and good performance status patients, however radiation doses need to be defined in such setting.

#### **ETHICAL APPROVAL**

As per international standard or university standard written ethical approval has been collected and preserved by the author(s).

#### **CONSENT**

As per international standard or university standard, patients' written consent has been collected and preserved by the author(s).

## COMPETING INTERESTS

Authors have declared that no competing interests exist.

## REFERENCES

1. Grommes C, DeAngelis LM. Primary CNS Lymphoma. *J Clin Oncol.* 2017;35(21):2410-2418. DOI: 10.1200/JCO.2017.72.7602.
2. von Baumgarten L, Illerhaus G, Korfel A, Schlegel U, Deckert M, Dreyling M: The diagnosis and treatment of primary CNS lymphoma—an interdisciplinary challenge. *Dtsch Arztebl Int.* 2018;115:419–26. DOI: 10.3238/arztebl.2018.0419
3. Tao K, Wang X, Tian X. Relapsed Primary Central Nervous System Lymphoma: Current Advances. *Front Oncol.* 2021;11:649789. DOI: 10.3389/fonc.2021.649789.
4. Morris PG, Correa DD, Yahalom J, Raizer JJ, Schiff D, Grant B, Grimm S, Lai RK, Reiner AS, Panageas K, Karimi S, Curry R, Shah G, et al. Rituximab, methotrexate, procarbazine, and vincristine followed by consolidation reduced-dose whole-brain radiotherapy and cytarabine in newly diagnosed primary CNS lymphoma: final results and long-term outcome. *J Clin Oncol.* 2013;31:3971–3979.
5. DeAngelis LM. Whither whole brain radiotherapy for primary CNS lymphoma? *Neuro Oncol.* 2014;16:1032–1034.
6. Zhang Y, Zhou DB. Primary central nervous system lymphoma: status and advances in diagnosis, molecular pathogenesis, and treatment. *Chin Med J (Engl).* 2020;133(12):1462-1469. DOI: 10.1097/CM9.0000000000000844.
7. Kenai H, Yamashita M, Nakamura T, et al. Gamma Knife surgery for primary central nervous system lymphoma: usefulness as palliative local tumor control. *J Neurosurg.* 2006;105:133-8.
8. Hirono S, Iwadate Y, Higuchi Y, Serizawa T, Nagano O, Matsutani T, Saeki N. Stereotactic radiosurgery in combination with up-front high-dose methotrexate as a first-line treatment for newly diagnosed primary central nervous system lymphoma. *J Neurooncol.* 2015;123(2):237-44. DOI: 10.1007/s11060-015-1786-1.
9. Shin SM, Silverman JS, Bowden G, Mathieu D, Yang HC, Lee CC, Tam M, Szelemej P et al. Relapsed or refractory primary central nervous system lymphoma radiosurgery: Report of the International Gamma Knife Research Foundation. *J Radiosurg SBRT.* 2017;4(4):247-253.
10. Kumar R, Laack N, Pollock BE, et al. Stereotactic radiosurgery in the treatment of Recurrent CNS Lymphoma. *World Neurosurgery.* 2015;84(2):390–7 DOI:10.1016/j.wneu.2015.03.062
11. Sakamoto M, Oya N, Mizowaki T, et al. Initial experiences of palliative stereotactic radiosurgery for recurrent brain lymphomas. *J Neurooncol* 2006;77:53-8.
12. Chao ST, Barnett GH, Volgelbaum MA, et al. Salvage stereotactic radiosurgery effectively treats recurrences from whole-brain radiation therapy. *Cancer.* 2008;113:2198. DOI: 10.1002/cncr.23821
13. Palmer JD, Bhamidipati D, Shukla G, Epperla N, Glass J, Kim L, Shi W. Outcomes after stereotactic radiosurgery for CNS lymphoma. *J Neurooncol.* 2020; 147(2):465-476. DOI: 10.1007/s11060-020-03444-5.
14. Fisher B, Seiferheld W, Schultz C, DeAngelis L, Nelson D, Schold SC, Curran W, Mehta M. Secondary analysis of Radiation Therapy Oncology Group study (RTOG) 9310: an intergroup phase II combined modality treatment of primary central nervous system lymphoma. *J Neurooncol.* 2005;74(2):201-5. DOI: 10.1007/s11060-004-6596-9.

© 2022 Bansal et al.; This is an Open Access article distributed under the terms of the Creative Commons Attribution License (<http://creativecommons.org/licenses/by/4.0>), which permits unrestricted use, distribution, and reproduction in any medium, provided the original work is properly cited.

*Peer-review history:*  
The peer review history for this paper can be accessed here:  
<https://www.sdiarticle5.com/review-history/86840>