



Thinking beyond Gauze Count at Surgery: A Reminder to Surgeons on Textilomas

I. O. Awowole^{1*}, O. N. Makinde², A. M. Tijani³, O. Olasehinde⁴
and O. O. Badejoko²

¹Department of Obstetrics and Gynaecology, Obafemi Awolowo University Teaching Hospitals Complex, Ile-Ife, Osun State, Nigeria.

²Department of Obstetrics and Gynaecology, Obafemi Awolowo University, Ile-Ife, Osun State, Nigeria.

³Department of Obstetrics and Gynaecology, Ladoko Akintola University of Technology, Ogbomosho, Osun State, Nigeria.

⁴Department of Surgery, Obafemi Awolowo University Teaching Hospitals Complex, Ile-Ife, Osun State, Nigeria.

Authors' contributions

All the Authors participated in the clinical management of the patient. Author IOA prepared the manuscript. Authors ONM, AMT and OO managed the literature search. Author OOB managed the pictorial aspect of the write-up and proof-read the article. All the Authors read the manuscript and made appropriate corrections. All authors read and approved the final manuscript.

Case Study

Received 23rd June 2014
Accepted 4th July 2014
Published 15th July 2014

ABSTRACT

Introduction: Inadvertently leaving surgical sponges in operation site has been described by various terms, including textiloma and gossypiboma. In recognition of the morbidity and economic implications that are associated with this error, surgeons exercise utmost caution to avoid retention of surgical instruments in body cavities.

Presentation of Case: A 29 year old Para1 presented at our facility with incapacitating abdominal pain and swelling of twelve months duration. She had an emergency Caesarean section at another hospital one month before the onset her symptoms. She had several hospital admissions, during which she was managed conservatively for adhesive intestinal obstruction without sustained relief. She was resuscitated, and she had exploratory laparotomy at our centre. A surgical linen that measured 110x150cm

*Corresponding author: Email: drawo2001@yahoo.com;

was retrieved from an abscess cavity. The procedure was complicated by entero-cutaneous fistula, which was satisfactorily managed surgically.

Discussion and Conclusion: Despite the large size of the retained material, the diagnosis was not entertained for twelve months, thereby conferring untold hardship on the patient. The possibility of retained foreign bodies should be considered early as a differential diagnosis of chronic post-operative pain, abscess or fistula. Furthermore, teamwork and seamless communication between surgeons and other theatre staff is essential to prevent such mistakes.

Keywords: Textiloma; gossipyboma; caesarean section; fistula; surgical linen; gauze count; post-operative pain.

1. INTRODUCTION

Inadvertently leaving surgical sponges in operation site has been described by various terms, including cottonloma, gauzeoma, textiloma and gossypiboma [1]. Quite often, these terms are used synonymously. Gossypiboma is a combination of latin and Swahili languages ("gossypium" being the latin word for cotton, and "boma", a Swahili term which literarily means "place of concealment") [2].

In recognition of the morbidity and economic implications of this avoidable surgical error, every surgical team takes special care to avoid inadvertent retention of surgical instruments in body cavities following surgeries [3]. We report as a reminder, an uncommon situation in which the surgical sponge count confirmed complete retrieval, whereas, a surgical linen had been inadvertently left behind in the peritoneal cavity.

2. PRESENTATION OF CASE

The patient was a 29 year old Para 1, none alive who presented at our emergency unit with recurrent abdominal pain of twelve months duration. She had an emergency Caesarean section at a private hospital about a month before the onset of the pain. She had been admitted thrice at different hospitals on account of the pain before she presented at our centre. On each of these occasions, she was managed conservatively for post-operative adhesive intestinal obstruction with parenteral antibiotics, analgesics and other supportive therapy with temporary relief of symptoms. At presentation in our centre, she was weak, anxious and febrile with a temperature of 39°C. Her pulse rate was 118beats per minute, and her blood pressure was 70/50mmHg. Her abdomen was distended, with moderate tenderness. An ill-defined abdominal mass was palpated. Pelvic examination revealed bogginess and tenderness in the pouch of Douglass. She had leucocytosis, with absolute neutrophilia of 12,000cells/mm³. Abdominopelvic scan revealed an area of walled off collection with internal echoes. A diagnosis of intra-abdominal collection, possibly precipitated by a foreign body was entertained and she was scheduled for exploration after optimal resuscitation. At laparotomy, the abscess cavity was drained, and a surgical drape measuring about 110x150cm (Figs. 1 and 2) was recovered. A peritoneal lavage was done, and a drain was left in situ. She however developed a high output entero-cutaneous fistula on the third day after surgery, which was surgically managed with satisfactory outcome. She was discharged home on post-operative day 10 in stable condition. She has since remained in satisfactory state of health.

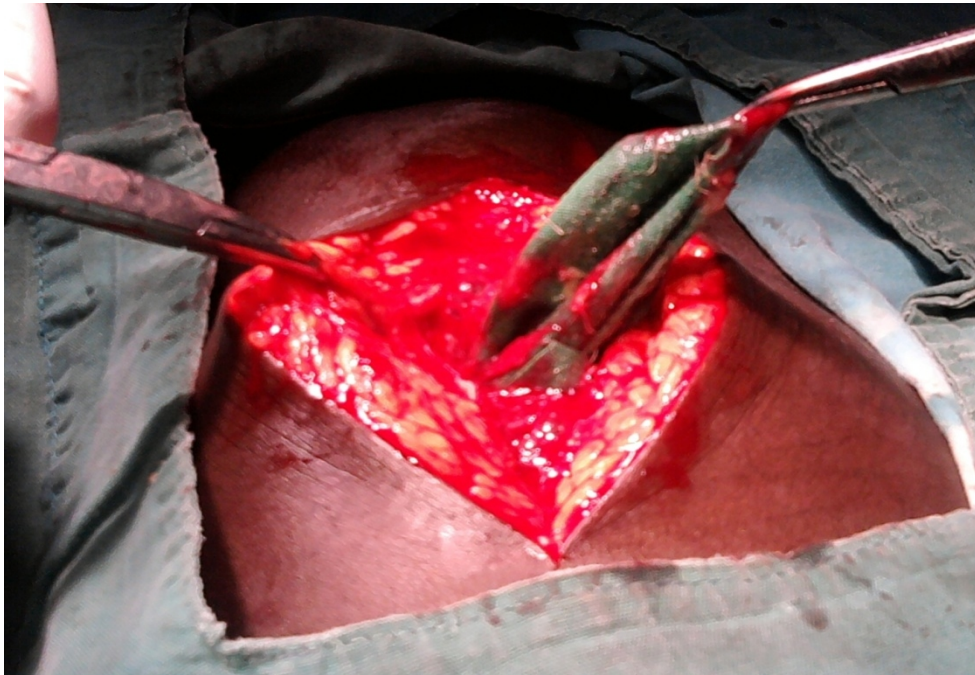


Fig. 1. The retained surgical linen at the onset of the exploration



Fig. 2. The retrieved surgical linen.

3. DISCUSSION

Textilomas are materials derived from textiles, which are inadvertently left in body cavities after surgical procedures. They are regarded as perhaps the least reported complication of surgery, reason being the associated medico-legal implications. The significance of a textiloma is further emphasized by Zahiri et al. [4], who appropriately classified it as one of the “three never events” of surgery, as they constitute a gross violation of patients’ safety. The two other events include “wrong site procedures” and “fire outbreaks” in theatre during an ongoing surgery.

The incidence of retained foreign bodies following surgery ranged between 1/100 and 1/5,027 surgeries [5,6]. This wide range is believed to be due to under-reporting of the event in many centers, and the fact that some cases may remain asymptomatic, and are therefore undiagnosed. As much as 80% of cases of textilomas occur following surgeries in body cavities such as the thoracic and the abdominal cavities. Albeit uncommon, it has also been reported following neurosurgical procedures [1], breast surgeries [7], as well as on the extremities such as the leg [8,9].

Worthy of mention is that intra-abdominal procedures involving deep cavities such as retro-peritoneal, hepatobiliary, and pelvic surgeries, during which a blood soaked sponge may easily disappear under a retractor, are at increased risk of textilomas. Though commoner after emergency procedures, textilomas may also occur following elective procedures. Other risk factors include prolonged surgeries; excessive intra-operative haemorrhage; late night surgeries; unanticipated change in planned procedures; intra-operative deterioration of patient’s condition; inexperienced staff; hurried change of shift during an ongoing surgery, and inadequate staff [5,10,11]. Caesarean section and other procedures involving the removal of large intra-abdominal masses may in particular, provide the massive space required to accommodate large sheets as reported here; our report may however represent the largest retained foreign body that is ever reported in literature.

Two types of foreign body reaction have been reported in the pathophysiology of textilomas; there is an initial sterile exudative reaction due to the irritation of surrounding tissues by the foreign body [12]. This exudate later becomes secondarily infected by bacteria, leading to the formation of an abscess. The second reaction emanates from an aseptic fibrinous reaction, which culminates in the formation of granulomatous capsules that wall off the foreign body. The untold hardship vested on patients with textilomas is a clinical reflection of the severity of these reactions.

The prolonged duration of symptoms before the diagnosis was established in our patient underscores the tendency to misdiagnose the condition, as it has no pathognomonic clinical symptoms/signs [13]. Frequently, textilomas are misdiagnosed as post-operative adhesive intestinal obstruction, and the conservative line of management is towed. A review of the management plan is however often necessitated, by the failure to achieve any remarkable clinical improvement. Other commonly reported differential diagnoses include suspected malignancies, surgical site tumor recurrence, pseudotumoral syndromes, space occupying lesions, chronic fistulae of unknown aetiology, hydatid cysts, and irritable bowel syndrome [1,12,14]. Radiological investigations, ranging from ultrasound scan through CT scan to magnetic resonance imaging are often called to the rescue in patients with textilomas, [15] though they may also fail to clinch the diagnosis in as much as 2/3rd of cases, thereby prolonging the latency period to diagnosis.

Open surgeries, or endoscopic procedures where applicable remain the hallmark of management of patients with textilomas, [16,17] albeit spontaneous extrusions through body orifices such as the anus and the external urethral meatus have been reported.(5, 18) Open surgery is favoured by some surgeons, as the condition is often complicated by injury to adjacent viscera, especially bowel loops as a result of adhesions incited by the foreign body. Occasionally, the adhesions are severe enough to warrant bowel resection and anastomosis.

The severe morbidity and economic implications of textilomas underscore the innumerable benefits of prevention. Perhaps the most critical approach to the prevention of retention of foreign bodies at surgical sites is teamwork and seamless communication between surgeons and other theatre staff. Furthermore, distractions in operating theatre, especially those involving communications and data transmission with cell phones and other electronic media must be reduced to barest minimum, if not completely eliminated. Only dire emergency communications should be entertained intra-operatively, and even these must be as brief as possible [11].

Institutions are also advised to have a documented protocol on handling miscounts and incomplete surgical materials during surgeries. A costless and veritable approach to the prevention of retained foreign bodies at surgery is the "Standard Surgical Instrument and Sponge Count". This protocol involves a routine, audible pre-operative count of surgical sponges and instruments by at least two people, with the surgeons paying close attention. A repeat count is done before commencement of closure of the surgical site, and a third count is conducted at the completion of the entire procedure. This technique was reported to prevent textilomas in about 82% of cases, and the premium placed on the prevention of textilomas using this method is highlighted by the 15-30 minutes spent by registered nurses on accounting for surgical sponges and instruments during every surgical procedure [3]. This article aims to remind surgeons that materials other than surgical sponges may be retained at surgical site. Though, a surgical linen count at every surgery may appear time-consuming, it would have prevented the complications experienced by this patient. The same standard count technique should therefore be applied to all surgical instruments and linens.

The preference for tagged, larger laparotomy sponges over the small surgical sponges even on skin incisions is gradually becoming popular. Furthermore, surgeons are advised to painstakingly check all surgical sites, including a four-quadrant check for abdomino-pelvic surgeries, to be sure that no foreign body had been inadvertently left behind before commencement of surgical closure.

In an attempt to compensate for human fallibility despite the above-mentioned precautionary measures, complementary newer technologies have been developed. These include the use of automated counters that obviates the need for manual counting; the use of labelled radio-opaque sponges; bar-coded sponges; and radiofrequency tagged surgical sponges [19]. The Disposable, Absorbable, Secure Hold (EZ-DASH), an absorbent 12-thickness laparotomy pad covering a malleable stainless steel mesh, thereby providing both the needed retraction and a reduction in the use of individual laparotomy sponges is one of the newer technological innovations aimed at complementing human efforts [20].

4. CONCLUSION

In conclusion, despite painstaking and meticulous efforts at surgery, human mistakes may simply persist. We therefore advise that the possibility of retention of surgical instruments

and textilomas should be considered early as a differential diagnosis of any patient in whom post operative pain, abscess or fistula runs a chronic course.

CONSENT

All authors declare that written informed consent was obtained from the patient for publication of this case report and accompanying images.

ETHICAL APPROVAL

All authors hereby declare that the management of this patient and the preparation of the manuscript have been performed in accordance with the ethical standards laid down in the 1964 Declaration of Helsinki.”

COMPETING INTERESTS

Authors have declared that no competing interests exist.

REFERENCES

1. Ribalta T, McCutcheon IE, Neto AG, Gupta D, Kumar AJ, Biddle DA, et al. Textiloma (Gossypiboma) Mimicking Recurrent Intracranial Tumor. *Arch Path Lab Med.* 2004;128(7):749-58.
2. Shahi K, Geeta B, Rajput P. Forget Me Not - Gossypiboma in Pregnancy: Report of a Case. *Internet J Surg.* 2009;19(2):55-58.
3. Australian College of Operating Room Nurses and Association of peri-Operative Registered Nurses. Counting of Accountable Items used during Surgery. *Standards for Perioperative Nurses: ACORN.* 2006;1-12.
4. Zahiri HR, Stromberg J, Skupsky H, Knepp EK, Folstein M, Silverman R, et al. Prevention of 3 never event" in the operating room: fires, gossypiboma, and wrong-site surgery. *Surg Innov.* 2011;18(1):55-60.
5. Kamal EB, Kamal AG, Rami JY. Retained Surgical Sponges (Gossypiboma). *Asian J Surg.* 2005;28(2):109-15.
6. Taçyıldız I, Aldemir M. The Mistakes of Surgeons : Gossypiboma. *Acta chir belg.* 2003;03:71-5.
7. Yeniceri O, Balci P, Cullu C, Devce M. Gossipyboma in the Breast: A Rare Case Report. *J Med Cases.* 2014;5(3):140-2.
8. Chung-Ping L, Chia-Chun H, Tsun-Hou C. Gossypiboma of the Leg: MR Imaging Characteristics. A Case Report. *Korean J Radiol.* 2003; 4(3):191-3.
9. Sakayama K, Fujibuchi T, Sugawara Y, Kidani T, Miyawaki J, Yamamoto H. A 40-year-old gossypiboma (foreign body granuloma) mimicking a malignant femoral surface tumor. *Skeletal Radiol.* 2005;34(4):221-4.
10. Gawande A A. DM S. Risk factors for retained instruments and sponges after surgery. *N Engl J Med.* 2003;348(3):229-35.
11. American College of Surgeons. American College of Surgeons: Statement on the Prevention of Retained Foreign Bodies after Surgery. Available:http://www.facs.org/fellows_info/statements/st-51html2008.
12. Asuquo ME, Ogbu N, Udosen J, Ekpo R, Agbor C, Ozinko M, et al. Acute abdomen from gossypiboma: A Case series and review of literature. *Nig J Surg Res.* 2006;8(3-4):174-176.

13. Rajagopal A, Martin J. Gossypiboma-A Surgeon's Legacy Report of a Case and Review of the Literature. *Dis Colon Rectum*. 2002;45(1):119-20.
14. Gencosmanoglu R, Inceoglu R. An unusual cause of small bowel obstruction: Gossypiboma – case report. *BMC Surgery*. 2003;36: 6.
15. Mathew JM, Rajshekhar V, Chandy MJ. MRI features of neurosurgical gossypiboma: report of two cases. *Diagnostic Radiol*. 1996;38(5):468-9.
16. Singh R, Mathur RK, Patidar S, Tapkire R. Gossypiboma: Its Laparoscopic Diagnosis and Removal. *Surg Lap endo Percut tech*. 2004;14(5):304-5.
17. Kansakar R, Hama BK. Cystoscopic removal of an intravesical gossypiboma mimicking a bladder mass: a case report. *J Med Case Rep*. 2011;5:579.
18. Lin, Chuang, Wong, Liao. Gossypiboma: migration of retained surgical gauze and spontaneous transurethral protrusion. *BJU International*. 1999;84:879-80.
19. Regenbogen SE, Greenberg CC, Resch SC, Kollengode A, Cima RR, Zinner MJ, et al. Prevention of retained surgical sponges: A decision-analytic model predicting relative cost-effectiveness. *Surgery*. 2009;145(5):527-35.
20. Enker WE, Martz JE, Picon A, Koulos J, Goldman N, Yang P, et al. A Report on the Introduction of the EZ DASH Lap into Clinical Use. New York: USA; 2007.

© 2014 Awowole et al.; This is an Open Access article distributed under the terms of the Creative Commons Attribution License (<http://creativecommons.org/licenses/by/3.0>), which permits unrestricted use, distribution, and reproduction in any medium, provided the original work is properly cited.

Peer-review history:

The peer review history for this paper can be accessed here:
<http://www.sciencedomain.org/review-history.php?iid=599&id=12&aid=5326>