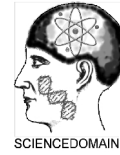



British Journal of Medicine & Medical Research
4(32): 5174-5178, 2014

SCIENCEDOMAIN *international*
www.sciencedomain.org



Barotraumatic Subcutaneous Orbital Emphysema after Nose Blowing: Case Report

**Yasin Metiner¹, Tuba Cimilli Ozturk^{1*}, Ozge Ecmel Onur¹
and Serdar Ozdemir¹**

¹*Department Emergency Medicine, Fatih Sultan Mehmet Education and Research Hospital, Istanbul, Turkey.*

Authors' contributions

This work was carried out in collaboration between all authors. Author YM carried out the patient's treatment and wrote the first draft of the manuscript. Authors TCO and OEO edited the final manuscript. Author SO managed the literature searches. All authors read and approved the final manuscript.

Case Study

Received 5th June 2014
Accepted 7th July 2014
Published 17th July 2014

ABSTRACT

Orbital subcutaneous emphysema is defined as the abnormal presence of air within the periorbital soft tissue. It occurs generally as a result of blunt or penetrating facial trauma. Spontaneous barotraumatic emphysema is a very rare entity that generally results due to a sudden increase in the intraorbital pressure. If there is not an obvious visual acuity loss even with high ocular pressure, it is generally managed conservatively. However prolonged elevation of intraorbital pressure may cause an irreversible, ischemic visual loss secondary to an ischemic optic neuropathy or an acute central retinal artery occlusion. Emergency decompression may be required. Here we are presenting a patient with barotraumatic orbital subcutaneous emphysema, occurring after forceful nose blowing who was managed conservatively without any complications.

Keywords: *Subcutaneous emphysema; barotrauma; emergency medicine; orbital blow-out fractures; trauma.*

*Corresponding author: Email: tcimilliozturk@gmail.com;

1. INTRODUCTION

Orbital subcutaneous emphysema is defined as the abnormal presence of air within the periorbital soft tissue. It occurs generally as a result of blunt or penetrating facial trauma. There are a few spontaneous orbital emphysema cases reported in the literature. The mechanism is defined with sudden increase in the intraorbital pressure [1-5].

Although, the clinical course is mostly benign in nature, emergency decompression is required in some cases [6]. Severe orbital emphysema can cause an irreversible, ischemic visual loss secondary to an ischemic optic neuropathy or to an acute central retinal artery occlusion [7].

Here we are reporting a rare case of barotraumatic orbital subcutaneous emphysema, occurring after forceful nose blowing who was managed conservatively without any complications.

2. CASE

A 33-year-old man presented to the emergency department (ED) with a history of sudden right upper eyelid swelling. He denied any physical trauma to the face or head. Past medical history revealed nothing special and he had no previous facial surgical operations. He was complaining of flu-like symptoms for a few days and he thought that this swelling might have occurred after a forceful nose blowing.

On physical examination, the vital signs were normal. There was minimal tenderness localized at the right side of the periorbital region, and at the upper eyelid. There was marked ptosis at the effected eyelid (Fig.1). Upper eyelid palpation revealed fine crepitation. There was minimal bleeding through the right nostril which had stopped spontaneously during the examination. The left nostril was clear. On ophthalmological examination visual acuity and intraorbital pressure was normal in both eyes. Extraocular movements were also normal bilaterally. Computed tomography scan showed air over the right orbita (Fig. 2). There was fracture at the orbital medial wall. The orbito-palpebral subcutaneous emphysema diagnosed without blunt or penetrating facial trauma.

The patient was treated with a 7-day broad-spectrum prophylactic antibiotic, nasal decongestant and non-steroidal anti-inflammatory drug. Ice-pack application, avoiding of nose blowing or sneezing was also advised. On head and neck surgery and ophthalmology follow-up visits the patient remained asymptomatic and no complications were observed.

3. DISCUSSION

The medial orbital wall is formed partly by the frontal process of the maxilla, the lacrimal bone and the lateral wall of the ethmoid bone, the lamina papyracea. The lamina papyracea is the weakest point of the medial orbital wall. It has been reported as the most common site of pure orbital fractures and passage of air from the paranasal sinuses [8].

Orbital emphysema is not infrequent after blunt or penetrating facial and orbital traumas. But rarely as in our case, might intraorbital barotrauma be the sole mechanism that results in the subcutaneous air. The intraorbital pressure rise can be observed during nose blowing, sneezing, coughing, vomiting, diving or travelling by plane [1-4].

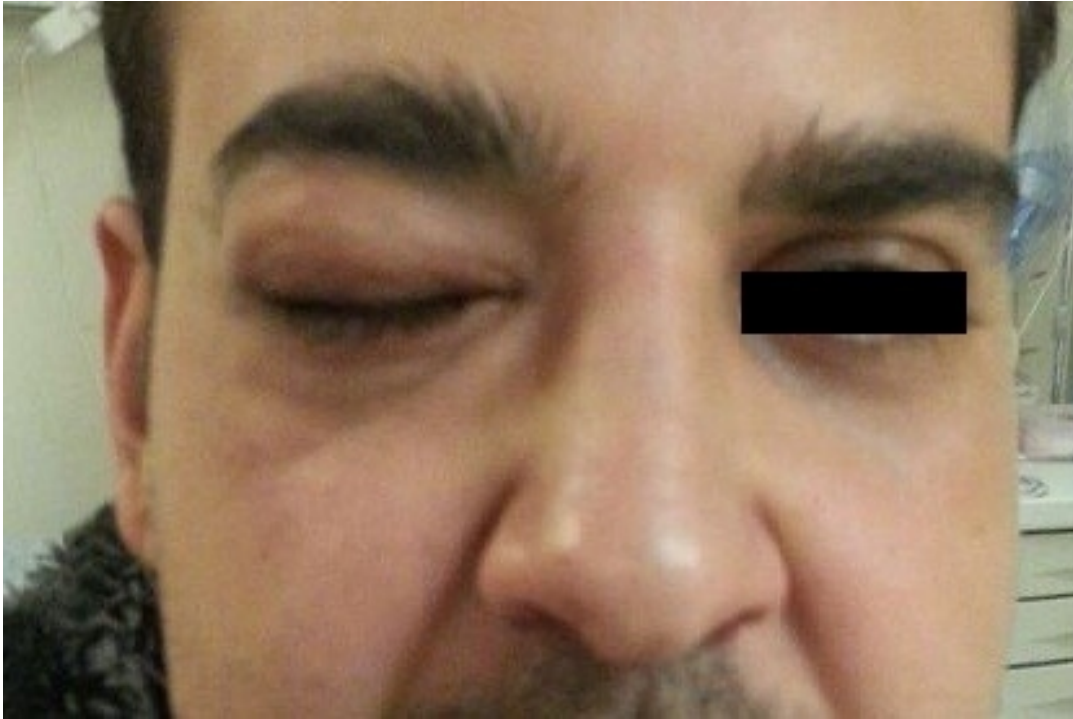

Fig. 1. The patient with right upper eyelid diffuse swelling and ptosis after nose blowing

In our case nose blowing especially by blocking of one nostril probably results in intranasal pressure elevation, and the pressure reflected directly to the orbital wall. Chiu and colleagues defined that the barotrauma is responsible from a possible defect in the lamina papyracea which is the thinnest part of the orbital wall. After the injury, the air in the paranasal sinuses is thought to enter the orbital, subconjunctival, subcutaneous planes [5].

Subcutaneous orbital emphysema is a relatively benign condition that generally results in cosmetic concerns in patients for a few days. Conservative treatment is usually the choice of treatment [9,10]. Although the role of prophylactic antibiotics is unclear, in recent reports the authors suggest for a short time [5]. Prolonged elevation of intraorbital pressure may cause an irreversible, ischemic visual loss secondary to an ischemic optic neuropathy or an acute central retinal artery occlusion. Ababneh reported a case with elevated intraocular pressure (26mmHg) who was managed with topical antiglaucoma drug and lubricating eye drops. The patient's visual acuity in the effected eye was also diminished as the author declared [1].

However, some authors reported cases with elevated intraocular pressure required invasive decompression. Garcia and colleagues reported a severe orbital emphysema case required emergency needle decompression [6]. Shah also reported a case with visual acuity loss that was managed with simple underwater drainage of trapped air by 24-gauge needle [11].

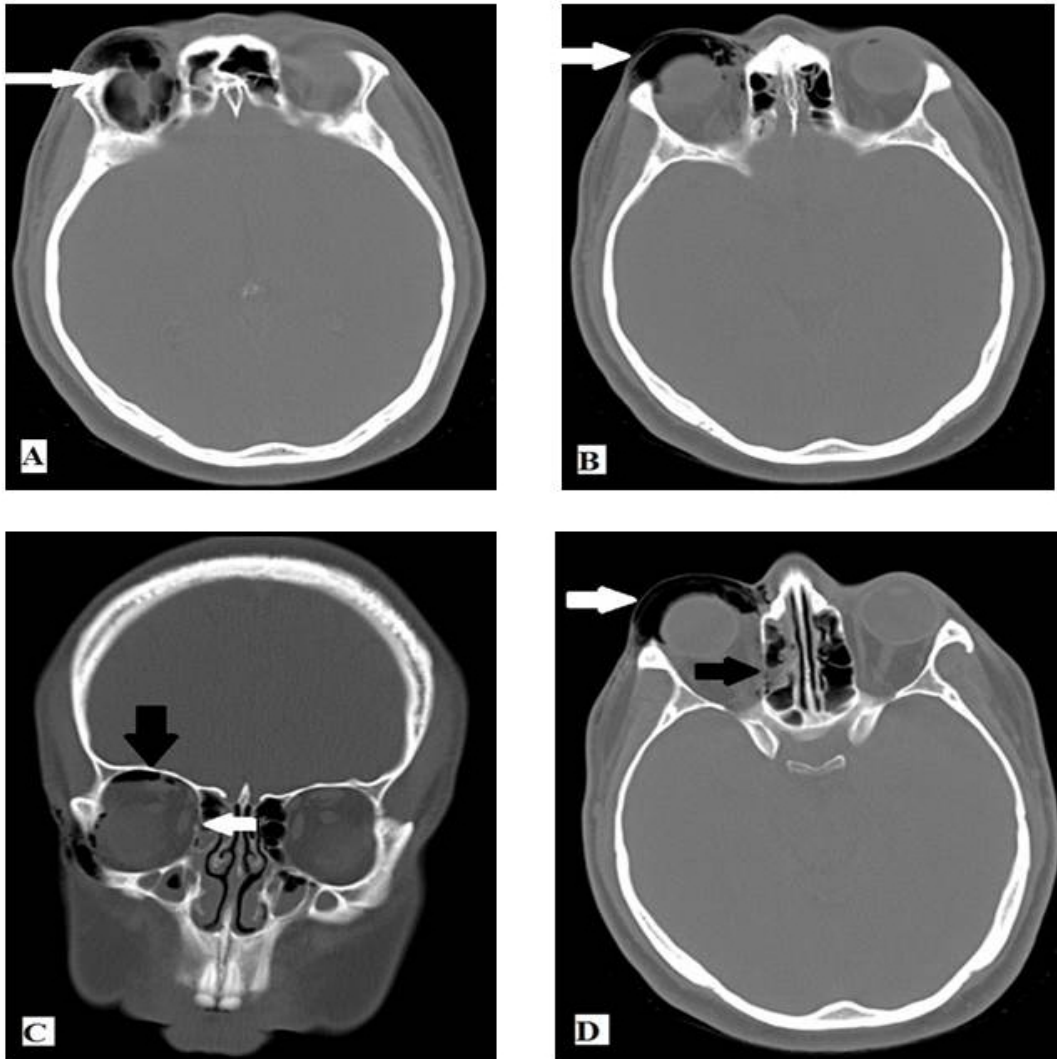


Fig. 2-A. Axial computed tomographic view is showing the right orbital emphysema (white arrow) B: Note the suprapalpebral emphysema (white arrow) C: Coronal computed tomographic view is also showing the right orbital emphysema (black arrow) and fracture on the medial wall of right orbita (white arrow) D: Note the ethmoid sinus lateral fragment fracture (black arrow)

4. CONCLUSION

Emergency physicians should be suspicious about the diagnosis of spontaneous fracture of orbital walls when evaluating the patients with ptosis and upper eyelid swelling without trauma. Subcutaneous orbital emphysema cases with normal ophthalmologic examination can be managed conservatively with close follow-up.

CONSENT

All authors declare that 'written informed consent was obtained from the patient (or other approved parties) for publication of this case report and accompanying images.

ETHICAL APPROVAL

Not applicable.

COMPETING INTERESTS

Authors have declared that no competing interests exist.

REFERENCES

1. Ababneh OH. Orbital, subconjunctival, and subcutaneous emphysema after an orbital floor fracture. Clin Ophthalmol. 2013;7:1077-9. doi: 10.2147/OPTH.S44649. Epub 2013 Jun 5.
2. Alimehmeti R, Gjika A, Kruja J. Orbital emphysema after nose blowing. Neurology. 2011;76(14):1274. doi: 10.1212/WNL.0b013e3182143523.
3. Halpenny D, Corbally C, Torreggiani W. Blowout fracture of the orbital floor secondary to vigorous nose blowing. Ir Med J. 2012;105(7):245-6.
4. Sever M, Buyukyilmaz T. Orbital emphysema due to nose blowing. Turk J Med Sci. 2009;39(1):143-5. doi:10.3906/sag-0711-7
5. Chiu WC, Lih M, Huang TY, Ku WC, Wang W. Spontaneous orbital subcutaneous emphysema after sneezing. Am J Emerg Med. 2008;26(3):381.e1-2. doi: 10.1016/j.ajem.2007.05.021.
6. García-Medina JJ, García-Medina M, Pinazo-Durán MD. Severe orbito-palpebral emphysema after nose blowing requiring emergency decompression. Eur J Ophthalmol. 2006;16(2):339-42.
7. Linberg JV. Orbital emphysema complicated by acute central retinal artery occlusion: Case report and treatment. Ann Ophthalmol. 1982;14(8):747-9.
8. Burm JS, Chung CH, Oh SJ. Pure orbital blowout fracture: New concepts and importance of medial orbital blowout fracture. Plast Reconstr Surg. 1999;103(7):1839-49.
9. Ozdemir O. Orbital emphysema occurring during weight lifting semin ophthalmol. 2014:(in press). doi:10.3109/08820538.2013.874469.
10. Watanabe T, Kawano T, Kodama S, Suzuki M. Orbital blowout fracture caused by nose blowing. Ear Nose Throat J. 2012;91(1):24-5.
11. Shah. Spontaneous subcutaneous orbital emphysema following forceful nose blowing: treatment options. Indian J Ophthalmol. 2007;55(5):395. doi: 10.4103/0301-4738.33834.

© 2014 Metiner et al.; This is an Open Access article distributed under the terms of the Creative Commons Attribution License (<http://creativecommons.org/licenses/by/3.0>), which permits unrestricted use, distribution, and reproduction in any medium, provided the original work is properly cited.

Peer-review history:

The peer review history for this paper can be accessed here:
<http://www.sciencedomain.org/review-history.php?iid=599&id=12&aid=5354>