



# Changes in Liver Histomorphology, Hematological Parameters and Lipid Profile of Cadmium-Exposed Rats Treated with Combined Leaf Extract of *Vernonia amygdalina* and *Occimum gratissimum*

Osuwwe Clement Orororo<sup>a</sup>, Oghenekevwe Efekemo<sup>a</sup>  
and Onoriode Andrew Udi<sup>b\*</sup>

<sup>a</sup> Department of Chemical Sciences (Biochemistry Option), Faculty of Science, Edwin Clark University, Kiangbodo, Delta State, Nigeria.

<sup>b</sup> Human Anatomy Department, College of Basic Health Science, Achievers University Owo, Ondo State, Nigeria.

## Authors' contributions

This work was carried out in collaboration among all authors. All authors read and approved the final manuscript.

## Article Information

DOI: 10.9734/AJMAH/2022/v20i11759

## Open Peer Review History:

This journal follows the Advanced Open Peer Review policy. Identity of the Reviewers, Editor(s) and additional Reviewers, peer review comments, different versions of the manuscript, comments of the editors, etc are available here: <https://www.sdiarticle5.com/review-history/92674>

Original Research Article

Received 09 August 2022  
Accepted 12 October 2022  
Published 31 October 2022

## ABSTRACT

**Aim:** This study was aimed at examining the effect of mixture of *Ocimum gratissimum* extract and *Vernonia amygdalina* extract on lipid profile and hematological parameters of Wistar rats administered with cadmium.

**Methodology:** Sixteen female rats were divided into four groups and designated as follows: Group 1-Control (Normal Saline,) Group 2-(Cadmium 10mg/kg bwt), Group 3 (Normal saline, leaf extract 200kg/kg bwt) Group 4 (Cadmium 10mg/kg bwt and leaf extract 200kg/kg bwt) and were treated for 28 days (4 weeks).

**Results:** Exposure of rats to Cadmium alone (Group B) brought about significant increase in levels of Cholesterol, TAG and LDL with a decrease in HDL compared to control and rats maintained on plant extract alone (Group 3). However, treatment of Cd-exposed rats with mixture of the plant extracts (Group 4) significantly reduced Cholesterol, TAG and LDL with an increase in HDL compared to rats maintained on Cd alone (Group 2). The PCV and RBC of the rats administered

with the cadmium showed a significant reduction when compared to the control group, whereas the WBC increased significantly ( $p < 0.05$ ). The group administered with the leaf extract and a combination of the leaf extract and cadmium recorded an increase in the (PCV), (RBC) level of the Wistar rat and a reduction in the (WBC) level when compared to the group administered with cadmium.

**Conclusion:** The findings of this study demonstrate that mixture of *Ocimum gratissimum* and *Vernonia amygdalina* extracts have lipid lowering properties that may be advantageous to those with the problem of cadmium toxicity. The extracts were also found to be efficient in decreasing cholesterol, triacylglyceride, and low density lipoprotein levels, indicating that they have hypocholesterolaemic properties.

**Keywords:** *Vernonia amygdalina*; *Ocimum gratissimum*; haematology; lipid profile.

## 1. INTRODUCTION

“Cadmium (Cd) is ubiquitous in nature and to great extent it is concentrated in the food chain due to its high soluble nature compared to other toxic heavy metals. It is not degradable, consequently it is easily transported from soil to plants which animals and humans largely depend on for survival” [1]. Studies conducted by Vasey, [2] stated that there are two main ways for ionic form of  $Cd^{2+}$  to get through the hepatocyte cell membrane: (a) binding with  $Fe^{2+}$  and  $Zn^{2+}$  transporters, or (b) through voltage-gated  $Ca^{2+}$  channels. Protein-bound Cd usually binds to liver-produced metallothionein (MT) protein to form Cd metallothionein (Cd-MT) complex, which enters cells through receptor-mediated endocytosis and is then released from the Cd-MT as a Cd ion through the digestion of lysosome. Chronic Cd ion is stored in various tissues such as the liver, kidney, prostate and bone [3]. “In the female liver, Cd absorption is 10%–20% higher than in males, and the female liver is more susceptible to Cd toxicity. This difference may be related to progesterone-activated receptor-dependent calcium channels, channels that are involved in the absorption and accumulation of Cd into the liver” [4]. “It was also documented in a study that the deposition of Cd in the liver can cause both liver injury and hepatotoxicity” [5].

Extensive research on the molecular mechanism of Cd carcinogenesis has shown that chronic Cd exposure can induce oxidative stress interfere with gene expression [6], affect cell cycle regulation, inhibit cell apoptosis, induce inflammatory signaling, and promote genomic instability and mutation in key genes to promote tumorigenesis [7]. Indeed, high concentrations of Cd from acute exposure or low concentrations of chronic exposure are both linked to severe hepatotoxicity/liver injury that promotes liver diseases and HCC development.

Generally, the properties of antioxidant of various plants have been applied in the treatment of different diseases especially in developing countries where they have been documented in traditional medicine [8]. A study had revealed about 80% of individuals with the use of traditional medicine in developing countries to meet up their primary health care needs [9]. The phytochemical evaluation of *Ocimum gratissimum* (OG) revealed the following bioactive compounds; flavonoids, triterpenes, alkaloids, citral, saponins, eugenol, and thymol etc [9]. Flavonoids compounds have been described with biological activities such as, anti-inflammatory, antitumor and antioxidant [10] activities. According to a study by Udi et al. [11], *Ocimum gratissimum* has ameliorative properties since it slows the degradation of the purkinje cells in the cerebellum of male Wistar rats exposed to lead acetate. Additionally, this is consistent with the findings of the study on the effects of Lead II Acetate-induced PhysioMorphological Changes in Prefrontal Cortex of *Ocimum gratissimum*-fed wistar Rats [12], which found that *Ocimum gratissimum* counteracts the negative effects of lead acetate on the pyramidal cells of the prefrontal cortex.

“*Vernonia amygdalina*, popularly called bitter leaves belong to the family Asteraceae or Compositae, is consumed locally as food and for ethno-medicinal uses. The bitter taste of *Vernonia amygdalina* comes from the phytochemicals of the leaves, which include alkaloids, saponins, glycosides, and tannins” [13].

“Naringenin also restored the levels of antioxidant defense to normal levels and preserved the normal histological architecture of the liver tissue” [14]. “Similarly, a protective effect of alpha-tocopherol (vitamin E) on Cd toxicity in rat liver has been shown. Coadministration of

vitamin E (300 mg/Kg/day for 3 weeks) decreased prooxidative state hepatic markers such as malondialdehyde (MDA) and peroxidase (POD) activities that are induced by Cd exposure and also increased superoxide dismutase (SOD) and catalase (CAT) activities, restored Ca levels, and improved liver architecture" [15]. "In addition, olive oil and colocynth oil prevented oxidative damage in Wistar rat livers induced by Cd. Cotreatment with olive oil or colocynth oil restored the antioxidant potential in plasma and liver and decreased MDA levels and transaminase activity" [16]. "Ferulic acid (FA) derivatives of curcumin also contribute to liver repair. An intriguing recent study found that adding FA (50 mg/kg) to the diet dramatically reduced Cd accumulation in rat liver and kidney tissues by increasing the expression of antioxidant enzymes and lowering the expression of hepatonephrotoxic enzymes" [17]. The aim of this study was therefore to examine the ameliorative effects of combined leaf extracts of *Ocimum gratissimum* and *Vernonia amygdalina* on the lipid profile, hematology and histomorphology of Cadmium induced liver of an adult Wistar rats.

## 2. MATERIALS AND METHODS

### 2.1 Extraction

The leaves were destalked from the stem, sorted, washed with distilled water and air dried in a room temperature for 21 days. Milled to powder and stored in an airtight beaker, 140g of the plant sample were extracted on a Soxhlet extractor using ethanol (96%) and water as the extraction solvents. The resulting eluate was dried at 40°C and reconstituted in distilled water to appropriate concentrations.

### 2.2 Experimental Design

This was an experimental study involving sixteen (16) Wistar rats which were purchased from the animal house of the Faculty of Basic Medical Sciences, Delta State University, Abraka weighing between 120-200g were divided at random into four (4) groups of 4 animals each of female Wistar rats thus: Group A – control fed with normal feed and water alongside with normal saline. Group B – Fed with Normal feed and water alongside with administration of 1mg of cadmium (14 days to study the direct effect of Cadmium). Group C – Fed with Normal feed and water alongside with administration of 1mg of Extract (14 days to study the direct effect of *Ocimum gratissimum* and *Vernonia amygdalina*

extracts). Group D – Fed with Normal feed, water and 1mg of cadmium along side with 1mg of the extract was administered (14 days to study the ameliorating effects of the extracts).

### 2.3 Blood Sample and Organ Collection

At the end of the treatment period the experimental rats were sacrificed by cervical dislocation. Blood samples were collected by cardiac puncture and dispensed into heparinized bottles for clinical chemistry analysis and EDTA (Ethylenediaminetetra acetic acid) container for haematological tests centrifuged at 5000g for 10 minute. Sera and supernatants collected and were stored frozen until used for analysis.

### 2.4 Assessment of Biochemical Parameters

**Determination of Serum Total Cholesterol Using Randox Assay Kit:** Test tubes labeled "blank," "Test," and "Standard" received exactly 10 µl each of distilled water, sample, and standard (CAL). Following that, each test tube received 1000 µl of reagent. Following their mixing and 5-minute incubation at 37°C, the absorbance of the sample (A<sub>sample</sub>) and standard (A<sub>standard</sub>) were measured at 500 nm within 60 minutes against the reagent blank.

**Determination of low density lipoprotein Cholesterol (LDP-C) Using Randox Assay Kit:** 0.2 µl sample and reagent (A) was pipetted into centrifuge tubes mixed thoroughly and stand for 15minutes at room temperature, was centrifuge at a minimum of 4000 r.p.m. for 15minutes. Supernatant was carefully collected. After which the reagent (cholesterol kit) to room temperature, then pipette into a test tubes.

**Determination of High density lipoprotein Cholesterol (HDP-C) Using Randox Assay Kit:** 200 µl of sample was Pipetted into centrifuged tubes then 500 µl was used to dilute the precipitant, after which it was mix thoroughly and allowed for 10 minutes at room temperature. Then it was centrifuge at 4,000 rpm for 10 minutes at 12,000 rpm. Then the clear supernatant was carefully removed using a pipette.

**Determination of Serum Triglycerides using Manuel Method:** three glass stoppered tubes was set up which contains the test, standard and blank, the tubes were mix for 30 seconds in a vortex mixer, then the tubes were stand at a room temperature for 10 minutes for clear

separation of two layers. There after the top solvent layer was used for further assay.

**Determination of the red blood percentage using a centrifugation technique:** The capillary tube was filled with sample (blood). After which it was cleaned with a cottonwood. The tip was steel with plasticine to avoid spillage of blood while spinning. Thereafter Capillary tube was place on the hematocrit centrifuge, then was allow to spin for 5min at 12,000rpm. After which the capillary tube was brought out and was placed on the hematocrit reader at the eye level, then the reading was taking.

**Determination of Red blood cell:** Whole blood is diluted appropriately using an isotonic diluent to avoid lysis of red cells.

The number of red cells in a known volume and of known dilution is counted using a counting chamber.

**Determination of Red blood cell:** The estimation of the White blood cell was as described for RBC.

## 2.5 Analysis of Data

Data were expressed as mean $\pm$  standard error m(SEM) the mean valves between the groups were compared by using analysis of variance (ANOVA) and least significance test (LSD) producer using the software (SPSS). The results were considered significant at  $p < 0.05$  level.

## 3. RESULTS

### 3.1 Effect of Combined Leaf Extract of *Vernonia amygdalina* and *Ocimum gratissimum* on Lipid Profile on Cadmium Induced Wistar Rats

The effect of combined leaf extract of *Vernonia amygdalina* and *Ocimum gratissimum* on lipid profile on cadmium induced wistar rats is presented in Table 1. The effect of *Vernonia amygdalina* and *Ocimum gratissimum* on lipid profile on cadmium induced Wistar Ratsshowed There was a significant increase in the level of serum cholesterol, triglyceride and LDL levels in group administered with only cadmium when compared with the control group ( $p < 0.05$ ), while those administered with only the plant extract and a combination of the plant extract and cadmium showed significant decrease in level of cholesterol, triglyceride, high density lipoprotein, and low density lipoprotein when compared to the group administered with cadmium only. High density lipoprotein (HDL) level of group administered with cadmium only recorded a significant decrease when compared to those of the control group ( $p < 0.05$ ).

The administration of the extract to Cd-exposed rats brought about significant reduction in cholesterol, TAG and LDL compared to rats maintained on Cd alone (Table 1).

**Table 1. Effect of combined leaf extract of *Vernonia amygdalina* and *Ocimum gratissimum* on lipid profile on cadmium induced Wistar Rats**

Groups	Cholesterol	Lipid profile Triglyceride	HDL	LDL
Group A	25.73 $\pm$ 0.70 <sup>a</sup>	23.50 $\pm$ 0.96 <sup>a</sup>	3.29 $\pm$ 0.17 <sup>a</sup>	19.02 $\pm$ 0.34 <sup>a</sup>
Group B	44.59 $\pm$ 3.59 <sup>bc</sup>	28.99 $\pm$ 0.98 <sup>bc</sup>	2.15 $\pm$ 0.36 <sup>bc</sup>	37.71 $\pm$ 2.88 <sup>bc</sup>
Group C	19.67 $\pm$ 0.33 <sup>ade</sup>	17.66 $\pm$ 0.34 <sup>ade</sup>	5.43 $\pm$ 0.11 <sup>ade</sup>	14.51 $\pm$ 0.15 <sup>ade</sup>
Group D	33.34 $\pm$ 0.70 <sup>adf</sup>	25.49 $\pm$ 0.68 <sup>adf</sup>	3.08 $\pm$ 0.04 <sup>adf</sup>	21.80 $\pm$ 0.83 <sup>adf</sup>

Values are Mean $\pm$ standard Error Mean (SEM). Values with different superscript are statistically different at ( $p < 0.05$ ). superscript (a,b) compares Group B, Group 3 and Group 4 to Group A (1<sup>st</sup> letters) along the column. Superscript (c,d) compares Group C and Group D to Group 2 (2<sup>nd</sup> letters) along the column while Superscript (e,f) compares Group D to Group 3 along the column

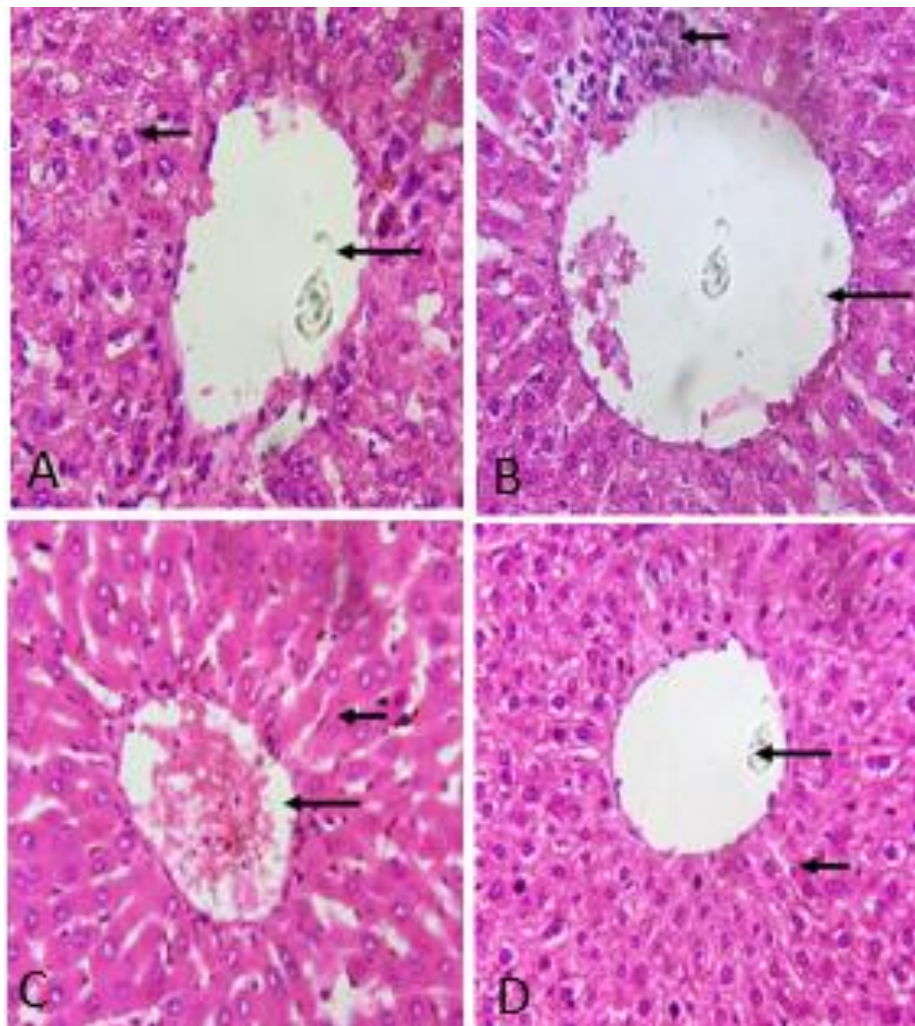
### 3.2 Effect of Combined Leaf Extract of *Vernonia amygdalina* and *Ocimum gratissimum* on Hematological Parameters on Cadmium Induced Wistar Rats

The effect of combined leaf extract of *Vernonia amygdalina* and *Ocimum gratissimum* on Hematological Parameters on cadmium induced Wistar Ratsshowed a significantly reduction in the packed cell volume (PCV) and red blood cell (RBC) level of the rats when compared to the control group, while the white blood cell (WBC) level increased ( $p < 0.05$ ). The group administered with the extract and a combination of the extract and cadmium recorded an increased in the packed cell volume (PCV) and red blood cell (RBC) level of the wistar rats and a reduction in the white blood cell (WBC) level when compared to the group administered with cadmium below.

**Table 2. Effect of combined leaf extract of *Vernonia amygdalina* and *Ocimum gratissimum* on lipid profile on cadmium induced Wistar Rats**

Groups	Hematological parameters		
	PCV	RBC	WBC
Group A	31.33 ± 1.20 <sup>a</sup>	5.00±0.42 <sup>a</sup>	4833.33 ± 88.19 <sup>a</sup>
Group B	20.67±1.20 <sup>b,c</sup>	3.97±0.09 <sup>b,c</sup>	7766.67 ± 284.80 <sup>b,c</sup>
Group C	34.00±0.58 <sup>a,d,e</sup>	5.33±0.09 <sup>a,d,e</sup>	4566.67 ± 66.67 <sup>a,d,e</sup>
Group D	29.33±0.88 <sup>a,d,f</sup>	4.47±0.15 <sup>a,d,f</sup>	5033.33±120.19 <sup>a,d,f</sup>

Values are Mean ± Standard Error Mean (SEM). Values with different superscript are statistically different at ( $p < 0.05$ ). Superscript (a,b) compares Group B, Group C, (1<sup>st</sup> letters) along the column. Superscript (c,d) compares Group C and Group D to Group B (2<sup>nd</sup> letters) along the column while superscript (e,f) compares Group D to Group C along the column



**Fig. 1. Histopathological slides**

- A:** Liver centriole appears normal, large and distinct (long arrow). The hepatocytes also reveal normal nucleus (short arrow).
- B:** Liver centriole appears large with thickened wall (long arrow). The hepatocytes also reveal slightly pyknotic nucleus with focal pool of mononuclear infiltrates (short arrow).
- C:** Liver centriole appears large and distinct surrounded by mild mononuclear cells (long arrow). The hepatocytes also reveal slightly vacuolated nucleus with mild fatty changes (short arrow).
- D:** Liver centriole appears large and distinct surrounded (long arrow). The hepatocytes also reveal pyknotic nucleus (short arrow)

#### 4. DISCUSSION

The study clearly shows that the administration of the combined extract of *Ocimum gratissimum* and *Vernonia amygdalina* (Group C) decreased the cholesterol, triacylglycerol and low density lipoprotein (LDL) level of the experimental animal significantly ( $p < 0.05$ ) when compared to the control (Group A) while the level of high density lipoprotein (HDL) increased significantly. Whereas, Wistar rat induced with Cadmium and combined plant extract (Group D) displayed an increased in the lipid profile of the Wistar rat with the exception of the high density lipoprotein (HDL) which showed a significant reduction ( $p < 0.05$ ). Adaramoye et al. [18] also reported a decrease in the cholesterol, glyceride, low density lipoprotein (LDL) level of Wistar rat administered with different dose of *Vernonia amygdalina* and an increase in the high density lipoprotein (HDL) level when compared to those of the control, this is in agreement with the findings of this present study.

“Lipid disorders play a key role in the pathogenesis and progression of atherosclerosis and cardiovascular disease, according to research, and environmental factors play a role in these disorders as well” [19]. “The use of medicinal plants for therapeutic purposes are increasingly becoming prevalent in modern society as alternatives to synthetic medicines. Various parts of *Ocimum gratissimum*, including the leaves, stems, and roots, are used pharmaceutically in folklore medicine to treat various ailments and diseases such as diabetes, hypertension, pile, rheumatism, and others” [20].

Nonetheless, some unfavorable effects of *Vernonia amygdalina* have been documented, indicating that the saponin fractions of the extract have a hemolytic effect [21]. Wistar rats' body weight was significantly reduced after prolonged feeding with *Vernonia amygdalina* leaves, according to Asuquo et al. [22]. This corroborate with this present study where Wistar rat administered with the combined extract of *Ocimum gratissimum* and *Vernonia amygdalina* (Group C) displayed a significant decrease in the weight of the rat when compared to those of the control group (Group A) and groups administered with cadmium (Groups B and D). Cholesterol is an important chemical involved in a variety of cellular processes, including membrane fluidity, vitamin D generation on the skin's surface, hormone manufacturing, and even aiding cell

connections in the brain [23]. It is critical that the body's cells receive an adequate quantity of cholesterol.

When cholesterol levels in the blood increase, unfortunately, it can have negative implications. Cholesterol, in particular, has gained prominence for its role in the development of atherosclerosis, the leading cause of mortality in affluent countries around the world [23]. The therapeutic effects of plant foods have been the focus of many significant dietary research because great efforts have been made to reduce the risk of cardiovascular illnesses through cholesterol management [24,23].

Reduced erythrocyte survival is one of the adverse implications of this membrane lipid peroxidation [25]. The results obtained from this study, it is apparent that the RBC parameters measured (Group B) decrease significantly which is an indication of reduced and abnormal erythropoiesis. This observation is consistent with the reports of Ekweogu et al. [26] but differ from the reports of Akpaso et al. [13]. “Administration of combined extract of *Ocimum gratissimum* and *Vernonia amygdalina* to cadmium induced rats appreciably improved the levels of red blood cell (Group D) (RBC) and its indices ( $p < 0.05$ ). This suggests that some phytoconstituents present in the extract can stimulate the formation or secretion of erythropoietin which stimulates the stem cells in the bone marrow to produce RBC” [27].

“The white blood cell (WBC) acts as a scavenger, removing foreign chemicals from the body. The number of white blood cell (WBC) is known to increase in response to a hazardous environment as a body defense mechanism” [28]. Changes in white blood cell (WBC) ((Groups B and D) have been linked to cardiovascular problems [29]. Coronary artery disease, insulin resistance, Type 2 diabetes, stroke, and diabetes-induced macro and microangiopathy have all been linked to leukocytosis [30]. AGEs, oxidative stress, angiotensin II, and pro-inflammatory cytokines have all been shown to activate leucocytes [30]. The result of this study (Group B) showed a significant ( $P < 0.05$ ) increase in WBC of cadmium induced Wistar rats which became reduced significantly (Group D) ( $P < 0.05$ ) on combined extract of *Ocimum gratissimum* and *Vernonia amygdalina* treatment. This may have been as a result of the ability of the extract to

ameliorate AGEs production and reduce oxidative stress within the blood cells. This finding is in agreement with earlier reports [30]. When compared to the control, (Fig. 1) group B's histology findings showed a pyknotic nucleus with a focused pool of mononuclear infiltrates. This is in accordance with the current study. According to Athmouni's research [5] on *Periploca angustifolia* polysaccharides and chelation therapy for cadmium-induced liver toxicity, Cd buildup in the liver can result in both liver damage and hepatotoxicity. The group that got cadmium, *Vernonia amygdalina*, and *Ocimum gratissimum* (Group D) demonstrated pyknotic nuclei without a focal pool of mononuclear infiltrates, indicating an ameliorative effect of the extracts.

## 5. LIMITATIONS OF STUDY

The study was limited to unavailability equipment to conduct a smooth research, it also suffered several challenges such as finance, and time.

## 6. CONCLUSION

The findings of this study demonstrated that *Ocimum gratissimum* and *Vernonia amygdalina* extracts have lipid lowering properties. The extracts were also found to be efficient in decreasing cholesterol, triacylglyceride, and LDL levels, indicating that they have hypocholesterolaemic properties. The study also shows that the combined plant extract can enhance hematological parameters in Wistar rats who have been exposed to Cadmium. Finally, the study's findings revealed that the combined extracts diet preparation had greater anti lipidemic and hematological properties, suggesting ameliorative effects to persons exposed to cadmium.

## 7. RECOMMENDATION

Owing to the finding of this study it is recommended that the combined plant extract of *Ocimum gratissimum* and *Vernonia amygdalina* should be explored for its adjuvant therapy for the management of diabetes mellitus treatment.

## CONSENT

It is not applicable.

## ETHICAL CONSIDERATION

Approval for this study was obtained from the Ethical Committee of the Faculty of Basic Medical Sciences, Delta State University, Abraka, via a letter with reference number RBC/FBMS/DELSU/21/08 on the use and care of animals for research.

## COMPETING INTERESTS

Authors have declared that no competing interests exist.

## REFERENCES

1. Del Pino J, Zeballos G, Anadon MJ, Capo MA, Díaz MJ, García J, Frejo MT. Higher sensitivity to cadmium induced cell death of basal forebrain cholinergic neurons: A cholinesterase dependent mechanism. *Toxicology*. 2014;325:151-59.
2. Vesey DA. Transport pathways for cadmium in the intestine and kidney proximal tubule: Focus on the interaction with essential metals. *Toxicology Letters*. 2010;198 (1):13–19.
3. Zhang T, Hu Y, Tang M, Kong L, Ying J, Wu T, Xue Y, Pu Y. Liver toxicity of cadmium telluride quantum dots (CdTe QDs) due to oxidative stress in vitro and in vivo. *Int J Mol Sci*. 2015;16(23):279-299.
4. Imafidon CE. Acetonic extract of *Vernonia amygdalina* (Del.) attenuates Cd-induced liver injury: Potential application in adjuvant heavy metal therapy. *Toxicology Reports*. 2018;5:324–332.
5. Athmouni K. Optimization, antioxidant properties and GC-MS analysis of *Periploca angustifolia* polysaccharides and chelation therapy on cadmium-induced toxicity in human HepG2 cells line and rat liver. *International Journal of Biological Macromolecules*. 2018;108:853–862.
6. Buha A, Jugdaohsingh R, Matovic V, Bulat Z, Antonijevic B, Kerns JG, Goodship A, Hart A, Powell JJ. Bone mineral health is sensitively related to environmental cadmium exposure-experimental and human data. *Environ. Res*. 2019;176: 108539.
7. Venza M. Epigenetic effects of cadmium in cancer: Focus on melanoma. *Current Genomics*. 2014;15(6):420–435.
8. El-Boshy ME. Protective effects of selenium against cadmium induced

- hematological disturbances, immune-suppressive, oxidative stress and hepatorenal damage in rats. *Journal of Trace Elements in Medicine & Biology*. 2015;29:104–110.
9. Alara OR, Nour A, Abdul-mudalip SK, Olalere OA. Phytochemical and pharmacological properties of *Vernonia amygdalina*-A REVIEW. *J Chem. Eng. & Industrial Bio-technol*. 2017;80-96.
  10. Yeap SK, Ho WY, Beh BK, Liang WS, KYH, Hadi A, Alitheen NB. *Vernonia amygdalina*, an ethnomedical used green vegetable with multiple bio-activities. *J Med Plants Res*. 2014;4(25):2787–2812.
  11. Udi OA, Oyem JC, Ebeye OA, Chris-Ozoko LE, Igbigbi PS, Olannye DU. The effects of aqueous extract of *Ocimum gratissimum* on the cerebellum of male wistar rats challenge by lead acetate. *Clinical Nutrition Open Science*. 2022;44: 28-41.
  12. Udi OA, Igbigbi PS, Chris-Ozoko LE, Oyeleke AA. Lead II acetate induced Physio-Morphological changes in prefrontal cortex of *Ocimum gratissimum* fed Wistar Rats. 2018;1(1):1-10
  13. Akpaso MI, Atangwho IJ, Akpantah A, Fischer VA, Igiri AO, Ebong PE. Effect of combined leaf extracts of *Vernonia amygdalina* (Bitter Leaf) and *Gongronema latifolium* (Utazi) on the Pancreatic  $\beta$ -Cells of Streptozotocin-Induced Diabetic Rats. *British Journal of Medicine & Medical Research*. 2011;1(11):24–34.
  14. Athmouni K. Development of catechin-phospholipid complex to enhance the bioavailability and modulatory potential against cadmium-induced oxidative stress in rat's liver. *Archives of Physiology and Biochemistry*. 2020;126(1):82–88.
  15. Bahri S. Protective role of vitamin E against cadmium induced oxidative stress into the rat liver. *Tunisie Medicale*. 2019; 97(1):100–105.
  16. Amamou F. Protective effect of olive oil and colocynth oil against cadmium-induced oxidative stress in the liver of Wistar rats. *Food and Chemical Toxicology*. 2015; 78:177–184.
  17. Sanjeev S. Influence of ferulic acid consumption in ameliorating the cadmium-induced liver and renal oxidative damage in rats. *Environmental Science and Pollution Research International*. 2019;26 (20):20631–20653.
  18. Adaramoye OA, Akintayo O, Achem J, Fafunso MA. Lipid lowering effects of methanolic extract of *Vernonia amygdalina* leaves in rats fed on high cholesterol diet. *Vascular Health Risk Management*. 2008;4:235-241.
  19. Afolabi TA, Ogbunneke CC, Ogunkunle OA, Bamiro FO. Comparative assessment of the potable quality of Water from industrial, urban and rural parts of Lagos, Nigeria. *Ife Journal of Science*. 2012;14(2):221–231.
  20. Oyem JC, Chris-Ozoko LE, Enaohwo MT, Otabor FO, Okudayo VA, Udi OA. Antioxidative properties of *Ocimum gratissimum* alters lead acetate induced oxidative damage in lymphoid tissues and hematological parameters of adult Wistar rats. *Toxicology Reports*. 2021;8:215-222.
  21. Nimembo-Uadia R. Effect of *Vernonia amygdalina* in alloxan-induced diabetic albino rats. *J. Med Lab Sci*. 2003;12(1):25-31.
  22. Asuquo O, Edet A, Mesembe O, Atanghwo J. Ethanolic extracts of *Vernonia amygdalina* and *Ocimum gratissimum* enhance testicular improvement in diabetic Wistar rats. *The Internet Journal of Alternative Medicine*. 2009;8(2):1–6.
  23. Daniels TF, Killinger KM, Michal JJ, Wright Jr, RW, Jiang Z. Lipoproteins, cholesterol homeostasis and cardiac health. *Int J Biol Sci*. 2009;29 (5):474-88.
  24. Udi OA, Chris-Ozoko LE, Iteire AK, Enaohwo TM, Ewere B. Histologic effect of garlic extract on the spleen of adult wistar rat. *J. Pharm Biol. Sci*. 2017;12:1-4.
  25. Osigwe CC, Akah PA, Nworu CS. Biochemical and haematological effects of the leaf extract of *Newbouldia laevis* in alloxan-induced diabetic rats. *Journal of Biosciences and Medicines*. 2017;5(6):18–36.
  26. Ekweogu CN, Ude VC, Nwankpa P, Emmanuel O, Ugbog EA. Ameliorative effect of aqueous leaf extract of *Solanum aethiopicum* on phenylhydrazine-induced anaemia and toxicity in rats. *Toxicol Res*. 2020;36(3):227–238.
  27. Quasie O, Zhang Y, Zhang H, Luo J, Kong L. Four new steroid saponins with highly oxidized side chains from the leaves of *Vernonia amygdalina*. *Phytochem Lett*. 2016;15:16–20.
  28. Ngogang JY. Haematinic activity of *Hibiscus cannabinus*. *African Journal of Biotechnology*. 2005;4:833-837.



29. Mohammed B, Gabel M, Karlsson LM. Nutritive values of the drought tolerant food and fodder crop enset. Afr. J. Agric. Sci. 2013;8(20):2326-2333.
30. Mahmoud AM. Hematological alterations in diabetic rats - Role of adipocytokines and effect of citrus flavonoids. Excli J. 2013;12: 647–657.

© 2022 Orororo et al.; This is an Open Access article distributed under the terms of the Creative Commons Attribution License (<http://creativecommons.org/licenses/by/4.0>), which permits unrestricted use, distribution, and reproduction in any medium, provided the original work is properly cited.

*Peer-review history:*  
*The peer review history for this paper can be accessed here:*  
<https://www.sdiarticle5.com/review-history/92674>