



A Case of Overlapping Autoimmune Sclerosing Cholangitis and Autoimmune Hemolytic Anemia

**Mouayad Al Shtawi^a, Ashraf ALakkad^{b*}, Naser Al Zein^c,
Amer Masaud Azaz^{d#} and Imad Shubbar^a**

^a Pediatric Department, Delma Hospital, AL Dhafra Region, UAE.

^b Department of Internal Medicine, Madinat Zayed Hospital, AL Dhafra region, UAE.

^c Pediatric Hematology & Oncology Department, Division Chief of Pediatric hematology & Oncology, Sheikh Khalifa Medical City, Abu Dhabi, UAE.

^d Pediatric Department, Sheikh Khalifa Medical City, Abu Dhabi, UAE.

Authors' contributions

This work was carried out in collaboration among all authors. All authors read and approved the final manuscript.

Article Information

DOI: 10.9734/IBRR/2022/v13i330178

Open Peer Review History:

This journal follows the Advanced Open Peer Review policy. Identity of the Reviewers, Editor(s) and additional Reviewers, peer review comments, different versions of the manuscript, comments of the editors, etc are available here: <https://www.sdiarticle5.com/review-history/86960>

Received 01 March 2022

Accepted 09 May 2022

Published 09 May 2022

Case Study

ABSTRACT

This case study revolves around a 14-year old female patient, who was otherwise healthy and normal, but brought to the hospital for her condition. The patient presented with complaints of fever, sore throat, severe abdominal pain, and generalized body aches for the last two days.

She appeared to be lethargic and weak. Her condition had made her fatigued and a yellowish tinge of the face and sclera was obvious, pointing towards a likely case of jaundice. Upon abdominal examination, the patient also had hepatomegaly and splenomegaly present, and the muscles appeared to be tender as well.

The child was admitted to the hospital, where her lab investigations revealed that she was anemic. Other investigations revealed that her liver enzymes and bilirubin levels were significantly elevated. Her DAT was positive and there was a presence of high eosinophilia.

However, her Hepatitis A, B, and C screening came out to be negative. She was kept as a suspected case of Autoimmune Hemolytic Anemia as it appeared to be the most probable diagnosis, given her condition, but following a biopsy she was also confirmed as a case of Autoimmune Sclerosing Cholangitis.

Pediatric Consultant

*Corresponding author: E-mail: ashraf.alaqqad@gmail.com;

Once the diagnosis was confirmed, the child was treated accordingly. This was a unique case because it involved a significant overlap in the presence of two diseases. Both of the diseases, although similar in appearance, could have caused great havoc if they were not separately diagnosed and treated accordingly.

This case study deals with such an overlapping case that was brought to the hospital. With a myriad of confusing symptoms, it was obvious that the diagnosis could have been misdiagnosed or incorrectly diagnosed. However, the lab reports and examinations that were carried out smartly helped in excluding the other diagnoses which would have obviously lead to confusions and also in starting the wrong treatment.

This case study deals with the examination, laboratory protocols, along with the association of symptoms, all of which help in reaching towards the final diagnosis in a timely manner and thus, helped treat the patient effectively.

The case study also highlights how both of these diseases present in a patient of the younger population, and how they need to be managed effectively and efficiently to ensure that there are no complications that might alter the already deteriorating state of the patient.

Keywords: Autoimmune hemolytic anemia; Autoimmune sclerosing cholangitis; DAT.

1. INTRODUCTION

Autoimmune Hemolytic Anemia is a rare heterogeneous disorder that is hereditary in nature. In this disorder, there is an acquired premature destruction of red blood cells (RBCs) by the body's own immune system that seems to have generated antigens against the premature RBCs [1].

There are four major serological types of autoimmune hemolytic anemia that exist to date: Warm Autoimmune Hemolytic Anemia, Cold Agglutinin Disease, Mixed Type, and also Paroxysmal Cold Hemoglobinuria [2].

However, just like in the case of any other undiagnosed yet suspected anemia, there is also a systematic way of approaching this particular type of anemia. Since hemolysis is the initiating factor in Autoimmune Hemolytic Anemia, it is not difficult to guess that why hemolysis would be the first warning or alerting sign that would ultimately lead the physician to carry out further investigations to establish this diagnosis. Hemolysis is also the one common factor that is involved in the pathogenesis in all types of AIHA.

However, the commonly noticed signs in Autoimmune Hemolytic Anemia include either a normocytic or macrocytic anemia, raised reticulocyte count, raised unconjugated bilirubin levels, or the presence of spherocytes or agglutination on blood smears, as well as reduced haptoglobin levels. All these factors are confirmed signs that lead one to the diagnosis of Autoimmune Hemolytic Anemia in a given patient [3].

Once a confirmed diagnosis has been established and the patient has been informed about their illness, the next step is to deduce a treatment option that is deemed appropriate according to the clinical picture of the patient. There is no final treatment that puts an end to this disease or resolves it completely, and so in every case, supportive measures need to be continued for the rest of the patient's life [4].

The patient whose case is being discussed also presented with complaints that were consistent with Autoimmune Sclerosing Cholangitis. This condition is often referred to as 'Overlap Syndrome', mainly because it is seen to commonly overlap with both the clinical and morphological features of Primary Sclerosing Cholangitis (PSC) and Autoimmune Hepatitis [5].

The key factor here is the involvement of the immune system. Being an autoimmune disease, there is no clear initiating or triggering factor for this disease. It clearly seems to stem from disturbances or problems in the immune system of a patient, who is most commonly of a young age [6].

Because of the presence of an obvious and confusing overlapping clinical picture, it is often difficult to diagnose this condition, and thus, delays are often encountered. The final solution to tackle this issue is to only rely upon the cholangiographic diagnosis on the presence of structures within the biliary tree to establish the diagnosis [7].

This case study aims to reflect at each perspective of the case. It is vital for every

physician to be aware regarding the types of clinical scenarios that may arise in their clinical settings, such as in this case of Overlap Syndrome. This case study will make it easier to understand how such cases with overlapping symptoms are diagnosed, managed, and treated in such an effective manner that makes sure to avoid any impeding complications.

2. CASE STUDY

This case revolves around a 14-year old female child. The child was previously in a healthy and normal state. However, she was brought to the hospital with presenting with complaints of fever, sore throat, and generalized body pains for the last three days. She also had severe abdominal pain and because of this condition, she appeared to be generally unwell and fatigued.

In response to the severity of her condition, she was directly admitted to the hospital.

2.1 Examinations

Upon examining her in detail, it was found that the patient appeared pale. She had obvious signs of jaundice as her face and sclera both had a yellowish tinge. She also complained about passing darker than normal urine.

Her vitals were as follows: temperature 37.1C, peripheral pulse 88, blood pressure 108/72 mm Hg, oxygen saturation 100%.

The child also complained of muscle tenderness and this was confirmed by her general physical examination.

Her abdominal examination revealed that she also had hepatomegaly (extending 3 cm below the costal margin) and splenomegaly.

2.2 Laboratory Analysis

The laboratory investigations that were carried out on the patient along with their respective results have been summarized as follows:

Table 1. laboratory investigations

Hepatitis Bs Ag Screen	Negative		PT	15.0 sec(s)	(12.0 - 15.0)
Hep Bs Ab	Negative		INR	* 1.2	(0.7 - 1.1)
Hep Bs Ab Titer	6.950 IU/L		APTT	* 44.8 sec(s)	(27.7 - 42.1)
Hep Be Ag	Negative	(Negative -)	Fibrinogen Lvl	3.20 g/L	(2.00 - 4.00)
Hep B Core Ab	Negative		Anticoagulant?	None	
Hep B Core IgM Ab	Negative	(Negative -)	D-Dimer Auto	* 0.43 mcg/mL	(- <=0.50)
Hepatitis C Ab Screen	Negative		Hepatitis Bs Ag Screen	Negative	(Negative -)
Hep A Ab	Negative		ANA	* Negative	
DAT Poly	Positive		CMV IgG	Positive	(Negative -)
Glucose Random	6.56 mmol/L	(- <=8.80)	CMV IgG Abs	* > 250.0 AU/mL	
Total Protein	72.3 g/L	(60.0 - 80.0)	CMV IgM	Negative	(Negative -)
Albumin Lvl	39.1 g/L	(35.0 - 50.0)	CMV IgM Titer	0.080	
Bili Total	52.1 micromol/L	(0.0 - 17.1)	EBV Capsid Antigen IgG	Positive	(Negative -)
Bili Direct	44.8 micromol/L	(0.0 - 3.4)	EBV Capsid Antigen IgM	Negative	(Negative -)
Alk Phos	510.8 IU/L	(- <=187.0)	EBV Nuclear Antigen IgG	Positive	(Negative -)
AST	279.3 IU/L	(0.0 - 32.0)	Hep B Core IgM Ab	Negative	(Negative -)
ALT	223.2 IU/L	(0.0 - 31.0)	HSV 1/2 IgM	Negative	(Negative -)
EBV Capsid Antigen IgG	Positive	(Negative -)	LKM Abs	* Negative	
EBV Capsid Antigen IgM	Negative	(Negative -)	Parvo B19 IgG	Positive	(Negative -)
EBV Nuclear Antigen IgG	Positive	(Positive -)	Parvo B19 IgG abs	* 36.27 IU/mL	
Albumin Lvl	30 g/L	(35 - 52)	Parvo B19 IgM	Negative	(Negative -)
Bili Total	39.4 micromol/L	(- <=17.0)	Rubella IgM Ab	Negative	(Negative -)
Bili Direct	27.4 micromol/L	(- <=5.0)	SMA Screen	* Negative	
AST	236 IU/L	(- <=32)	Hep A IgM Ab	Negative	(Negative -)
ALT	194 IU/L	(- <=33)	Anti Tissue Transglutaminase IgA	* < 1.9 CU	(- <=19.9)
WBC	15.0 x10 ⁹ /L	(4.5 - 13.5)	DAT Interp	DAT Interp	
RBC	* 3.26 x10 ¹² /L	(3.80 - 5.00)	DAT Poly	Positive	
Hgb	74 g/L	(115 - 150)	IgG BB	4+	
Hct	0.24 L/L	(0.34 - 0.44)	IgM BB	0	
MCV	74.2 fL	(73.0 - 95.0)	IgA BB	* 1+	
MCH	22.7 pg	(26.0 - 32.0)	C3d	0	
MCHC	306 g/L	(320 - 360)	C3c	0	
Platelet	366 x10 ⁹ /L	(140 - 400)	Ctrl	0	
Ammonia Lvl	* 32.1 micromol/L	(15.0 - 51.0)			
Ceruloplasmin	0.45 g/L	(0.16 - 0.45)			
A-1-AT	2.05 g/L	(0.90 - 2.00)			
Amino Acid Quant	Amino Acid Quant				

2.3 MRI MRCP

The MRI MRCP report of the child revealed the following results:

‘Presence of hepatosplenomegaly was noted. There was a diffuse irregular biliary dilatation of thickened wall with periportal lymph nodes and T2W hyperintensity in keeping with the suspected clinical diagnosis of sclerosing cholangitis.

2.4 Liver Biopsy

The liver biopsy results of the child revealed the following analysis:

“This biopsy showed moderate portal inflammation with interface hepatitis noted in some of the portal tracts. No definite plasma cells are identified. Diffuse bile duct injury is noted. No periductal fibrosis is seen. No granuloma or lymphoid aggregates/follicles are seen.

The above features along with the MRCP/MRI findings are suggestive of overlap syndrome (AIH/PSC). The histological features are probably affected due to the steroid intake and treatment. Another possibility that cannot be completely excluded is autoimmune cholangitis.

Correlation with serology markers, radiology and laboratory results.”

2.5 Patient’s Progress

On the very next day of her admission to the ward, the child hemoglobin dropped to 70 g/L along with positive antibodies. As a suspected case of Autoimmune Hemolytic Anemia (Subtype variant: Warm AIHA) and primarily to avoid complications from taking place, the child was started on Prednisone right away. In the meantime, it was also excluded that there was no history of any other autoimmune disease present or diagnosed in this patient. This variant of Warm AIHA was of secondary type, because it occurred in relation to Autoimmune Hepatitis, which is another autoimmune condition that was coexisting in this patient.

However, her abnormal liver enzymes combined with her clinical presentation helped reveal the fact that she was suffering from a case of Autoimmune Hepatitis associated with Cholangitis. This diagnosis was confirmed under the observation of a Pediatric GI.

Therefore, she was continued on Prednisolone and remained admitted due to her ongoing fever. Currently, after some tapering and dose adjustments, she is now on Prednisolone 20 mg during the day and 15 mg at night.

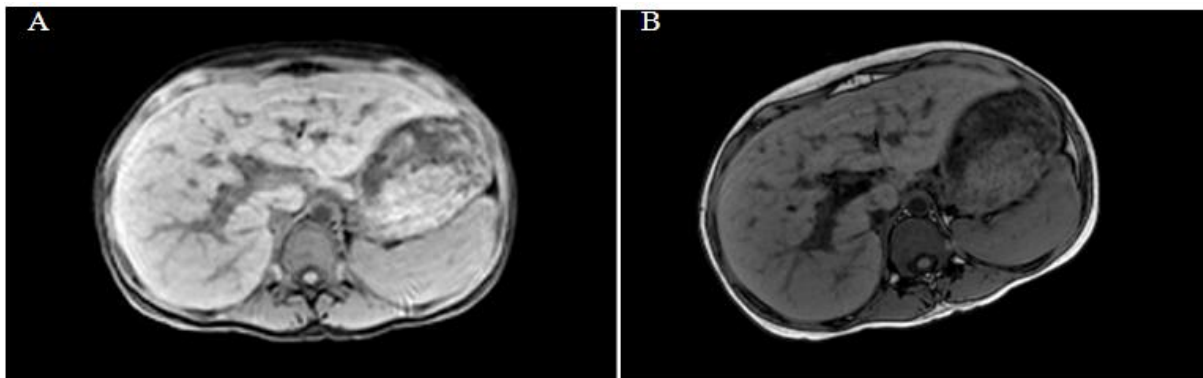


Fig. 1. MRI MRCP report

When the CBC was repeated, it revealed the following results:

Table 2. Post-treatment lab report

White Blood Cells	12.4 (Differentials were normal)
Hemoglobin	108
Hematocrit	0.34
Platelets	537,000
Direct Coombs’ Test	Positive

2.6 Management & Treatment Plan

After the Pediatric Gastroenterology confirmed that the patient was indeed suffering from Autoimmune Hepatitis associated with Warm Autoimmune Hemolytic Anemia, the matter revolved around suggesting an appropriate treatment plan for her.

The hepatology team were brought on board. Here, her LFTs were seen to worsen over time, her jaundice had now become well-manifested, and hemoglobin continued to drop down, attaining a level of 51 at the time. At this point, the patient was being maintained on Ursodiol and Azathioprine. Because of her worsening anemia, Prednisone was being continued without stopping. It was later stopped when she was discharged.

She was also started on IV Methylprednisolone 2 mg/kg/day along with 2 doses of IVIG. When she was discharged, she was prescribed Sirolimus 2 mg PO daily. As per the last update taken in April 2022, it was found that her response to Sirolimus was acceptable. Her hemoglobin levels were also satisfactory and the reticulocyte count had significantly dropped. Steroids were stopped and she was advised to continue taking Folic Acid 5 mg PO on a weekly basis for the time being.

3. DISCUSSION

Pediatric autoimmune diseases pose a great negative impact on the morbidity and mortality of the pediatric population around the world. Due to the lack of this target population describing their complaints properly in detail, it often becomes difficult to diagnose these diseases in children. There are currently an estimated 26 autoimmune diseases that present in the pediatric population across the different ages of their age group. All of these diseases are among the prevalent diseases that are seen in this age group [8].

Autoimmune Hepatitis is one such autoimmune disease that is found to occur in the pediatric population. It was commonly seen to occur in the female pediatric population. More frequently, it has been seen to occur as part of the 'Overlap Syndrome'.

The Overlap Syndrome is a name given to a condition where a patient presents with similar and 'overlapping' features of both Autoimmune Hepatitis and Primary Sclerosing Cholangitis, as

seen in this patient. The management of these types of cases is usually confusing, mainly because it becomes difficult to diagnose the actual condition amidst the confusing symptoms [9].

Autoimmune Hepatitis is a progressive form of autoimmune disease where there is a noticeable inflammation of the liver due to an unknown cause [10]. This form of hepatitis is thought to stem from a combination of genetic and environmental factors and so, the affected individual has to suffer from a myriad of symptoms in return. 60% of the patients are diagnosed without any obvious symptoms or causes.

Out of all the cases diagnosed, 80% belong to the Type I category, which is diagnosed on the basis of anti-smooth muscle antibodies (ASMA) with or without any antinuclear antibodies. (ANA) [11].

The most common symptoms that present in this condition are malaise, fatigue, jaundice, abdominal pain, and sometimes, arthralgias. The treatment options for Autoimmune Hepatitis keep evolving and changing as per the intensity and severity of the disease.

So far, the most widely accepted regimen is where the disease is stopped from progressing towards liver cirrhosis and other complicated and irreversible stages.

The given patient was also seen to be suffering from Autoimmune Hemolytic Anemia. This is a rare, hereditary condition in which a hemolysis or breakdown of the premature red blood cells (RBCs) occurs due to the immune system dysfunctioning against the body's red blood cell antigens [13].

It is estimated that for every 100,000 people, 1.77% are diagnosed with AIHA annually. Two-thirds of these cases belong to the category of Warm Autoimmune Hemolytic Anemia, which is undoubtedly the most common variant of the disease [12].

Autoimmune Hemolytic Anemia could either be primary or secondary depending on the presence or absence of an underlying illness. The diagnosis is largely based on the abnormalities that could be seen on the peripheral smear and the complete blood picture. Primary AIHA occurs when the underlying cause is unclear or

idiopathic whereas Secondary AIHA occurs when there is a presence of any disorder – ranging from infectious diseases, lymphoproliferative disorders, autoimmune conditions, or even a combination of either of these issues [13].

From the given case and its associations with Autoimmune Hepatitis, it is clear that this is a case of Secondary AIHA.

Just like with any other autoimmune disease, there is no treatment for it. Supportive blood transfusions are given to the patient to make sure that their hemoglobin levels remain within the optimal range. Hematopoietic stem cell transplantation is also recommended in some cases, but the cost of this is often too expensive for people to afford, so they usually prefer transfusions and other supportive treatment options [14].

4. CONCLUSION

In this case, the patient presented with confusing symptoms. A prompt diagnosis was made, and in accordance with that, further evaluation and management was carried out.

Autoimmune Hemolytic Anemia (AIHA) is a common condition in today's world. In this disease, there is hemolysis or the premature breakdown of red blood cells (RBCs) either due to the formation of autoantibodies or the activity of the immune system and its components in breaking down these red blood cells.

This patient was dealing with two coexisting conditions in a sequence of events that are labelled as the 'Overlap Syndrome'. Both the conditions presented with different symptoms and therefore, had to be dealt with accordingly.

The patient involved in this case was subjected to different laboratory analysis and examinations to find out her diagnosis and once this was done, it became easier for the doctors to treat and manage her condition accordingly.

Now, the patient has been discharged and is on maintenance treatment. All her symptoms have almost resolved except for AIHA, which is known to be a life-long condition and so, will be dealt with accordingly as well.

DISCLAIMER

The products used for this research are commonly and predominantly use products in our

area of research and country. There is absolutely no conflict of interest between the authors and producers of the products because we do not intend to use these products as an avenue for any litigation but for the advancement of knowledge. Also, the research was not funded by the producing company rather it was funded by personal efforts of the authors.

CONSENT

As per international standard or university standard, patients' written consent has been collected and preserved by the author(s).

ETHICAL APPROVAL

As per international standard or university standard written ethical approval has been collected and preserved by the author(s).

COMPETING INTERESTS

Authors have declared that no competing interests exist.

REFERENCES

1. Hill A, Hill QA. Autoimmune hemolytic anemia. Hematology. American Society of Hematology. Education Program. 2018;(1):382–389. Available: <https://doi.org/10.1182/asheducation-2018.1.382>
2. Michalak SS, Olewicz-Gawlik A, Rupa-Matysek J, Wolny-Rokicka E, Nowakowska E, Gil L. Autoimmune hemolytic anemia: current knowledge and perspectives. Immunity & Ageing. 2020; 17(1):1-16.
3. Fattizzo B, Zaninoni A, Nesa F, et al. Lessons from very severe, refractory, and fatal primary autoimmune hemolytic anemias. Am J Hematol. 2015;90(8):E149-E151.
4. Michalak SS, Olewicz-Gawlik A, Rupa-Matysek J, Wolny-Rokicka E, Nowakowska E, Gil L. Autoimmune hemolytic anemia: current knowledge and perspectives. Immunity & ageing: I & A, 2020;17(1):38. Available: <https://doi.org/10.1186/s12979-020-00208-7>
5. Boberg KM, Chapman RW, Hirschfield GM, Lohse AW, Manns MP, Schrupf E International Autoimmune Hepatitis Group. Overlap syndromes: the International

- Autoimmune Hepatitis Group (IAIHG) position statement on a controversial issue. *J Hepatol.* 2011;54:374–385
6. Kumar N, Poddar U, Yadav R, Lal H, Pani K, Yachha SK, Srivastava A, Pandey R. Autoimmune Sclerosing Cholangitis in Children: A Prospective Case-Control Study. *Pediatric gastroenterology, hepatology & nutrition.* 2021;24(2):154–163. Available: <https://doi.org/10.5223/pghn.2021.24.2.154>
 7. Gregorio GV, Portmann B, Karani J, Harrison P, Donaldson PT, Vergani D, et al. Autoimmune hepatitis/sclerosing cholangitis overlap syndrome in childhood: a 16-year prospective study. *Hepatology.* 2001;33:544–553.
 8. Lovell DJ, Huang B, Chen C, Angeles-Han ST, Simon TA, Brunner HI. Prevalence of autoimmune diseases and other associated conditions in children and young adults with juvenile idiopathic arthritis. *RMD open.* 2021;7(1):e001435. Available: <https://doi.org/10.1136/rmdopen-2020-001435>
 9. Bunchorntavakul C, Reddy KR. Diagnosis and management of overlap syndromes. *Clinics in Liver Disease.* 2015;19(1):81-97.
 10. Linzay CD, Sharma B, Pandit S. Autoimmune Hepatitis. [Updated 2021 Aug 27]. In: StatPearls [Internet]. Treasure Island (FL): StatPearls Publishing; 2022 Jan-. Available: <https://www.ncbi.nlm.nih.gov/books/NBK459186/>
 11. Doycheva I, Watt KD, Gulamhusein AF. Autoimmune hepatitis: Current and future therapeutic options. *Liver Int.* 2019;39(6):1002-1013.
 12. Hansen DL, Möller S, Andersen K, Gaist D, Frederiksen H. Increasing incidence and prevalence of acquired hemolytic Anemias in Denmark, 1980-2016. *Clin Epidemiol.* 2020;12:497–508. DOI: 10.2147/CLEP.S250250.
 13. Barcellini W, Zaninoni A, Giannotta JA, Fattizzo B. New Insights in Autoimmune Hemolytic Anemia: From Pathogenesis to Therapy. *Journal of Clinical Medicine.* 2020;9(12):3859.
 14. Hill Q.A, Hill A, Berentsen S. Defining autoimmune hemolytic anemia: a systematic review of the terminology used for diagnosis and treatment. *Blood Advances.* 2019;3(12):1897–1906. Available: <https://doi.org/10.1182/bloodadvances.2019000036>

© 2022 Shtawi et al.; This is an Open Access article distributed under the terms of the Creative Commons Attribution License (<http://creativecommons.org/licenses/by/4.0>), which permits unrestricted use, distribution, and reproduction in any medium, provided the original work is properly cited.

Peer-review history:
The peer review history for this paper can be accessed here:
<https://www.sdiarticle5.com/review-history/86960>