



## **International Journal of Medical and Pharmaceutical Case Reports**

**15(3): 15-18, 2022; Article no.IJMPCR.86220**  
**ISSN: 2394-109X, NLM ID: 101648033**

# **Unilateral Giant Bullous Emphysema; Vanishing Lung Syndrome**

**Bayrakçi Onur <sup>a\*</sup> and Akinci Gülay <sup>b</sup>**

<sup>a</sup> *Department of Thoracic Surgery, Ersin Arslan Training and Research Hospital, Turkey.*

<sup>b</sup> *Department of Anesthesiology and Reanimation, Ersin Arslan Training and Research Hospital, Turkey.*

### **Authors' contributions**

*This work was carried out in collaboration between both authors. Author BO designed the study and wrote the first draft of the manuscript. Author AG managed the literature searches. Both authors read and approved the final manuscript.*

### **Article Information**

DOI: 10.9734/IJMPCR/2022/v15i330158

### **Open Peer Review History:**

This journal follows the Advanced Open Peer Review policy. Identity of the Reviewers, Editor(s) and additional Reviewers, peer review comments, different versions of the manuscript, comments of the editors, etc are available here: <https://www.sdiarticle5.com/review-history/86220>

**Received 10 February 2022**

**Accepted 13 April 2022**

**Published 16 April 2022**

**Case Study**

## **ABSTRACT**

Bullous lung disease is an illness characterized by nonfunctional air-filled spaces caused by deterioration of alveolar tissue. Lung diseases such as chronic bronchitis, emphysema, and bronchiolitis are associated with smoking. We aimed to present a case of giant bullous emphysema without any known comorbidity and who was admitted to the clinic with progressive dyspnea in a short time. A 52-years-old male patient was admitted to the clinic with the complaint of increasing dyspnea in the last 3 months. Smoking was 26 pack years, and no chronic disease. Giant bullae with a size of 13x15x20 cm, starting from the right apical and extending posteriorly to the lower lobe fissure, and diffuse emphysematous pathologies were seen in the thorax CT. The patient was operated on for a giant bullous lesion that subtotally contains the upper lobe of the right lung and causes respiratory dysfunction with the compression effect on the middle lobe and lower lobe (resection of the giant bulla was operated by the right thoracotomy). Except for the operation-related pain complaint, no respiratory symptoms were seen. The patient said with an effort, respiratory distress decreased significantly. No complications were observed, and the patient was discharged on the 6th day of the operation. Vanishing Lung Syndrome is a complication of Chronic Obstructive Pulmonary Disease, and it is defined as idiopathic giant bullous emphysema. This illness defined as giant bulla occupying one-third of the hemithorax, it compresses the mediastinum and lung parenchyma. Differentiating bullous lesions of the lung from pneumothorax is important in the

\*Corresponding author: E-mail: [dronurbayrakci@gmail.com](mailto:dronurbayrakci@gmail.com);

treatment. Surgical treatment is a successful option in symptomatic giant bullae or with compression of lung parenchyma. Bullectomy improves the patient's symptoms, pulmonary function, quality of life, and expansion of the lung parenchyma.

**Keywords:** Bullous; emphysema; giant; lung; vanishing.

## 1. INTRODUCTION

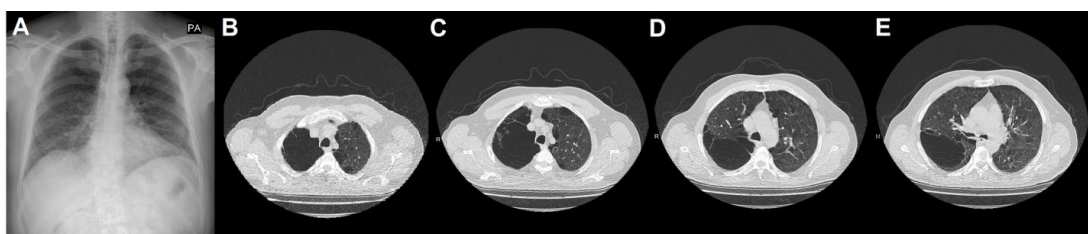
Bullous lung disease is an illness characterized by nonfunctional air-filled spaces caused by deterioration of alveolar tissue [1]. Lung diseases such as chronic bronchitis, emphysema, and bronchiolitis are associated with smoking. It was reported that smoking is responsible for the formation of bullae [2,3]. This disease is described as secondary to cocaine or cannabis use, emphysema, alpha-1 antitrypsin deficiency, Marfan syndrome, Ehlers-Danlos syndrome, and inhaled fiberglass exposure. Extensive paraseptal emphysema coalesces to form giant bullae, compressing the normal lung parenchyma [4,5]. We aimed to present a case of giant bullous emphysema without any known comorbidity and who was admitted to the clinic with progressive dyspnea in a short time.

## 2. PRESENTATION OF CASE

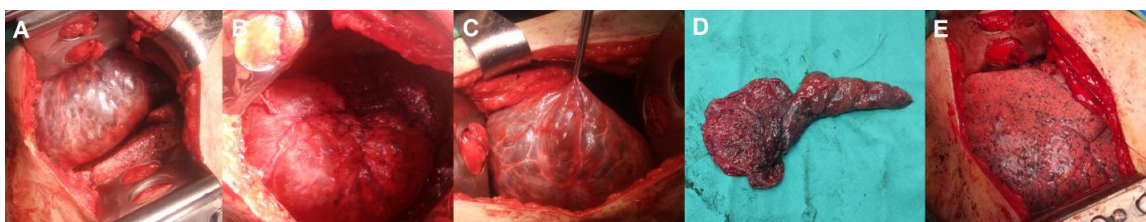
A 52-years-old male patient was admitted to the clinic with the complaint of increasing dyspnea in the last 3 months. Smoking was 26 pack years, and no chronic disease. Physical examination revealed intercostal retraction, wheezing, and rhonchi. Breath sounds were decreased in the

right apical region of the lung. Giant bullae with a size of 13x15x20 cm, starting from the right apical and extending posteriorly to the lower lobe fissure, and diffuse emphysematous pathologies were seen in the thorax CT (Computed Tomography). SpO<sub>2</sub> (oxygen saturation) was 89 (at rest in room air). The FEV<sub>1</sub> (The forced expiratory volume in 1 second) value was 2.32 (75%) and the FEV<sub>1</sub>/FVC (the forced vital capacity) 67% in the pulmonary function test. An operation was planned for a giant bullous lesion that subtotally contains the upper lobe of the right lung and causes respiratory dysfunction with the compression effect on the middle lobe and lower lobe (Fig. 1).

En bloc resection of the giant bulla was operated by the right thoracotomy (figure 2). The patient was mobilized on the first postoperative day. Air leakage through the thorax tube ended on the 3rd days. Except for the operation-related pain complaint, no respiratory symptoms were seen. The patient said that when walking and with effort, respiratory distress decreased significantly. SpO<sub>2</sub> value was measured as 93 (at rest in room air). No complications were observed, and the patient was discharged on the 6th day of the operation.



**Fig 1. A. Preoperative chest X-ray B,C,D,E. CT images of giant bullous emphysema**



**Fig. 2. A,B. Images of intraoperative exploration C. Image of giant bulla D. Resection specimen of bulla E. Image of fully expanded lung parenchyma after resection**

### 3. DISCUSSION

Vanishing Lung Syndrome (VLS) is a complication of Chronic Obstructive Pulmonary Disease (COPD), and it is defined as idiopathic giant bullous emphysema [6]. VLS is associated with many clinical findings such as progressive dyspnea, cough, decreased pulmonary capacity, and ruptured bullae causing secondary pneumothorax [7]. The patient, who was a smoker without a history of chronic disease, was admitted to the clinic with the complaint of increasing dyspnea in the study. Giant bullae on chest X-ray may be mimicking pneumothorax. The VLS defined as giant bulla occupying one-third of the hemithorax, it compresses the mediastinum and lung parenchyma. Subpleural bullae may also be seen with paraseptal emphysema or centrilobular emphysema. In our case, it was a giant bulla that completely occupied the right upper lobe, and compressed the middle and lower lobes. In case of clinical suspicion or confusion with pneumothorax, it should be evaluated with thorax computed tomography (CT). A true pneumothorax is identified by the radiological white line on the chest X-ray. It can be detailed bulla associated with the lobe, its size, compression of the mediastinum and lung parenchyma in the CT.

Enzymatic degradation of the alveolar wall from elastase produced by alveolar macrophages and neutrophils plays a crucial role in the pathogenesis of bulla formation. It results in poor gas exchange due to fibrosis in the alveolar membrane [8]. Giant bullae formed by this pathological change are seen as nonfunctional air-filled spaces. Therefore, it can be hypoxemia, hypercapnia and mismatch of ventilation-perfusion. The patient was seen hypoxemia and compression of pulmonary parenchyma in the study.

If a giant bullous emphysema patient is asymptomatic, who is more rational to follow up with bronchodilator treatment. However, patients with symptomatic or ruptured bulla require surgical treatment. Surgical treatments are bullectomy (with video-assisted thoracoscopic surgery or thoracotomy), endobronchial valve, endocavitary drainage and lung transplantation. Improvement in pulmonary function test values (FEV1 or FEV1/FVC) is seen in patients who underwent surgical treatment [9]. Surgical treatment is usually successful of bullous lung disease, and with this treatment will be prevented complications such as pneumothorax and

infection [10]. A significant improvement was observed in the values of the pulmonary function test and the patient's complaints in the study. Full expansion of the compressed lung parenchyma was seen after total bullectomy.

### 4. CONCLUSION

Differentiating bullous lesions of the lung from pneumothorax is important in the treatment. Surgical treatment is a successful option in symptomatic giant bullae or with compression of lung parenchyma. Bullectomy improves the patient's symptoms, pulmonary function, quality of life, and expansion of the lung parenchyma.

### CONSENT

As per international standard or university standard, patients' written consent has been collected and preserved by the author(s).

### ETHICAL APPROVAL

As per international standard or university standard written ethical approval has been collected and preserved by the author(s).

### COMPETING INTERESTS

Authors have declared that no competing interests exist.

### REFERENCES

1. Greenberg JA, Singhal S, Kaiser LR. Giant bullous lung disease: Evaluation, selection, techniques, and outcome. *Chest Surg Clin N Am* 2003;13:631-649.
2. Keller CA. Pathophysiology and classification of emphysema. *Chest Surg Clin N Am* 2003;13:589-613.
3. Johnson MK, Smith RP, Morrison D, et al. Large lung bullae in marijuana smokers. *Thorax* 2000;55:340-342.
4. Sharma N, Justaniah Al M, Kanne JP, et al. Vanishing lung syndrome (giant bullous emphysema): CT findings in 7 patients and a literature review. *J Thorac Imaging* 2009;24(3):227-30.
5. Mireles-Cabodevila E, Sahi H, Farver C, et al. A young patient with a minimal smoking history presents with bullous emphysema and recurrent pneumothorax. *Chest*. 2007; 132:338-43.
6. Yousaf NM, Chan NN, Janvier A. Vanishing Lung Syndrome: An Idiopathic

- Bullous Emphysema Mimicking Pneumothorax. Cureus 2020;12(8):e9596.
7. Gao X, Wang H, Gou K, et al. Vanishing lung syndrome in one family: five cases with a 20-year follow-up. Mol Med Rep. 2015;11:567-570.
  8. Im Y, Farooqi S, Mora AJ. Vanishing lung syndrome. Proc (Bayl Univ Med Cent). 2016;29:399-401.
  9. Palla A, Desideri M, Rossi G, et al. Elective surgery for giant bullous emphysema: a 5-year clinical and functional follow-up. Chest. 2005;128: 2043-2050.
  10. Lone YA, Dar AM, Sharma ML, et al. Outcome of the Surgical Treatment of Bullous Lung Disease: A Prospective Study. Tanaffos. 2012;11(2):27-33.

---

© 2022 Onur and Gülay; This is an Open Access article distributed under the terms of the Creative Commons Attribution License (<http://creativecommons.org/licenses/by/4.0>), which permits unrestricted use, distribution, and reproduction in any medium, provided the original work is properly cited.

*Peer-review history:*  
*The peer review history for this paper can be accessed here:*  
<https://www.sdiarticle5.com/review-history/86220>