



# Short Term Follow Up of Patients with Osteoporotic Vertebral Compression Fractures Treated with Percutaneous Vertebroplasty

**R. Balaraman<sup>1\*</sup>**

<sup>1</sup>Sree Balaji Medical College & Hospital, Chennai – 600044, India.

## **Author's contribution**

*The sole author designed, analysed, interpreted and prepared the manuscript.*

## **Article Information**

DOI: 10.9734/JPRI/2021/v33i42B32438

### Editor(s):

(1) R. Deveswaran, M.S.Ramaiah University of Applied Sciences, India.

### Reviewers:

(1) Melgar O. Matulac, Adventist Medical Center Manila, Philippines.

(2) Sourabh Ramesh Joshi, Rural Dental College, Pravara Institute of Medical Sciences University, India.

Complete Peer review History: <https://www.sdiarticle4.com/review-history/72113>

**Short Research Article**

**Received 22 June 2021**  
**Accepted 31 August 2021**  
**Published 01 September 2021**

## **ABSTRACT**

Vertebral compression fractures are the most common osteoporotic fractures, 30-50% of all women develop vertebral compression fractures. In this study the mean age of 64 years with youngest case of age of 55 years and oldest case. 55 % of patients included in the study are female. One case had systemic hypertension, one case had Parkinsonism, and one case had Coronary Artery Disease. A significant reduction in analgesic intake was revealed. The patients without any analgesics increased from 0.5% (n=2) pre operative to 85.7% (n=30) at the six months follow-up (P less than 0.0001). pain score of ODS for immediate, 1month, 2 month, 3<sup>rd</sup> month and 6 month and found that(patient active measure) pam is reduced after immediate to 1 month till 6 month(p<0.05), and after 3<sup>rd</sup> month to 6 month no difference in pam score was observed.

**Keywords:** Coronary heart diseases; vertebral compression fractures; analgesics; osteoporosis.

## **1. INTRODUCTION**

Osteoporosis is reported to highly predominant in India. Female are mostly affected and almost

60% of women population are reported to have this disorder. On average 45 lakhs Indian females above 60yrs of age have had a fractured spine compared to osteoporotic hip fractures

which accounts every year for around 2.5 lakhs cases [1-4]. By the age of 75 yrs about 25% of all women have had at least one vertebral compression fractures which increases to 50% at the age of 80 yrs [1,2].

A conventional treatment of compression fractures includes bed rest, life style modifications, analgesics, bracing and supplementary osteoporosis reversing interventions. Notwithstanding, with conventional treatment [alendronate, salmon calcitonin nasal spray, SERM, Teriparatide Ultimately vertebral compression fractures. The regular treatment of compression fractures includes life style modifications, analgesics, bracing and supplementary osteoporosis reversing interventions [4-6]. hence this study aims to evaluate and analyze the short term functional outcome of Vertebroplasty in the management of stable osteoporotic wedge compression fractures of both lumbar and thoracic vertebrae.

## 2. METHODOLOGY

### 2.1 Inclusion Criteria

Only patients with thoracic and lumbar vertebrae osteoporotic fracture where included.

- Painful vertebral compression fracture presenting within a month at our hospital treatment with intact posterior cortex, only those cases with intact posterior cortex where included in the study.
- Kyphosis less than 20 degree.
- Chronic painful Vertebral fracture with Non union.

### 2.2 Exclusion Criteria

Only patients with thoracic and lumbar vertebrae osteoporotic fracture where included.

- Painful vertebral compression fracture presenting within a month at our hospital treatment with intact posterior cortex, only those cases with intact posterior cortex where included in the study.
- Kyphosis less than 20 degree.
- Chronic painful Vertebral fracture with Non union.

### 2.3 Sample Size

A total of 20 patients were taken up in the study during the above mentioned period. The age of

the patient was in the range of 52 -80 years. There were 9 males and 11 females in this study. One patients had associated injuries which were managed and they did not influence the functional outcome.

Patients with thoracic and lumbar vertebrae osteoporotic fracture where included in the study. Patients were investigated with Chest X-Ray, ECG, CBC, RFT, Random Blood Sugar, and Blood grouping and typing, which were required to get anesthetic fitness for the procedure. Other investigations like Serum Calcium, LFT, ALP, Acid phosphatase, Urine Bence Jones Protein were done to evaluate the cause of fractures. After radiological examination procedure was performed by radiologists and the patient was prepared in the ward in the morning on the day of surgery.

A Radiolucent and image intensifier compatible operating table was used. An indwelling Foley's catheter was maintained during surgery. The patient was positioned prone; the area to be operated was visualized under C arm image intensifier. C arm was arranged such that Anteroposterior, lateral and oblique view could be taken if required during the procedure. Using marker pen, level of the fracture was marked under C- arm control. Area to be operated was painted using povidone iodine and draped After general anaesthesia, 20ml of lignocaine with adrenaline was infiltrated over the proposed site of operation. Under image intensifier we located the pedicle percutaneously, a small incision was made lateral and superior to the cutaneous pedicle location which allowed proper convergence through the tissues to the proposed pedicle entry point. Using Vertebroplasty Cook's needle of size 11 gauge 115cm entry point was made at 10' o clock position on the lateral border of pedicle and switched c-arm to the lateral view to verify trajectory of needle & position. Through transpedicular approach needle was placed into the body at the junction of posterior two-third & anterior one-third of vertebral body which was confirmed in the lateral view.

## 3. RESULTS

In our study we had mean age of 64 years with youngest case of age of 55 years and oldest case of age 80 years. 4 cases had associated comorbid conditions out of which one had Diabetes Mellitus, one case had systemic hypertension, one case had Parkinsonism, and one case had Coronary Artery Disease. For the evaluation of

the segmental kyphosis (in terms of vertebral height) and alignment, 20 patient's x-rays were radiologically assessed. Repeated measure analysis used to find statistical difference significance of pain score of ODS for immediate, 1 month, 2 month, 3<sup>rd</sup> month and 6 month and found that pam 1s reduced after immediate to 1

month till 6 month ( $p < 0.05$ ), and after 3<sup>rd</sup> month to 6 month no difference in m pam score. We don't have much improvement in the Beck index. Whereas Balloon Kyphoplasty has shown the ability to restore and increase in vertebral body height and Becks which improves the alignment.

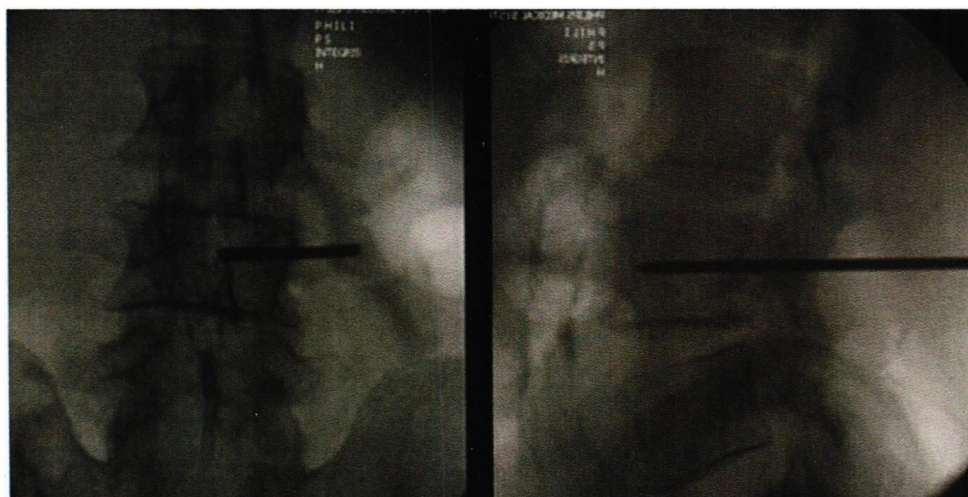


Fig. 1. C-Arm image showing the trajectory of needle & position in antero posterior and lateral view

Table 1. Sex distribution

	Frequency	Percent	Valid percent	Cumulative percent
F	11	55.0	55.0	55.0
!Valid M	9	45.0	45.0	100.0
Total	20	100.0	100.0	

Table 2. Vertebral level

Vertebral levels	Frequency	Percent	Valid percent	Cumulative percent
D11	2	10.0	10.0	10.0
D12	9	45.0	45.0	55.0
L1	3	15.0	15.0	70.0
Valid L2	4	20.0	20.0	90.0
L3	1	5.0	5.0	95.0
L4	1	5.0	5.0	100.0
Total	20	100.0	100.0	

Table 3. Comorbids

Comorbids	Frequency	Percent	Valid percent	Cumulative percent
-	16	80.0	80.0	80.0
CAD	1	5.0	5.0	85.0
DM	1	5.0	5.0	90.0
Valid HT	1	5.0	5.0	95.0
PARK	1	5.0	0	100.0
Total	20	100.0	100.0	

**Table 4. Denis compression fracture****CLASSIFICATION**

<b>FRACTURE TYPE</b>	<b>CASES NO.</b>
TYPE A	0
TYPE B	10
TYPE C	0
TYPED	10
TOTAL	0

**Table 5. Osteoporotic vertebral Wedge compression fractures - GENANT'S CLASSIFICATION**

<b>SHAPE</b>	<b>CASE NO</b>	<b>PERCENT AGE</b>
WEDGE	9	45%
BICONCAVE	11	55%
CRUSH	0	0
TOTAL	20	100%

**4. DISCUSSION**

McGraw and colleagues studied results from 135 venographies in 96 vertebroplasties provided useful information for PMMA flow characteristics. The study by Gilula et al said that the contrast material may interfere with visualization of the cement [5]. Author prefers venography for a very severe lesions E.g. A-V malformation, hypervascular metastasis. A significant reduction in analgesic intake was revealed [7,8]. The patients without any analgesics increased from 0.5% (n=2) pre operative to 85.7% (n=30) at the six months follow-up (P less than 0.0001). Repeated measure analysis used to find statistical difference significance of pain score of ODS for immediate, 1 month, 2 month, 3<sup>rd</sup> month and 6 month and found that pam is reduced after immediate to 1 month till 6 month ( $p < 0.05$ ), and after 3<sup>rd</sup> month to 6 month no difference in pam score. Advantage of veretebroplasty are fast, reliable and effective pain reduction which was assessed by visual analog score scores, This statistics comparing preop VAS score versus VAS score at immediate, one month, three months, six months from which we interpreted that p value  $< 0.05$  in all postoperative period, so it was a significant comparison. Statistically, we got significant pain relief in immediate post operative period which was maintained at the end of 6 months also.

**5. CONCLUSION**

In future surgeons will have a number of othersafer options like sky expander, vesselpasty depending upon the indication for treatment of

vertebral compression fractures by minimally invasive technique. This study suggests vertebroplasty in osteoporotic wedge compression fracture is one of the better treatment option available.

**DISCLAIMER**

The products used for this research are commonly and predominantly use products in our area of research and country. There is absolutely no conflict of interest between the authors and producers of the products because we do not intend to use these products as an avenue for any litigation but for the advancement of knowledge. Also, the research was not funded by the producing company rather it was funded by personal efforts of the authors.

**CONSENT AND ETHICAL APPROVAL**

As per international standard or university standard guideline Patient's consent and ethical approval has been collected and preserved by the authors.

**COMPETING INTERESTS**

Author has declared that no competing interests exist.

**REFERENCES**

- Gill GG, Manning JG, White HL. Surgical treatment of spondylolisthesis without spine fusion: Excision of the loose lamina with decompression of the nerve

- roots. J Bone Joint Surg Am. 1955;37:493-520.
2. Grobler LJ, Wiltse LL. Classification, non-operative, and operative treatment of spondylolisthesis, in Frymoyer JW (ed): The Adult Spine: Principles and Practice. New York, Raven Press. 1991;2:1655-1704
  3. Harvell JC Jr, Hanley EN Jr. Spondylolysis and spondylolisthesis, in Pang D (ed): Disorders of the Pediatric Spine. New York- Raven Press. 1995;561-574.
  4. Farfan HF, Osteria V, Lamy C. The mechanical etiology of spondylolysis and spondylolisthesis. Clin Orthop. 1976;117: 40-55.
  5. Fredrickson BE, Baker D, Mc Holick WJ, et al. The natural history of spondylolysis and spondylolisthesis. J Bone Joint Sur Am. 1984;66:699-707.
  6. Suk SI, Lee CK, Kang HS, et al. Vertebral fracture in osteoporosis. J Korean Orthop Assoc. 1993;28:980–987.
  7. Jensen ME, Evans AJ, Mathis JM, Kallmes DF, Cloft HJ, Dion JE. Percutaneous polymethylmethacrylate vertebroplasty in the treatment of osteoporotic vertebral body compression fractures: technical aspects. AJNR Am J Neuroradiol. 1997;18: 1897–1904.
  8. Grados F, Depriester C, Cayrolle G, Hardy N, Deramond H, Fardellone P. Long-term observations of vertebral osteoporotic fractures treated by percutaneous vertebroplasty. Rheumatology (Oxford). 2000;39:1410–1411.

© 2021 Balaraman; This is an Open Access article distributed under the terms of the Creative Commons Attribution License (<http://creativecommons.org/licenses/by/4.0>), which permits unrestricted use, distribution, and reproduction in any medium, provided the original work is properly cited.

*Peer-review history:*

*The peer review history for this paper can be accessed here:  
<https://www.sdiarticle4.com/review-history/72113>*