



Hyaluronic Acid Enriched Fat Graft versus Cartilage Perichondrium for Repair of Medium Size Tympanic Membrane Perforations

Doaa Hassan El-Far ^{a*}, Mahmoud Fawzy Mandour ^a,
Mahmoud Abd El-Aziz ^a and Mohamed Nasser El-Sheikh ^a

^a Department of Otorhinolaryngology, Faculty of Medicine, Tanta University, Tanta, Egypt.

Authors' contributions

This work was carried out in collaboration among all authors. All authors read and approved the final manuscript.

Article Information

DOI: 10.9734/JAMMR/2022/v34i244916

Open Peer Review History:

This journal follows the Advanced Open Peer Review policy. Identity of the Reviewers, Editor(s) and additional Reviewers, peer review comments, different versions of the manuscript, comments of the editors, etc are available here: <https://www.sdiarticle5.com/review-history/95169>

Original Research Article

Received: 19/10/2022

Accepted: 23/12/2022

Published: 27/12/2022

ABSTRACT

Background: Hyaluronic acid (HA) enriched fat graft myringoplasty (FGM) has many advantages compared with conventional MP using temporalis fascia and cartilage perichondrium, as it is short, easy, economical, and with minimum invasion and initiate a more rapid and complete healing process. This study aimed to evaluate the effectiveness of fat plug MP, enriched with HA for closure of medium size tympanic membrane perforations (TMP) (25-50% of TM surface area) and to compare it with classical cartilage perichondrium MP.

Methods: This prospective randomized control study was conducted on 50 cases with TMP. Cases were allocated into 2 groups: group I: tympanoplasty was done using fat graft enriched with HA. In group I hyaluronic was applied as gel foam soaked with commercially available HA and group II: tympanoplasty was done using cartilage perichondrium. All cases were subjected to ENT

*Corresponding author;

examination and pre-operative audiological evaluation including pure tone audiometry (PTA) and tympanometry.

Results: Graft taking was statistically insignificant after 3 months compared to 1 month follow ups in both groups. Air bone gap (ABG) was insignificantly different in the pre and postoperative ABG in both groups. Hearing was significantly improved postoperatively compared to preoperatively in both groups (P value<0.001). There was no significant difference in distribution of side of perforation in both groups. Hearing gain was statistically insignificant between both groups (P value=0.256). Hearing was significantly improved postoperatively compared to preoperatively in both groups (P value <0.001).

Conclusion: In cases with TMP, the TM HA enriched Fat graft myringoplasty (FGM) is an effective procedure with minimal invasion in management of the medium sized TMP. Also, it is safe and feasible procedure. Hearing was significantly improved postoperatively compared to preoperatively in both groups: HA enriched FGM group and MP with cartilage perichondrium group respectively.

Keywords: Hyaluronic acid enriched fat graft; cartilage perichondrium; medium size tympanic membrane perforations.

1. INTRODUCTION

Perforations of the tympanic membrane (TMP) are often caused by infectious and traumatic agents. Perforations originate from middle ear infections, and in the majority of instances, trauma heals spontaneously. However, if there are recurrent infections or if the illness persists, the likelihood of spontaneous healing of these perforations is diminished. Even if they are tiny, TMPs that have persisted for a long time might induce conductive loss of hearing and middle ear infection. Closure of chronic dry TMPs is intended to restore the tympanic membrane's (TM) integrity in order to improve hearing and reduce the occurrence of acute otitis media [1].

Myringoplasty (MP) is the technique for closing holes of the TM's pars tensa. Repairing the TMP without raising the annulus and accessing the middle ear is a standard otolaryngology treatment. This method employs an autologous fat graft, a paper patch, an absorbable gelatin patch, and hyaluronic acid (HA) ester films [2].

Fat Plug Myringoplasty (FGM) offers numerous advantages over temporalis fascia-based MP since it is brief, straightforward, economical, and with minimum invasion. A microscopic examination of fat from the ear lobule revealed that the fat cells are more compact and include more fibrous tissue than total Gross. By bridging the gap, it provides scaffold for the formation of TM epithelium and mucus membrane [1].

HA enriched fat plug that initiates a more rapid and complete healing process, and its efficacy when used during MP has been studied.

The goal of this research is to assess the effectiveness of FPM, enriched with HA for closure of medium size TM perforations (25-50% of TM surface) and to compare it with classical cartilage perichondrium MP.

2. METEERIALS AND METHODS

This randomized prospective control study was done on 50 cases with tympanic membrane perforation (TMP).

The inclusion criteria were patients older than 11 years old and younger than 70years old. TMP medium in size according to Saliba's TMP classification reported in 2008 (25-50% of TM surface area) [2]. The perforations lasted at least six months. No signs of current chronic otitis media, cholesteatoma, or pocket retraction development. There were no ossicular abnormalities suspected upon microscopic inspection. Hearing in the other ear is intact. The exclusion criteria were patients with marginal perforation. Patients with retraction pocket or squamosal chronic otitis media. Patients with recurrent ear discharge independent of respiratory upper tract infection. Patients with recurrent TMP. Patients with associated comorbidity (diabetic, hepatic, renal, malnutrition, smoking)

2.1 Intervention

Cases were randomly divided in 2 groups, (Group I and II) with 25 cases in each group. Group I: MP was done using fat graft enriched with HA. In group I hyaluronic was applied as gel foam soaked with commercially available HA. Group (II): tympanoplasty was done using cartilage perichondrium.

All cases were subjected to routine ENT examination and pre-operative audiological examination with pure tone audiometry (PTA) and tympanometry. Procedure was done under general anesthesia. Microscope has been used to make type I tympanoplasty "myringoplasty" in all cases. In the first group (group I). HA enriched fat was used as graft material while tragal cartilage perichondrium in (group II).

2.2 Surgical Technique

Group I (HA enriched Fat Graft Myringoplasty (FGM)): General anesthesia was used in all cases. All cases were done using Microscope through per-meatal approach.

Surgical Steps: The ear was draped in a sterile technique. Local injection of 1% xylocaine with 1/100,000 adrenaline at cartilaginous bony junction of ear canal at 3,6,9,12 O'clock, and the ear lobule. Under microscopic view using proper ear speculum, Refreshment of the margins of the perforation using straight sharp needle and cup forceps to de-epithelialize the edge of perforation. Graft Harvesting (fat of ear lobule): A tiny cut was made along the posterior aspect of the ear lobule, and the fat was removed with sharp dissecting shears, taking care not to puncture the anterior skin. For medium perforations, fat was taken from the ear lobule or by a 5-mm cut below the mastoid tip and below the sternocleidomastoid muscle for at least twice the size of the perforation. The fat plug was then inserted through the hole into the middle ear and partially retracted back through the perforation to guarantee eversion of the perforation edge. The fat plug is positioned such that it covers the depth of the middle ear with a tiny portion lateral to the TM. On the surface of the fat graft, HA gel (commercially available) was applied, followed by HA-soaked gel foam in the external auditory canal.

Steps of applying HA gel: Dropping HA gel on the fat graft, Applying gel foam, dropped HA gel again, packing of the external auditory canal by gel foam and finally, an ear dressing was applied.

Group II (cartilage perichondrium MP): General anesthesia was used in all cases. All cases were done using Microscope through per-meatal approach.

Surgical Steps: Ear was prepared, and perforation was refreshed as in the first group. Graft harvesting: On the posterior portion of the

tragus, a tiny cut was made, and the cartilage and perichondrium were revealed. A cartilage fragment with perichondrium on both faces was removed. The transplant was subsequently treated by carefully removing the layer of perichondrium covering the cartilage on the convex side, so exposing the cartilage on this side. The perichondrium of the cartilage's concave surface was preserved. A sharp blade was used to thin the cartilage. The graft was allowed to dry, and tragus skin is closed with sutures. The posterior canal wall was incised from six to twelve o'clock, approximately one centimetre from the annulus. The tympan meatal flap was then lifted and reflected anteriorly. The graft was then positioned via the underlay approach, with the perichondrium facing laterally. A gel foam disc stabilised the location of the graft above the promontory. Under the microscope, the repositioning of the tympanic meatal flap and the excellent adhesion of the graft with the TM are evaluated. Gel foam was placed inside the external auditory canal. All 50 cases were hospitalized for 24 hours then were discharged with routine precautions of antibiotics, analgesics, and nasal decongestants. Dressing was removed after 1 week and evaluation of the graft after 4 weeks.

2.3 Outcome Measure

Primary outcome: all cases were followed for 3 months. Graft uptake was evaluated at 4 and 12 weeks post-operatively. Secondary outcomes were audiological assessment using PTA was performed after 12 weeks. Dropped cases during follow-up period were treated statistically through intention to treat analysis.

2.4 Statistical Analysis

SPSS v26 was used to do statistical analysis (IBM Inc., Chicago, IL, USA). Comparing the two groups using an unpaired Student's t- test, quantitative data were provided as mean and standard deviation (SD). When applicable, qualitative variables were given as frequency and percentage (%) and analysed with the Chi-square test or Fisher's exact test. A two-tailed P value less than or equal to 0.05 was deemed statistically significant.

3. RESULTS AND DISCUSSION

Perforations of the tympanic membrane (TMP) are often caused by infection or trauma. In the majority of instances, perforations result in middle ear infections, and damage heals

naturally. However, if there are recurrent infections or if the illness persists, the likelihood of spontaneous healing of these perforations is diminished (Tables 1-6). Even if they are tiny, TMPs that have persisted for a long time might

induce conductive loss of hearing and otitis media. Closure of chronic dry TMP aims to restore the TM's integrity in order to improve hearing and reduce the prevalence of otitis media [3].

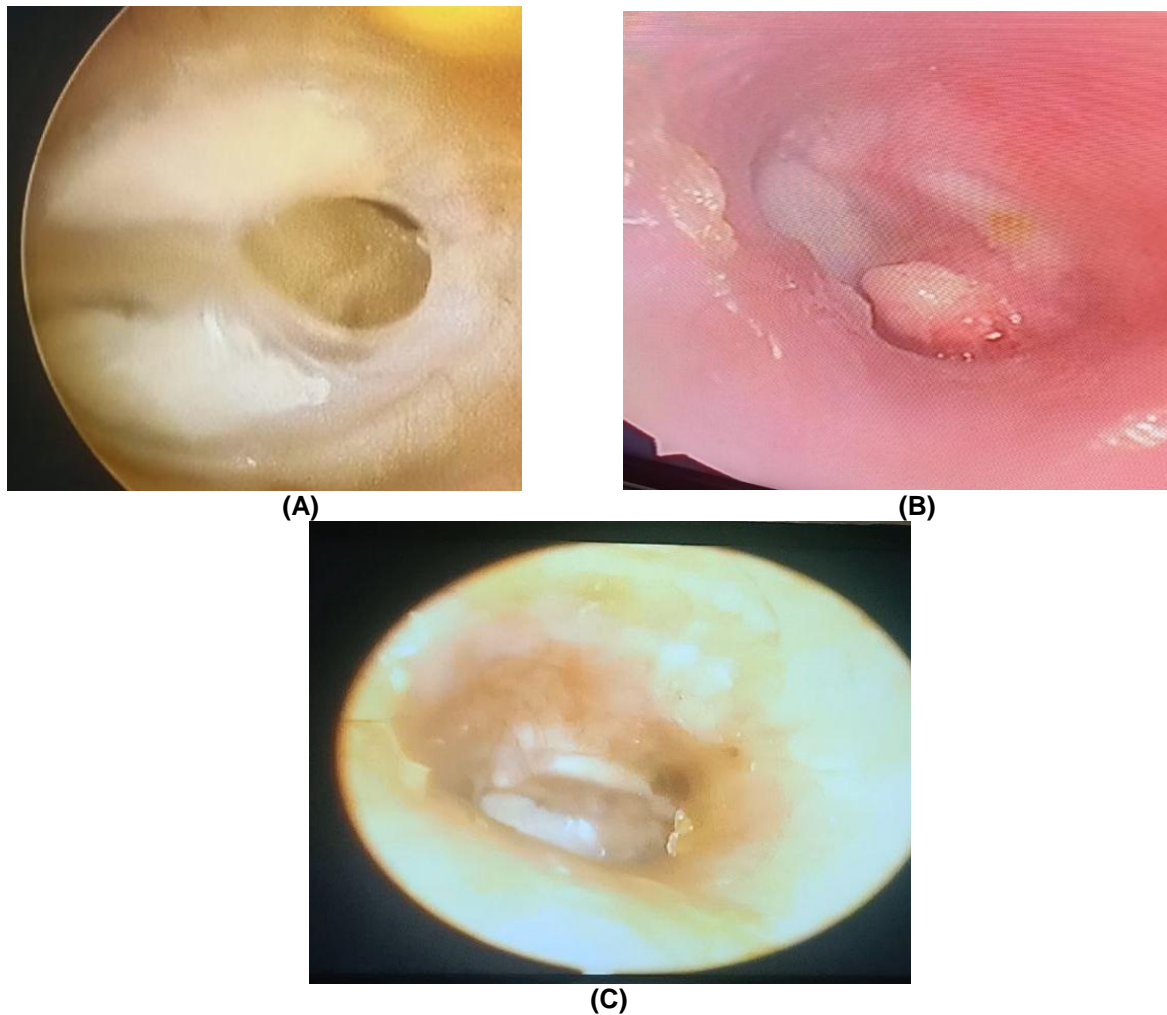


Fig. 1. (A) Endoscopic view of left ear dry central perforation, (B) Post-operative hyaluronic acid enriched fat graft myringoplasty group I after 1 month and (C) Post-operative hyaluronic acid enriched fat graft myringoplasty group I after 3 months

Table 1. Demographics of the studied groups

		Group I (n=23)	Group II (n=22)
Age (years)	Mean ± SD	40 ± 11.4	35.5 ± 16.1
	Range	15 - 65	12 - 63
T. test		1.085	
P value		0.284	
Sex	Male	7 (30.43%)	4 (18.18%)
	Female	16 (69.57%)	18 (81.82%)
Chi-square χ^2		0.914	
	P value	0.491	

χ^2 : Chi-square test; Regarding distribution of side of perforation, there was statistically insignificant between both groups (P value= 0.457)

Table 2. Distribution of side of perforation in both group

		Group I (n=23)	Group II (n=22)
Right side		6 (26.09%)	8 (36.36%)
Left side		17 (73.91%)	14 (63.64%)
Chi-square	X²	0.554	
	P Value	0.457	

X²: Chi-square test; Regarding Graft taking, there was statistically insignificant between both groups 1 month postoperatively (P value= 0.399). while there was statistically insignificant between both groups 3 months postoperatively (P value= 0.665)

Table 3. Graft taking of both groups 1 and 3 months postoperative

1 month postoperatively		Group I (n=23)	Group II (n=22)
Taken		14 (60.87%)	16 (72.73%)
Residual perforation		9 (39.13%)	6 (27.27%)
Chi-square	X²	0.712	
	P value	0.399	
3 months postoperatively			
Taken		19 (82.61%)	20 (90.91%)
Failed		4 (17.39%)	2 (9.09%)
Chi-square	X²	0.413	
	P value	0.399	

X²: Chi-square test; Graft taking was statistically insignificant after 3 months compared to 1 month follow ups in both groups (P values= 0.189, 0.241 respectively)

Table 4. Graft taking of both groups 1 month and 3 months postoperative

		Group I (n=23)	Group II (n=22)
1 month	Taken	14 (60.87%)	16 (72.73%)
	Residual perforation	9 (39.13%)	6 (27.27%)
3 months	Taken	19 (82.61%)	20 (90.91%)
	Failed	4 (17.39%)	2 (9.09%)
Chi-square	X²	2.681	2.444
	P value	0.189	0.241

X²: Chi-square test; Regarding ABG, Pre and postoperative ABG was statistically insignificant between both groups

Table 5. ABG of the studied groups pre and postoperatively

Preoperative ABG	Group I (n=23)	Group II (n=22)
Mean ± SD	21.91 ± 4.62	24.86 ± 5.46
Range	13 – 31	15-34
T. test	1.959	
P value	0.057	
Postoperative ABG		
Mean ± SD	9.7 ± 4.17	11.77 ± 3.85
Range	4 – 17	5 -18
T. test	1.733	
P value	0.090	

Regarding hearing gain, there was statistically insignificant between both groups (P value= 0.256)

Myringoplasty (MP) is the technique for closing holes of the TM's pars tensa. The first effort at MP was documented in 1640 by Marcus Banzer and others. Berthold conducted the first surgical closure of TMP using an autograft (free skin graft

of full thickness) in 1878 and coined the name "Myringoplasty" [4].

Although Tympanoplasty is the optimum therapy, easy and economical techniques such as

Table 6. Hearing gain in the studied groups

	Group I (n=23)	Group II (n=22)
Preoperative ABG (dB)	21.91 ± 4.62	24.86 ± 5.46
Postoperative ABG (dB)	9.82 ± 4.23	11.77 ± 3.85
T. test	9.411	9.185
P value	<0.001*	<0.001*
Hearing gain (dB)	12.22 ± 2.09	13.09 ± 2.94
T. test	1.153	
P value	0.256	

*: significant as p value < 0.05

chemical cauterization and FPM have been proven to be helpful in mending minor central holes, resulting in a considerable improvement in hearing. Ringenberg et al. [5] initially described FPM for minor holes in 1962, with an 87% success rates. Since then, studies [6,7] have demonstrated success rates ranging from 76% to 92% for minor perforations.

Deddens et al. [8] regard the size of the tympanic membrane (TM) hole to be an essential component in attaining effective healing. 5–30% of the drum surface is perforated in his series, which would be a favourable prognostic factor for a FGM, but greater perforations are less effective with fat graft alone.

In 2008, Saliba et al. He found a success rates of up to 91% and concluded that HA FGM is appropriate for perforations of all diameters in all quadrants if the margin can be completely seen.

Konstantinidis et al. [9] conducted research on eighty-two individuals with TMP of varying sizes. They reported success rates of 60% for TMP between 41% and 50%, whereas we achieved an 82.61% success rate for holes of medium size (25-50%). Success rates were 100% for holes measuring 0% to 10% of TM, 94.45% for perforations from 11% to 20%, and 93.75 percent for perforations measuring 21% to 30%.

KIM et al. [10] evaluated the effectiveness of FGM in treating holes of various sizes and locations. In the majority of instances, the hole size was less than 20% of the total TM. Most perforations (15 instances) occurred in the anteroinferior quadrant, whereas 26 holes affected the anterior portion of the TM. The overall hole closure rates following FGM was reported to be 87% (40 instances), with no statistically significant difference between the four size groups (10%, 10–20%, 20–30%, and >30%) (p = 0.192).

In accordance with our findings, Saliba et al. [11] examined 92 children with TMPs who had had either HA FGM (n = 50) or FGM (n = 42) surgery. They found that neither age nor the location of the TMP had a statistically significant effect on the success rates of either group (P value = 0.590 and 0.060, respectively). In addition, they observed that ABG improved considerably after HA. HA-FGM, in contrast to FGM without HA, which did not result in a statistically significant improvement in hearing. (10.75 dB for HA-FGM and 4.75 dB for FGM, respectively).

Similarly, Fouad et al. [12] reported in their study that the mean preoperative ABG for the PRP-FGM, HA-FGM, and FGM groups were 20,1 3.5 decibels, 20,7 3.8 decibels, and 20,8 3.6 decibels, respectively. The average postoperative ABG was 16.3 2.7 dB, 7.1 3.9 dB, and 18.4 3.2 dB, respectively. In HA-FGM group, air bone gap improved by about 13 dB that was judged to be statically significant (P value=0.003).

Saliba et al. [13] indicate that fat graft loses half of its bulging in the second postoperative month and 45% of the remainder in the 4th postoperative month. At six months postoperatively, a modest fat graft stain was seen in the TM thickness.

M. Mozaffari et al. [14] noted that the fibrous layer plays a crucial role in preserving the TM's functional qualities. Failure of this layer to migrate results in a two-layered neo-membrane, a membrane devoid of mechanical qualities that is susceptible to more damage. It has been proven that HA modulates the orientation of fibroblast and collagen fibres, hence reducing scarring. Since collagen plays a crucial role in sound transmission, enhancement of this intermediate layer healing boosted mechanical qualities of the TM, including vibration and sound conduction. As the wound border of the TM is suspended in air with no underlying tissue matrix to support the regenerating epithelium and

migrating arteries, it is probable that exogenous HA will give this additional ECM support.

PL Santa Maria et al. [15] noted that mitotic activity is greatest at the wound edge during cutaneous wound healing. On the other hand, there is a lack of a proliferative basal cell layer along the wound boundaries of the TM, although proliferation occurs at distant vascular regeneration sites in the annulus and handle of malleus. Immunohistochemistry analysis, however, revealed substantial quantities of HA at both the perforation edges and these regeneration foci.

Recent microarray gene research identified multiple genes involved in the transcriptional response to TM injury at certain time periods in rats. Expression of HAS 2, the primary enzyme involved in HA synthesis during stress-induced circumstances and wound healing, was 53-fold increased 12 hours after perforation, suggesting a substantial involvement in TM wound repair. HA's hygroscopic characteristic aids the transport of nutrients and ions during inflammation [16], in addition to preserving the extracellular space and tissue hydration.

All of the aforementioned research has assessed the efficacy of HA and FGM in the primary healing of TMP. Fiorino et al. [17] have assessed the effectiveness of FGM in mending residual or recurring TMP.

According to a retrospective research, 31 cases, aged 25 to 57 (mean 43,3) years, had revision MP with fat graft. 26 individuals had FGM under local anaesthesia using ear lobe fat and 5 cases with belly fat. In 87.1% of cases, the TM hole was successfully closed. Post-operative air conduction threshold and ABG improved in their research, although the change was not statistically significant.

4. CONCLUSIONS

The TM HA-enriched FGM is an efficient treatment with least invasion for the management of medium-sized TMP. Also, the process is safe and practical. In both the HA-enriched FGM group and the MP with cartilage perichondrium group, postoperative hearing was dramatically enhanced relative to preoperative hearing.

5. RECOMMENDATIONS

To verify our results, we suggest a future study with a large number of cases, multicenter

cooperation, and a longer follow-up period. I suggested that HA-FGM is appropriate for holes of all sizes in all quadrants if the margin can be completely visualised. We can do HAFGM under general anaesthesia, and it has a higher success rate than FGM alone or HA alone. We are confident that the prevalence of HA FGM will grow in the next years. The refinement of HA Fat Graft application technique may drive otosurgeons to apply this material to perforations bigger than those currently treated.

CONSENT AND ETHICAL APPROVAL

Written informed permission was acquired from the parents or legal caregivers of the cases. This study was done on Tertiary Healthy Care Center, Tanta University Hospital. The Ethics Committee at Tanta University's Faculty of Medicine authorised the research.

COMPETING INTERESTS

Authors have declared that no competing interests exist.

REFERENCES

1. Debnath M, Khanna S. A comparative study of closure of tympanic membrane perforation between chemical cauterization and fat plug myringoplasty. *Int J Otolaryngol Head Neck Surg.* 2013;2:248-52.
2. Saliba I, Abela A, Arcand P. Tympanic membrane perforation: Size, site and hearing evaluation. *Int J Pediatr Otorhinolaryngol.* 2011;75:527-31.
3. Villar-Fernandez MA, Lopez-Escamez JA. Outlook for tissue engineering of the tympanic membrane. *Audiol Res.* 2015;5:117.
4. Chalis hazar U. Fat plug myringoplasty. *Indian J Otolaryngol Head Neck Surg.* 2005;57:43-4.
5. Ringenberg JC. Fat graft tympanoplasty. *Laryngoscope.* 1962;72:188-92.
6. Mitchell RB, Pereira KD, Lazar RH. Fat graft myringoplasty in children--A safe and successful day-stay procedure. *J Laryngol Otol.* 1997;111:106-8.
7. Terry RM, Bellini MJ, Clayton MI, Gandhi AG. Fat graft myringoplasty--A prospective trial. *Clin Otolaryngol Allied Sci.* 1988;13:227-9.
8. Deddens AE, Muntz HR, Lusk RP. Adipose myringoplasty in children. *Laryngoscope.* 1993;103:216-9.

9. Konstantinidis I, Malliari H, Tsakiropoulou E, Constantinidis J. Fat myringoplasty outcome analysis with otoendoscopy: Who is the suitable patient? *Otol Neurotol.* 2013;34:95-9.
10. Kim DK, Park SN, Yeo SW, Kim EH, Kim JE, Kim BY, et al. Clinical efficacy of fat-graft myringoplasty for perforations of different sizes and locations. *Acta Otolaryngol.* 2011;131:22-6.
11. Saliba I, Knapik M, Froehlich P, Abela A. Advantages of hyaluronic acid fat graft myringoplasty over fat graft myringoplasty. *Archives of Otolaryngology–Head & Neck Surgery.* 2012;138:950-5.
12. Fouad YA, Abdelhady M, El-Anwar M, Merwad E. Topical platelet rich plasma versus hyaluronic acid during fat graft myringoplasty. *Am J Otolaryngol.* 2018;39:741-5.
13. Saliba I. Hyaluronic acid fat graft myringoplasty: How we do it. *Clin Otolaryngol.* 2008;33:610-4.
14. Mozaffari M, Jiang D, Tucker AS. Developmental aspects of the tympanic membrane: Shedding light on function and disease. *Genesis (New York, NY : 2000).* 2020;58:e23348-e.
15. Santa Maria PL, Redmond SL, Atlas MD, Ghassemifar R. Histology of the healing tympanic membrane following perforation in rats. *Laryngoscope.* 2010;120:2061-70.
16. Teh BM, Shen Y, Friedland PL, Atlas MD, Marano RJ. A review on the use of hyaluronic acid in tympanic membrane wound healing. *Expert opinion on biological therapy.* 2012;12:23-36.
17. Fiorino F, Barbieri F. Fat graft myringoplasty after unsuccessful tympanic membrane repair. *Eur Arch Otorhinolaryngol.* 2007;264:1125-8.

© 2022 El-Far et al.; This is an Open Access article distributed under the terms of the Creative Commons Attribution License (<http://creativecommons.org/licenses/by/4.0>), which permits unrestricted use, distribution, and reproduction in any medium, provided the original work is properly cited.

Peer-review history:

*The peer review history for this paper can be accessed here:
<https://www.sdiarticle5.com/review-history/95169>*