



Into the Unknown-exploring a Rare *BRAF* K601E Mutation in a Rectal Adenocarcinoma

**Nupur Karnik^{1*}, Mandar Ankolkar¹, Prachi Gogte¹, Mukta Ramadwar²,
Vikas Ostwal³ and Omshee Shetty¹**

¹Division of Molecular Pathology, Tata Memorial Hospital, Homi Bhabha National Institute, Mumbai, India.

²Department of Pathology, Tata Memorial Hospital, Homi Bhabha National Institute, Mumbai, India.

³Department of Medical Oncology, Tata Memorial Hospital, Homi Bhabha National Institute Mumbai, India.

Authors' contributions

This work was carried out in collaboration among all authors. Authors NK and OS conceptualized the report, literature review and wrote the first and subsequent drafts of the manuscript. Authors MA and PG performed the DNA extraction, PCR and Sequencing and review of the draft. Author MR reviewed the histology and Sanger sequencing' and author VO provided input about the clinical presentation and management of the patient. All authors read and approved the final manuscript.

Article Information

DOI: 10.9734/JAMMR/2020/v32i2430770

Editor(s):

(1) Dr. Chan-Min Liu, Xuzhou Normal University, China.

Reviewers:

(1) Diana Maria Leite da Cunha Russo, University of Porto, Portugal.

(2) Iacuzzo Cristiana, University of Trieste, Italy.

Complete Peer review History: <http://www.sdiarticle4.com/review-history/64223>

Case Report

Received 25 October 2020
Accepted 30 December 2020
Published 31 December 2020

ABSTRACT

Aim: v-Raf murine sarcoma viral oncogene homolog B (*BRAF*) gene mutations are broadly divided as *BRAF* V600E and *BRAF* non-V600E. These groups exhibit differences in the clinical, histological, molecular and therapeutic mechanisms.

Case Presentation and Discussion: The case described is of a middle aged female with an aggressive rectal adenocarcinoma diagnosed on biopsy and immunohistochemistry. A rare *BRAF* non-V600E mutation at codon 601, K601E was detected. This mutation has been described in very few cases of colonic adenocarcinoma. The tumor showed extensive local and peritoneal disease with lung metastasis at presentation and progression on the primary line of chemotherapy. The aggressive predisposition of the tumor was contrary to reports suggesting non-V600E tumors to connote a better prognosis.

Conclusion: Active reporting of non-V600E *BRAF* variants in colorectal adenocarcinoma is essential in order to create a robust database which will help in assessing a biological behavior of these tumors and explore the role of targeted therapy.

*Corresponding author: E-mail: nkarnik23691@gmail.com;

Keywords: *BRAF* gene; rare; variant; colorectal adenocarcinoma; codon 601.

1. INTRODUCTION

v-Raf murine sarcoma viral oncogene homolog B (*BRAF*) gene mutation is an early event in colorectal carcinogenesis [1]. These mutations encode three protein classes; first are RAS independent monomers resulting from substitution Valine (V) to Glutamate (E) at codon 600 (*BRAF* V600E) accounting for more than 90% of *BRAF* mutations [2]. Class two and three mutations on codons 601 and 597 and codons 594 and 596 respectively are grouped as non-V600E [2]. Reporting these rare variants is essential as adequate and conclusive data regarding the biological behavior of these tumours is not available. Here, a rectal adenocarcinoma with a rare *BRAF* K601E mutation is discussed, which is the first instance of presence of the mutation at this location.

2. CASE PRESENTATION

A fifty-two year old postmenopausal woman presented with on and off complaints of white vaginal discharge for 4 months, with recent spotting. Per speculum examination showed a

mass involving the entire cervix and vaginal wall which was also felt per rectally as an exophytic growth involving the rectal mucosa.

She had serum carcinoembryonic antigen (CEA) levels of 2251 ng/mL (range 0-3 ng/mL) and cancer antigen 125 (CA-125) levels of 441.2 U/mL (range 0-35 U/mL). A computed tomography scan (CT scan) showed a 5.6x4.5x3.1 cm thickening in the middle and lower third of the rectum, lower cervix and vagina with extensive pelvic spread, peritoneal disease, enlarged abdominal and inguinal lymph nodes and multiple pulmonary nodules.

Biopsy taken from the cervix revealed an adenocarcinoma with papillary and micropapillary pattern and extracellular mucin. However, the immunoprofile was that of a lower gastrointestinal tract primary with Cytokeratin 20 (CK20) (DAKO, Denmark) and Homeobox protein CDX2 (CDX2) (DAKO, Denmark) positivity and negativity for p16^{INK4a} (Roche, USA). (Fig. 1) Retained mismatch repair proteins (MMR) (Cell Marque, USA) were noted on immunohistochemistry.

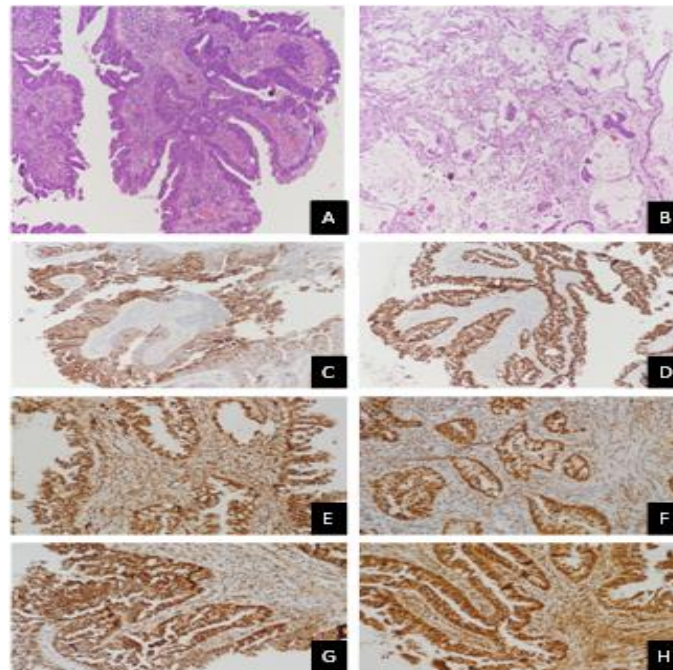


Fig. 1. Microscopic findings: A. Adenocarcinoma in papillary pattern (Hematoxylin and Eosin (H and E), x100), B. Adenocarcinoma along with extracellular mucin pools (H and E, 100x), C. Membranous positivity for CK20 (diaminobenzidine (DAB), 200x), D. Nuclear positivity for CDX2 (DAB, 200x), E-H. IHC for mismatch repair proteins showing retained nuclear staining- MLH1 (E), PMS2 (F), MSH2 (G) and MSH6 (H) (DAB, 200x)

In view of planning chemotherapy, *RAS* and *BRAF* molecular analysis was undertaken on the biopsy specimen. DNA extracted from formalin fixed paraffin embedded (FFPE) tumour section was subjected to Polymerase chain reaction (PCR) using specific primers for *RAS* and *BRAF*. (Table 1 includes details of the primers and PCR conditions used). PCR was followed by cycle sequencing, performed in Veriti thermal cycler (ABI, Thermo Fisher Scientific, USA). The cycle sequenced products were purified and were capillary electrophoresed on ABI Genetic Analyzer 3500 (Thermo Fisher Scientific, USA). The electropherograms were analysed on

Chromas lite sequence analysis software (*BRAF*-Gene ID 673, *KRAS*-Gene ID3845, *NRAS*- Gene ID 4893, *HRAS*-Gene ID 3265).

Sequencing results depicted nucleotide substitution at 1801 (c.1801A>G) on codon 601 (K601E). (Fig. 2) Exons 2, 3 and 4 of *KRAS* and *NRAS* genes and of exon 2 and 3 of *HRAS* gene showed a wild type sequence. The patient completed three cycles of Capecitabine and Oxaliplatin based chemotherapy regimen. Due to disease progression on imaging the regimen was changed to Capecitabine with Irinotecan. Currently, the patient is on regular follow-up.

Table 1. Primer sequences with specific PCR conditions required

Gene of interest		Primer sequence	Temperature
<i>BRAF</i>	Forward Primer	GGTGATTTTGGTCTAGCTACAG	56°C
	Reverse Primer	AGTAACTCAGCAGCATCTCAGG	
<i>KRAS</i> Exon 2	Forward Primer	AGGCCTGCTGAAAATGACTGAA	60 °C
	Reverse Primer	AAAGAATGGTCCTGCACCAG	
<i>KRAS</i> Exon 3	Forward Primer	GGATTCCTACAGGAAGCAAGT	60 °C
	Reverse Primer	TGGCAAATACACAAAGAAAGC	
<i>KRAS</i> Exon 4	Forward Primer	GGACTCTGAAGATGTACCTATGG	58 °C
	Reverse Primer	TCAGTGTTACTTACCTGTCTTGT	
<i>NRAS</i> Exon 2	Forward Primer	ACAGGTTCTTGCTGGTGTGA	62 °C
	Reverse Primer	ACAGGTTCTTGCTGGTGTGA	
<i>NRAS</i> Exon 3	Forward Primer	GTGGTTATAGATGGTGAAACCTGT	60 °C
	Reverse Primer	TGGCAAATACACAGAGGAAGC	
<i>NRAS</i> Exon 4	Forward Primer	TTCCCGTTTTTAGGGAGCAGA	62 °C
	Reverse Primer	TGCAAACCTCTTGACAAATGC	
<i>HRAS</i> Exon 2	Forward Primer	GGCAGGAGACCCTGTAGGAG	62 °C
	Reverse Primer	GTATTCGTCCACAAAATGGTTCT	
<i>HRAS</i> Exon 3	Forward Primer	GGAAGCAGGTGGTCATTGAT	62 °C
	Reverse Primer	TCACGGGGTTCACCTGTACT	
	Reverse Primer	GCATGCTGTTAATTGTGTGG	

Abbreviations: *BRAF*, v-Raf murine sarcoma viral oncogene homolog B; *KRAS*, Kirsten rat sarcoma viral oncogene homolog; *NRAS*, Neuroblastoma sarcoma viral oncogene homolog; *HRAS*, HRas proto-oncogene

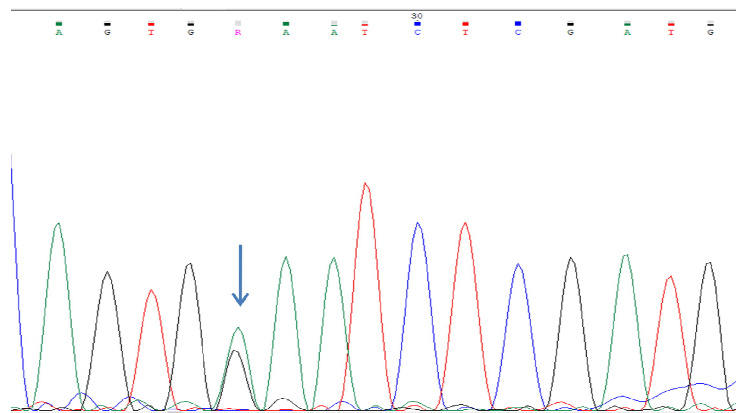


Fig. 2. Electropherogram obtained from sanger sequencing of *BRAF* gene. Heterozygous point mutations seen at nucleotide position 1801 showing Guanine in place of Adenine (c.1801A>G)

3. DISCUSSION

We describe a patient with a locally advanced rectal adenocarcinoma. Immunohistochemistry showed positivity for CDX2 along with CK20; both being extremely sensitive markers of colorectal differentiation [3]. The presence of the rare *BRAF* K601E mutation further added to the uniqueness of the tumor.

Cremolini et al in their study of *BRAF* mutations in colorectal adenocarcinomas showed that *BRAF* non-V600E mutant tumours, amounted to 1.8% [4]. These tumours were more common in females, affected the left colon and rectum, were well differentiated on histology with mucinous subtype being very infrequent and did not show peritoneal involvement [2,4]. Mucin pools and peritoneal involvement was seen in the present case which is a disparity to the above findings. The *BRAF* variant found in the present case, *BRAF* K601E mutation belongs to class two and has been described in malignant melanoma, lung carcinoma and thyroid carcinoma with an incidence of less than 5% amongst all *BRAF* mutant cases [5,6]. Osumi et al investigated 824 colorectal cancers and found *BRAF* non-V600E mutations in 14 (1.7%) cases of which, K601E mutation was seen in 1 (0.12%) case, details of which were not mentioned [7]. Moisset et al reported *BRAF* K601E mutation in a caecal adenocarcinoma in a young patient with aggressive clinical course, even showing peritoneal involvement as seen in the case presented [8]. Due to sheer uncommonness of the mutation and the different clinical pictures exhibited, it is difficult to predict the clinical presentation and progression of these tumors.

A number of researchers have analysed survival in non-V600E *BRAF* mutant cases with scant data about the K601E variant. The Biomarker Research for anti-EGFR Monoclonal Antibodies by Comprehensive Cancer Genomics (BREAC) Study showed a significantly reduced overall and progression free survival for both *BRAF* V600E and non-V600E mutant patients as compared to *BRAF* wild type ones [9]. Jones et al showed that *BRAF* V600E had the worst overall survival (11.4 months) followed by *BRAF* wild type (43 months) and lastly non-V600E mutant tumours (60.3 months) and non-V600E mutations independently correlated with improved overall survival [1,10]. A study of thyroid neoplasms also showed that specifically *BRAF* K601E mutant tumours had a better outcome than *BRAF* V600E tumours [6]. The patient with mutant *BRAF*

K601E caecal adenocarcinoma did not respond to an adjuvant chemotherapy regimen comprising Oxaliplatin, Irinotecan and Bevacizumab and died 8 months after surgery [8]. The patient being discussed is at seven months post diagnosis, on the second line of chemotherapy. Though majority of the studies show non-V600E *BRAF* mutations as having a better prognosis than the V600E counterparts, the patient described by Moisset et al and the present case showed rapid disease progression which is a distinct finding.

Regarding the therapeutic importance of *BRAF* K601E, there are reports suggestive of response to MEK inhibitors Trametinib and Binimetinib in melanoma patients [5]. Such clinical trials have not been documented in colorectal carcinoma cases and need evaluation in a larger cohort.

4. CONCLUSION

The case described, of a K601E (*BRAF* non V600E) mutant adenocarcinoma further emphasizes the need for reporting of such rare variants and following up with treatment response as definite regimens are the need of the hour in this era of personalized medicine.

CONSENT

As per international standard or university standard, participant's written consent has been collected and preserved by the author(s).

ETHICAL APPROVAL

It is not applicable.

COMPETING INTERESTS

Authors have declared that no competing interests exist.

REFERENCES

1. Caputo F, Santini C, Bardasi C, Cerma K, Casadei-Gardini A, Spallanzani A, et al. *BRAF*-mutated colorectal Cancer: Clinical and molecular insights. *Int J Mol Sci.* 2019;20(21). Available: <https://doi.org/10.3390/ijms20215369>
2. Schirripa M, Biason P, Lonardi S, Pella N, Simona Pino M, Urbano F, et al. Class 1, 2 and 3 *BRAF*-mutated metastatic colorectal Cancer: A detailed clinical, pathologic, and

- molecular characterization. Clin Cancer Res. 2019;25(13):3954-61. Available:<https://clincancerres.aacrjournals.org/content/25/13/3954.long>
3. Kaimaktchiev V, Terracciano L, Tornillo L, Spichtin H, Stoios D, Bundi M, et al. The homeobox intestinal differentiation factor CDX2 is selectively expressed in gastrointestinal adenocarcinomas. Mod Pathol. 2004;17(11):1392-99. Available:<https://doi.org/10.1038/modpathol.13800205>
 4. Cremolini C, Di Bartolomeo M, Amatu A, Antoniotti C, Morreto R, Berenato R, et al. *BRAF* codons 594 and 596 mutations identify a new molecular subtype of metastatic colorectal Cancer at favorable prognosis. Ann Oncol. 2015;26(10):2092-97. Available:[https://www.annalsofoncology.org/article/S0923-7534\(19\)35788-6/fulltext](https://www.annalsofoncology.org/article/S0923-7534(19)35788-6/fulltext)
 5. Marconcini R, Galli L, Antonuzzo A, Bursi S, Roncella C, Fontanini G, et al. Metastatic *BRAF* K601E-mutated melanoma reaches complete response to MEK inhibitor trametinib administered for over 36 months. Exp. Hematol Oncol. 2017;6(1):6. Available:<https://www.ncbi.nlm.nih.gov/pmc/articles/PMC5361706/>
 6. Coyne C, Afkhami M, Karunamurthy A, Nikiforova M, Seethala R, Nikiforov Y, et al. Histopathologic and clinical characterization of thyroid tumours carrying the *BRAF* K601E mutation. Thyroid. 2015;26(2):242-47. Available:<https://www.liebertpub.com/doi/full/10.1089/thy.2015.0227>
 7. Osumi H, Shinozaki E, Wakatsuki T, Suenaga M, Ichimura T, Ogura M, et al. Non-V600E *BRAF* mutations and EGFR signaling pathway in colorectal Cancer. Int J Cancer. 2019;145(9):2488-95. Available:<https://onlinelibrary.wiley.com/doi/abs/10.1002/ijc.32320>
 8. Moisset L, Raimbourg J, Hiret S, Dauve J, Boisdron-Celle M, Senelart H, et al. *BRAF* Non-V600E Mutated Metastatic Colorectal Cancer in a Young Patient: Discussion from a Case Report. Case Rep Oncol. 2019;12(2):426-29. Available:<https://www.ncbi.nlm.nih.gov/pmc/articles/PMC6587192/pdf/cro-0012-0426.pdf>
 9. Shinozaki E, Yoshino T, Yamazaki K, Muro K, Yamaguchi K, Nishina T, et al. Clinical significance of *BRAF* non-V600E mutations on the therapeutic effects of anti-EGFR monoclonal antibody treatment in patients with pretreated metastatic colorectal cancer: The Biomarker Research for anti-EGFR monoclonal Antibodies by Comprehensive Cancer genomics (BREAC) study. Br J Cancer. 2017;117(10):1450-58. Available:<https://www.nature.com/articles/bj2017308>
 10. Jones J, Renfro L, Al-Shamsi H, Schrock A, Rankin A, Zhang B, et al. Non-V600BRAF mutations define a clinically distinct molecular subtype of metastatic colorectal Cancer. J Clin Oncol. 2017;35(23):2624-30. Available:<https://ascopubs.org/doi/abs/10.1200/JCO.2016.71.4394>

© 2020 Karnik et al.; This is an Open Access article distributed under the terms of the Creative Commons Attribution License (<http://creativecommons.org/licenses/by/4.0>), which permits unrestricted use, distribution, and reproduction in any medium, provided the original work is properly cited.

Peer-review history:

The peer review history for this paper can be accessed here:
<http://www.sdiarticle4.com/review-history/64223>