



The Efficacy of Hyperbaric Oxygen in the Treatment of Chronic Ulcers

Nikitopoulou Th St^{1*} and Papalimperi Ath H²

¹Health Centre of Markopoulo, General Hospital of Athens "G. Gennimatas, Greece.

²Intensive Care Unit (ICU) of NIMTS Hospital of Athens, Greece.

Authors' contributions

This work was carried out in collaboration between both authors. Authors NTS and HPA contributed to the study design, coordination of the project and preparation of the manuscript. Both authors read and approved the final manuscript.

Article Information

DOI: 10.9734/BJMMR/2016/27932

Editor(s):

(1) Nurhan Cucer, Erciyes University, Medical Biology Department, Turkey.

Reviewers:

(1) Wagih Mommtaz Ghannam, Mansoura University, Mansoura, Egypt.

(2) Tan Paul, University of Yaoundé I, Cameroon.

Complete Peer review History: <http://www.sciencedomain.org/review-history/15821>

Review Article

Received 25th June 2016
Accepted 11th August 2016
Published 20th August 2016

ABSTRACT

Background: Chronic ulcers are a significant socio-economic problem and represent a major risk factor for hospitalization, amputation, sepsis and even death. The treatment of chronic ulcers is often difficult and painful. Experimental results have shown that hyperbaric oxygen therapy (HBOT) is useful to the treatment of chronic ulcers and particularly in diabetic ulcers. The objective of this literature review was to research the effectiveness of HBOT in healing chronic ulcers.

Methods: A review of the literature was performed, in electronic databases PubMed, Cinahl, latrotek on-line and in Health Sciences Library with the following key words: "chronic ulcers", "wound healing", "HBOT", "HBOT in chronic ulcers", "venous ulcers", "diabetic ulcers", "pressure ulcers".

Results: Ten randomized controlled trials, one retrospective trial and one clinical trial, were included. Nine studies involved patients with diabetic ulcers, in one study patients with venous ulcers, in one study patients with diabetic and venous ulcers and in one study patients with pressure ulcers. HBOT improves the healing rate of wounds and the period of the treatment, reduces the size of the wounds and the risk of amputation in diabetic ulcers. In venous and pressure ulcers the effectiveness of HBOT is still unclear, due to the minimum number of available trials.

*Corresponding author: E-mail: doranikitopoulou@gmail.com;

Conclusion: There is evidence that the use of HBOT can improve healing of chronic ulcers, but the available results are inadequate to prove it clearly. Any benefit from HBOT should be further examined in unbiased randomized trials.

Keywords: Hyperbaric oxygen therapy; chronic ulcers; wound healing.

1. INTRODUCTION

Chronic ulcers are classified into diabetic, vascular (venous and arterial) and pressure ulcers (bed sores) [1]. They require significant time to heal, a fact which gradually led to a better design of conventional treatments [2-4]. The optimal management of ulcers includes early recognition [5]. Patients are experiencing severe biopsychosocial issues, which degrade their quality of life (QOL). An improvement of QOL will be achieved by giving special attention to the interaction between the healing process and the existence of ulcers [6]. The pathophysiological relation between diabetes and delayed healing is complicated. Only two thirds are finally cured, while a 28% might be led to amputation [7]. Furthermore, the treatment of chronic wounds is a major financial burden for both patients and health system [8,9].

Many interventions have been proposed in order to accelerate the healing process. The treatment of chronic ulcers in diabetic population has been significantly improved during the last 15 years with the development of care programs and the introduction of advanced therapies [10]. One of the most promising therapies is the hyperbaric oxygen therapy (HBOT) [11] which is achieved when the person is breathing 100% O₂ with intervals, in a hyperbaric chamber where the pressure is greater than 1 atm (standard atmosphere) [2]. The partial oxygen pressure (PO₂) is increased at all tissues of the body, because of the increased diffusion difference of hyperbaric oxygen [12,13]. When oxygen is administered at a higher pressure than the atmospheric pressure, it is considered as a medicine with specific mechanism of action, indications, contraindications, dosage, treatment duration and adverse effects [13].

The purpose of this review was to investigate the efficacy of hyperbaric oxygen in the treatment of chronic ulcers.

2. METHODOLOGY

PubMed, Cinahl and Iatrotek on-line were used for the literature search, where published articles, studies and abstracts were found on the web,

using keys such as: "chronic ulcers", "wound healing", "HBOT", "HBOT in chronic ulcers", "venous ulcers", "diabetic ulcers" and "pressure ulcers". Moreover, a research in Health Sciences Library's magazines and books was conducted.

The review of the literature showed 65 studies concerning the use of HBOT in patients with chronic ulcers. Studies that were published during the last twenty years were included (with the exception of a study [14] which is the only one concerning the administration of HBOT in pressure ulcers). Studies in animal models and study protocols were also excluded. After the evaluation of the studies, 6 of the studies were excluded, based on the exclusion criteria (studies in animal models and study protocols), while only 12 studies met the inclusion criteria for the review (Fig. 1).

3. RESULTS

At the present review 10 randomized controlled trials (RCTs) [6,15-18,19-23], a retrospective [24] and a clinical study [14] have been comprised (Table 1).

All studies referred to the application of HBOT in patients with chronic ulcers. Subsequently, nine of these studies [6,16-22,24] were related to patients with diabetic ulcers, one randomized controlled trial [23] was related to patients with venous ulcers, whereas another randomized controlled trial [15] was concerned about patients with diabetic and venous ulcers. Finally, the clinical study [14] of Rosenthal et al. studied patients with chronic pressure ulcers.

The study of Kaur et al. [15] showed that HBOT increased the wound healing rate after 6 months of treatment and that three HBOT patients (out of 30) were completely healed. It was also found that the wound size was reduced by 59% in patients that underwent HBOT, while there was an increase of Transcutaneous Oxygen Tension (TcPO₂) or Transcutaneous oximetry (TCOM). In the following studies: RCT [6], RCT [17], RCT [18], RCT [19], RCT [20], RCT [21], RCT [22], RCT [23], there were similar results of increasing rate of wound healing and reducing wound size.

Table 1. Characteristics of studies investigating the use HBOT in chronic ulcers

Author (s)	Type of study	Chronic ulcer description	Study population				HBOT			Number of amputations	Results	
							ATA	Min	Num. of Therapies			
Kaur et al., 2012 [15]	RCT	Diabetic-Venous (> 4 weeks)	15 HBOT	15 C/T				2.5	90	30	1 HBOT 5 C/T	<ul style="list-style-type: none"> - HBOT increases the healing rate - Complete healing in 3 HBOT - 59% reduction in the size of the wound with HBOT - Increase of TcPO₂
Wang et al., 2011 [16]	RCT	Diabetic Wagner* 2-4	45 HBOT	41 ESWT				2.5	90	20	Not reported	<ul style="list-style-type: none"> 4-6 weeks: - Complete healing: 57% ESWT, 25% HBOT - Improving ulcers: 32% ESWT, 15% HBOT - No change: 11% ESWT, 60% HBOT
Löndahl et al., 2011 [6]	Single-center, double-blind RCT with placebo administration and use of SF-36	Diabetic (>3 months) Wagner 2-4	38 HBOT	37 placebo				2.5	85	40	Not reported	<ul style="list-style-type: none"> - HBOT increases the healing rate - Reduces the size of the wound at 1-year of follow-up in 23 HBOT and 10 placebo administration - HBOT improves HRQL
Löndahl et al., 2010 [17]	Single-center, double-blind RCT with placebo administration	Diabetic (>3 months)	49 HBOT	45 placebo				2.5	85	40	After a 1-year of follow-up in 4 HBOT and 4 placebo administrations	<ul style="list-style-type: none"> - HBOT increases the healing rate - Reduces the size of the wound at 1-year of follow-up in 61% HBOT and in 27% placebo administration
Duzgun et al., 2008 [18]	RCT	Diabetic (>4 weeks)	50 HBOT	50 C/T				2.0	90	35-45	After 92 weeks in 9 HBOT and in 17 C/T	<ul style="list-style-type: none"> - HBOT increases the healing rate With additional use of surgical debridement or skin grafting
Lyon, 2008 [24]	Retrospective	Diabetic	13 HBOT	25 C/T	25 HBOT /GF	26 GF		-	-	-	Not reported	<ul style="list-style-type: none"> At eight weeks: - HBOT increases the healing rate and reduces the wound size in HBOT and HBOT / GF
Adibia et al., 2003 [19]	Double-blind RCT	Diabetic (>6weeks)	8 HBOT	8 C/T				2.4	90	30	2 HBOT and 1 C/T	<ul style="list-style-type: none"> - HBOT increases the healing rate - Reduces the wound size in 6 weeks in 5 HBOT - Increase of TcPO₂ - HBOT improves HRQL - Cost-effective use of HBOT
Kessler et al., 2003 [20]	RCT	Diabetic (>3 months) Wagner 1-3	14 HBOT	13 C/T				2.5	90	20	Not reported	<ul style="list-style-type: none"> - HBOT increases the healing rate - Reduces the wound size in 4 weeks in 2 HBOT - Increase of TcPO₂ with HBOT

Author (s)	Type of study	Chronic ulcer description	Study population	HBOT			Number of amputations	Results	
				ATA	Min	Num. of Therapies			
Lin et al., 2001 [21]	RCT	Diabetic Wagner 0-2	17 HBOT	12 C/T	2.5	120	30	Not reported	- HBOT increases the healing rate - Increase of TcPO ₂ with HBOT - HBOT improves vascular function
Faglia et al., 1996 [22]	RCT	Diabetic (>3 months) Wagner 2-4	35 HBOT	33 C/T	2.2-2.5	90	38	After 7 weeks in 3 HBOT and in 11 C/T	- HBOT increases the healing rate
Hammarlund et al., 1994 [23]	Double-blind RCT with placebo administration	Venous (>1 year)	8 HBOT	8 Placebo	2.5	90	30	Not reported	- HBOT increases the healing rate - Reduces the wound size in 6 weeks in 35.7% HBOT and in 2.7% placebo administration -After 18 weeks relapse rate: 31%
Rosenthal et al., 1971 [14]	Clinical Study	Pressure ulcers	18 HBOT	3 C/T	3.0	90	37	Not reported	- Complete healing: 58% HBOT - Improved ulcers: 13% HBOT

*HBOT: Hyperbaric Oxygen Therapy, ATA: Atmosphere Absolute, RCT: Randomized Controlled Trial, N/T: Number of Therapies, C/T: Conventional Treatment, TcPO₂: Transcutaneous Oxygen Tension, SF-36: Short Form (36) Health Survey, HRQL: Health-Related Quality of Life, ESWT: Extra corporal Shock Wave Therapy, GF: Growth Factors, *: Wagner Classification System*

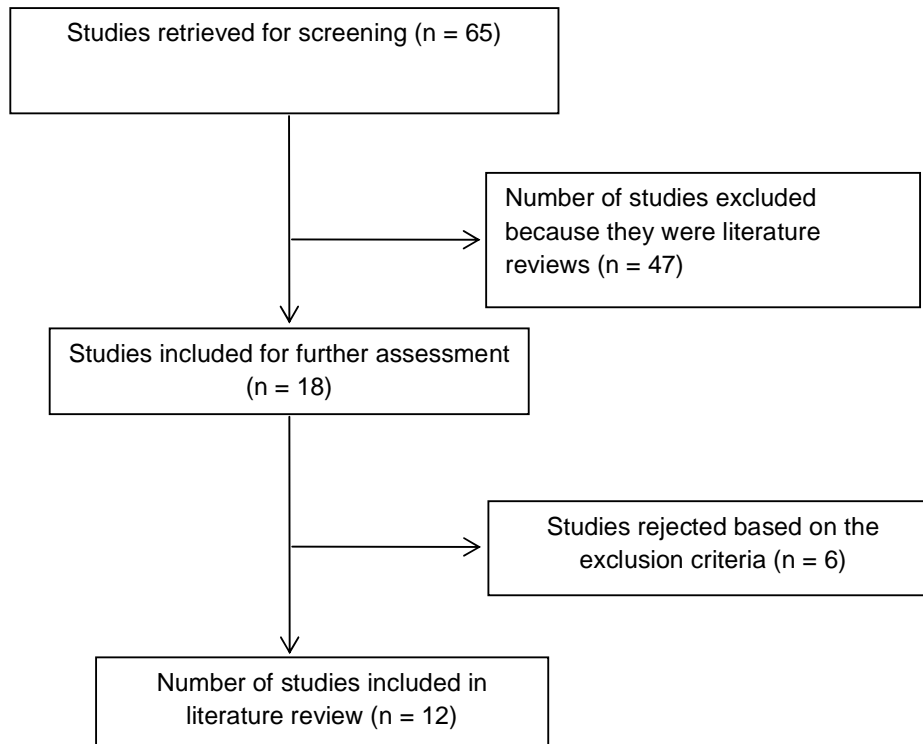


Fig. 1. Flowchart of literature review steps

Lyon included four groups of patients in her retrospective study [24] and proved that HBOT increases the healing rate, and that the use of HBOT in combination with the use of growth factors (GFs), contributes to reducing the size of the wound. Thereafter, the clinical results of Rosenthal et al. RCT [14] showed that 58% of patients treated with HBOT were completely healed, when 13% of them showed an improvement of ulcers.

The clinical results of Wang's et al. RCT [16] showed that the use of Extra corporal Shock Wave Therapy (ESWT) has been proved to be more effective than HBOT, after a 4-6 weeks period of treatment.

Errors (bias), confounding factors and restrictions were not systematically reported in all the above studies.

4. DISCUSSION

According to this literature review the majority of studies regarding the use of hyperbaric oxygen (HBO) as a treatment for chronic ulcers, mostly concerned diabetic leg ulcers, one concerned venous ulcers and another one was about pressure ulcers. The clinical results of all studies

were based on the rate of wound healing, the required time for the successful completion of the treatment and the decrease of the wound size after the application of HBOT. In several studies [15,17,18,19,23], data have been presented with the number of amputations performed after treatment, whereas in two studies [6,19] the patients' quality of life was evaluated, with the use of Short Form (36) Health Survey (SF-36) questionnaires. The cost-effectiveness of HBOT was examined in one study [19] and four studies [15,19,20,21] have recorded the increased TcPO₂ after HBOT administration.

The oxygen dose, the duration and the number of HBO treatments were relatively the same in all studies, although the ulcer classification, the healing time and the reduction of the wound size varies. There were recorded information on amputation (primary and secondary) in patients with diabetic ulcers in 5 studies [15,17,18,19,23], which indicated that HBOT contributed to a reduction of amputation numbers [25], in comparison with patients who were treated with either conventional treatment, or placebo.

Moreover, four studies [15,19-21] showed that TcPO₂ increases in the area around the wound after an HBOT, which is indeed an advantage for

its use. TcPO₂ provides an easy, reliable, noninvasive diagnostic measurement for the evaluation of tissue oxygenation and wound perfusion [26]. It can be used for the assessment of perfusion of tissue in diabetic ulcer area and for the estimation of healing probability. TcPO₂ can also be used for the selection of the level of amputation and in selecting the suitable patients for the use of HBOT as well.

Patients with diabetic foot ulcers according to Wagner classification system with Wagner grade III, IV and V (deep ulcer with abscess, osteomyelitis, joint sepsis, local gangrene or gangrene of entire foot) [27], are considered to be the most appropriate group for the application of HBO as an adjunctive therapy [25,28,29].

In two of the studies [6,19] patients completed the questionnaire (SF-36) both before treatment with hyperbaric oxygen and after a 12-month follow-up, in order to assess the mental and physical condition and their Health-Related Quality of Life (HRQL). The SF-36 was comprised of eight sections, including physical functioning, general health perceptions, bodily pain, social function, vitality and the limitations which have an important role because of the physical, emotional and mental health as well. The results of both studies showed that the use of HBOT improves the quality of life in physical functioning, as well as the psychological and social condition.

Although this review investigated research results that mainly indicated that HBOT reduces the risk of amputation and increases the rate of wound healing, several studies had different outcomes. In the study of Wang et al. [16] where clinical results of a group of patients treated with HBOT and in a group of patients that were given an ESWT treatment were compared, the use of ESWT therapy proved to be more effective than the HBOT.

A small randomized study [23] was conducted for patients with venous ulcers and showed the reduction of the wound area by using HBOT for 6 weeks, but no complete healing. This study demonstrated that HBOT efficacy in patients with venous ulcers is unreliable, since it reduces the extent of ulceration in the short term, but after 18 weeks of HBO treatment a large proportion of relapse seems to occur (31%).

A single clinical study was included [14] which demonstrated that HBOT administration to patients with pressure ulcers showed complete

healing in most patients (58%). Apart from the previously mentioned study, it was not possible to find other relevant ones, while other authors [30] have identify no other trials. HBOT efficacy in patients with pressure ulcers remains unreliable and further studies must be carried out, since there are not enough studies to prove beyond scientific doubt the beneficial effects of hyperbaric oxygen on chronic pressure ulcers [30,31].

There were side effects reported in three studies [17,20,22]. In these studies, there were two cases of ear barotraumas [22] and one patient with barotraumatic otitis who was discharged from the study group [20]. In one study [17] two cases with symptoms of hypoglycaemia and an ear barotrauma incident were recorded. Furthermore, myringotomy tubes had to be inserted in four patients, because of the pain caused by the failure to equilibrate pressure in the middle ear spaces [17]. Similar treatment complications were also referred to Löndahl's review [32].

Diabetic ulcers remain a major complication of diabetes mellitus with significant importance to morbidity and mortality. The supplementary therapeutic intervention of HBO has provided significant statistic evidence of a reduction in amputations both in clinical and experimental studies of the diabetic foot, although, as suggested by many authors [30,33,34], there should have been more randomized double "blind" studies, compared to equivalent retrospective studies.

5. CONCLUSION

Even though there is evidence that the use of HBO can improve the healing of chronic ulcers, it is not yet widely accepted. The number of clinical studies regarding its efficacy is not large enough, resulting in a controversial application of the treatment. There are numerous clinical aspects factors that may affect the healing of chronic ulcers. Thus there is an urgent need for the creation of large, multi-centered, prospective, randomized, controlled trials based on reliable criteria for the use of HBOT.

CONSENT

It is not applicable.

ETHICAL APPROVAL

It is not applicable.

COMPETING INTERESTS

Authors have declared that no competing interests exist.

REFERENCES

1. Gould L, Abadir P, Brem H, Carter M, Conner-Kerr T, Davidson J, et al. Chronic wound repair and healing in older adults: Current status and future research. *Journal of the American Geriatrics Society*. 2015; 63:427-438.
2. Thackham JA, McElwain DLS, Long RJ. The use of hyperbaric oxygen therapy to treat chronic wounds: A review. *Wound Repair and Regeneration*. 2008;16:321-330.
3. Samson DJ, Lefevre Fr, Aronson N. Wound-healing technologies: Low-level laser and vacuum-assisted closure evidence reports/technology assessments, no. 111. Rockville (MD): Agency for Healthcare Research and Quality (US); 2004.
4. Fonder MA, Lazarus GS, Cowan DA, Aronson-Cook B, Kohli AR, Mamelak AJ. Treating the chronic wound: A practical approach to the care of nonhealing wounds and wound care dressings. *Journal of the American Academy of Dermatology*. 2008;58:185-206.
5. Falanga V. European Wound Management Association (EWMA), Position document: Wound bed preparation in practice. London: MEP Ltd; 2004.
6. Löndahl M, Landin-Olsson M, Katzman P. Hyperbaric oxygen therapy improves health-related quality of life in patients with diabetes and chronic foot ulcer. *Diabetic Medicine*. 2011;28:186-190.
7. Hinchliffe RJ, Valk GD, Apelqvist J, Armstrong DG, Bakker K, Game FL. A systematic review of the effectiveness of interventions to enhance the healing of chronic ulcers of the foot in diabetes. *Diabetes-Metabolism Research and Reviews*. 2008;24:119-144.
8. Jeffcoate WJ, Harding KG. Diabetic foot ulcers. *Lancet*. 2003;361:1545-1551.
9. Gerassimidis T, Karkos CD, Karamanos D, Kampaoudis A. Current endovascular management of the ischaemic diabetic foot. *Hippokratia*. 2008;12:67-73.
10. Kranke P, Bennett M, Roeckl-Wiedmann I, Debus S. Hyperbaric oxygen therapy for chronic wounds. *The Cochrane Library*. 2006;1.
11. Hyperbaric Oxygen Therapy Committee of the Undersea and Hyperbaric Medical Society. Hyperbaric oxygen therapy committee report. Undersea and Hyperbaric Medical Society: Kensington MD; 2001.
12. Mesimeris T. Decompression sickness. *Hippokratia*. 2000;4:14-18.
13. Nikitopoulou TS, Papalimperi AH. The inspiring journey of hyperbaric oxygen therapy, from the controversy to the acceptance by the scientific community. *Health and Science Journal*. 2015;9:1-8.
14. Rosenthal AM, Schurman A. Hyperbaric treatment of pressure sores. *Archives of Physical Medicine and Rehabilitation*. 1971;52:413-415.
15. Kaur S, Pawar M, Banerjee N, Garg R. Evaluation of the efficacy of hyperbaric oxygen therapy in the management of chronic nonhealing ulcer and role of periwound transcutaneous oximetry as a predictor of wound healing response: A randomized prospective controlled trial. *Journal of Anaesthesiology Clinical Pharmacology*. 2012;28:70-75.
16. Wang CJ, Wu RW, Yang YJ. Treatment of diabetic foot ulcers: A comparative study of extracorporeal shock wave therapy and hyperbaric oxygen therapy. *Diabetes Research and Clinical Practice*. 2011;92: 187-93.
17. Löndahl M, Katzman P, Nilsson A, Hammarlund C. Hyperbaric oxygen therapy facilitates healing of chronic foot ulcers in patients with diabetes. *Diabetes Care*. 2010;33:998-1003.
18. Duzgun AP, Satir HZ, Ozozan O, Saylam B, Kulah B, Coskun F. Effect of hyperbaric oxygen therapy on healing of diabetic foot ulcers. *Journal of Foot and Ankle Surgery*. 2008;47:515-519.
19. Abidia A, Laden G, Kuhan G, Johnson BF, Wilkinson AR, Renwick PM, et al. The role of hyperbaric oxygen therapy in ischaemic diabetic lower extremity ulcers: a double-blind, randomized-controlled trial. *European Journal of Vascular and Endovascular Surgery*. 2003;25:513-518.
20. Kessler L, Bilbault P, Ortéga F, Grasso C, Passemard R, Stephan D, et al. Hyperbaric oxygenation accelerates the healing rate of nonischemic chronic diabetic foot ulcers: A prospective randomized study. *Diabetes Care*. 2003; 26:2378-2382.

21. Lin TF, Chen SB, Niu KC. The vascular effects of hyperbaric oxygen therapy in treatment of early diabetic foot. *Undersea and Hyperbaric Medicine*. 2001;28:63.
22. Faglia E, Favales F, Aldeghi A, Calia P, Quarantiello A, Oriani G, et al. Adjunctive systemic hyperbaric oxygen therapy in treatment of severe prevalently ischemic diabetic foot ulcer. A randomized study. *Diabetes Care*.1996;19:1338-1343.
23. Hammarlund C, Sundberg T. Hyperbaric oxygen reduced size of chronic leg ulcers: a randomized double-blind study. *Plastic and Reconstructive Surgery*. 1994;93:829-833.
24. Lyon KC. The case for evidence in wound care: Investigating advanced treatment modalities in healing chronic diabetic lower extremity wounds. *Journal of Wound, Ostomy and Continence Nursing*. 2008; 35:585-590.
25. Murad MH, Haydour Q, Benkhadra K. ACP Journal Club. Review: In patients with chronic diabetic foot ulcers, hyperbaric oxygen reduces major amputations. *Ann Intern Med*. 2013;159:JC9.
26. Niinikoski J. Clinical hyperbaric oxygen therapy, wound perfusion, and transcutaneous oximetry. *World Journal of Surgery*. 2004;28:307-311.
27. Wagner FW Jr. The diabetic foot. *Orthopedics*.1987;10:163-172.
28. Liu R, Li L, Yang M, Boden G, Yang G. Systematic review of the effectiveness of hyperbaric oxygenation therapy in the management of chronic diabetic foot ulcers. *Mayo Clin Proc*. 2013;88: 166-75.
29. Goldstein LJ. Hyperbaric oxygen for chronic wounds. *Dermatol Ther*. 2013; 26:207-214.
30. Kranke P, Bennett MH, Martyn-St James M, Schnabel A, Debus SE, Weibel S. Hyperbaric oxygen therapy for chronic wounds. *Cochrane Database Syst Rev*. 2015;24:CD004123.
31. Kuffler DP. Improving the ability to eliminate wounds and pressure ulcers. *Wound Repair Regen*. 2015;23:312-317.
32. Löndahl M. Hyperbaric oxygen therapy as adjunctive treatment for diabetic foot ulcers. *Int J Low Extrem Wounds*. 2013; 12:152-157.
33. Mills BJ. Wound healing: The evidence for hyperbaric oxygen therapy. *Br J Nurs*. 2012;21:28, 30, 32, 34.
34. Yazdanpanah L, Nasiri M, Adarvishi S. Literature review on the management of diabetic foot ulcer. *World J Diabetes*. 2015; 6:37-53.

© 2016 St and Ath; This is an Open Access article distributed under the terms of the Creative Commons Attribution License (<http://creativecommons.org/licenses/by/4.0>), which permits unrestricted use, distribution, and reproduction in any medium, provided the original work is properly cited.

Peer-review history:
The peer review history for this paper can be accessed here:
<http://sciencedomain.org/review-history/15821>