



# Comparing the Efficacy of CTG Versus Periocol<sup>®</sup> - GTR Membrane in the Treatment of Isolated Gingival Recession Defects: Two Case Reports

**Manisha Daruka<sup>a++\*</sup>, Shivi Khattri<sup>a#</sup>, Mayur Kaushik<sup>at</sup> and Nitin Tomar<sup>a‡</sup>**

<sup>a</sup> *Subharti Dental College and Hospital, India.*

## **Authors' contributions**

*This work was carried out in collaboration among all authors. All authors read and approved the final manuscript.*

## **Article Information**

### **Open Peer Review History:**

This journal follows the Advanced Open Peer Review policy. Identity of the Reviewers, Editor(s) and additional Reviewers, peer review comments, different versions of the manuscript, comments of the editors, etc are available here: <https://www.sdiarticle5.com/review-history/107427>

**Case Study**

**Received: 07/08/2023**  
**Accepted: 14/10/2023**  
**Published: 27/10/2023**

## **ABSTRACT**

Gingival recession is an apical displacement of gingival tissue which leads to root surface exposure causing aesthetic problem, attachment loss, hypersensitivity, and root caries. Connective Tissue Graft (CTG) is a gold standard procedure while GTR is also an effective and predictable surgical approach for recession coverage. Periocol<sup>®</sup> is sterile, type I bioresorbable collagen membrane of fish origin. The aim of this study is to comparatively evaluate the treatment of Miller class I and class II recession defects of maxillary anteriors by using CTG or Periocol<sup>®</sup>- Guided Tissue Regeneration (GTR) membrane.

To the author's knowledge this is the first study comparing the efficacy of CTG with Periocol<sup>®</sup> GTR

<sup>++</sup> *Junior Resident;*

<sup>#</sup> *Associate Professor;*

<sup>†</sup> *Professor and Head;*

<sup>‡</sup> *Professor;*

<sup>\*</sup>*Corresponding author: Email: manishadaruka01@gmail.com;*

membrane. Two patients were selected and subjected to two different techniques i.e CTG and Periocol® - GTR membrane. Evaluation was done on the basis of percentage gain in root coverage and increase in the width of keratinized gingiva.

Optimal results were achieved in both the cases regarding clinical measurements of recession coverage although greater coverage was seen in patient treated with Periocol®. Both the treatment modalities can be utilized for gingival recession coverage but with limitations in both. Recession coverage with Periocol® can be used as another option besides CTG.

*Keywords: Collagen; gingival; root surface; soft tissue cells.*

## 1. INTRODUCTION

Gingival recession is a common manifestation in most populations with more than 50% of the population having one or more sites with gingival recession of 1mm or more. It is clinically manifested by an apical displacement of gingival tissue. It also leads to root surface exposure which causes major functional and aesthetic problems [1]. The most common cause of gingival recession is faulty tooth brushing; while other factors include dental plaque, high frenum pull, area of root prominence, iatrogenic factors and postsurgical gingival recession [2].

Langer & Langer [3] Introduced CTG in treating gingival recession, in which CTG combined with an overlying pedicle-graft were used. It is the gold standard procedure as it has various advantages like the graft having dual blood supply, i.e. from the recipient bed and from the overlying flap. It also has better colour matching to the adjacent gingiva and the prognosis of recession coverage has been excellent, as has been reported by Langer and Langer [3], Edel [4], Broome and Taggart [5], Nelson [6].

The concept of GTR was introduced by Melcher 1976 and Nyman et al. [7] for treatment of periodontal defects.

GTR involves placement of either resorbable or non-resorbable barrier to seclude a space around the diseased root surface and allow cells from PDL and alveolar bone to repopulate the defect by refraining soft tissue cells from penetrating it [8].

Periocol® (Eucare Pharmaceuticals Pvt. Ltd, Chennai, India) is derived from specially controlled and certified animals and is highly purified to avoid any antigenicity.

Thus, in the present study, a comparative evaluation has been done for the treatment of Miller class I and Class II recession defects with

CTG versus Periocol® - GTR membrane. To the author's knowledge this is the first study comparing the efficacy of CTG with Periocol® GTR membrane.

## 2. CASE PRESENTATION

Two male patients of age 35 years and 40 years were selected from the OPD of Subharti Dental College & Hospital and randomly subjected to either of the treatment modalities namely Periocol® or CTG. Patient's medical history, dental history, personal history was taken and clinical parameters including Gingival Index (Loe and Silness, 1963), Plaque Index (Silness and Loe, 1964), Probing pocket depth (in mm) measured by UNC-15 periodontal probe using gingival margin as reference, Recession length and Width of keratinized gingiva (in mm) was measured by using UNC-15 periodontal probe. All parameters were recorded at baseline, 1 month and 3 months interval. Inclusion criteria included: i) Miller's Class I (marginal tissue recession does not extend to mucogingival junction. There is no loss of bone or soft tissue in the interdental area) class II gingival recession (marginal tissue recession extends to or apical to the mucogingival junction. There is no loss of bone or soft tissue in the interdental area) defect at the buccal aspect of maxillary incisors or canines ii) No previous periodontal surgery at the affected teeth. Exclusion criteria included i) Patient with history of any recent periodontal surgery in past 6 months ii) Pregnant and lactating patients iii) Smokers. Scaling and root planing was performed before proceeding with the surgery.

## 3. SURGICAL PROCEDURE

### 3.1 Site 1 (Subjected to CTG)

#### 3.1.1 Donor site

Local infiltration anesthesia was administered using 2% lignocaine HCl with adrenaline

(1:80000). A horizontal incision was made 5-6 mm from the free gingival margins near the premolar area in the palate using three incisions (Trapdoor Technique) [4] (Fig.1,2); followed by two internal vertical incisions on either side. A graft thickness of 1.5 mm was prepared (Fig. 3) and was placed on the recipient site.

### 3.1.2 Recipient Site

After anesthetizing, a sulcular incision was given and a pouch was created (Fig.4). The pouch was extended 3mm lateral to the recession defect and beyond the mucogingival junction apically. Then the CTG was placed (Fig.5) and the flap was coronally positioned to cover the recipient teeth and the area was sutured with 5-0 PGA/PLA anchored suture with composite button (Fig. 6&7).

### 3.2 Site 2 (Subjected to GTR)

At this site, the initial preparation of recipient site was similar to that of site 1(Fig.8). Two horizontal bevelled incisions (3mm in length) were given, mesial and distal to the recession defect located at a distance from the tip of the papillae followed

by two vertical incisions extending to the alveolar mucosa (Coronally Advanced Flap) [9]. The flap was then reflected (Fig.9), Periocol® membrane was placed (Fig.10) and the flap was stabilized using sutures (Fig. 11&12).

### 3.3 Post Operative Instructions

The patient was asked not to brush near the surgical site. Warm saline rinses were advised after 24 hours of surgery. Amoxicillin plus clavulanic acid 625mg combination was given for 5 days along with anti-inflammatory drug.

## 4. DISCUSSION

Gingival recession coverage was evaluated on the basis of 1. post operative recession length (RL), 2. % gain in root coverage (RC%), and 3. Percentage increase in width of keratinized gingiva (WKG%). RL at 1 and 3 months for CTG was recorded to be 1mm and RL at 1 and 3 months for Periocol was also 1mm. RC% and WKG% for periocol was 66.66% and 25% respectively at both 1 month and 3 months and it was 50% and 25% respectively in CTG at both 1 and 3 months.

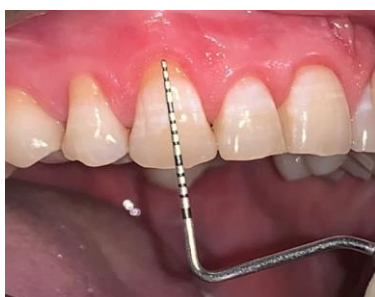

Fig. 1. Pre operative site

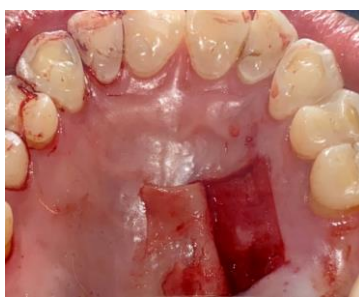

Fig. 2. Trapdoor epithelial flap reflected

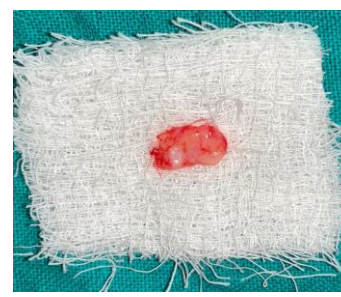

Fig. 3. Procured connective tissue graft

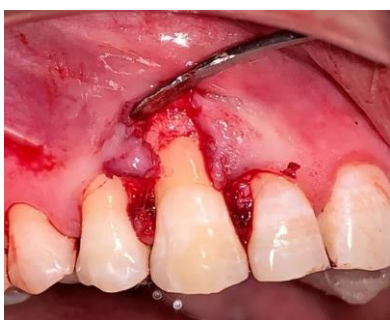

Fig. 4. Reflection at recipient site

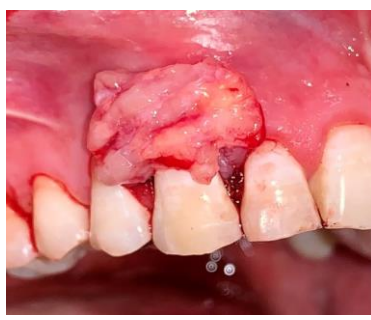

Fig. 5. Connective tissue graft placed at recipient site

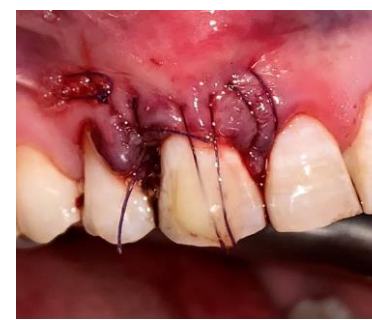

Fig. 6. Flap coronally anchored with composite button

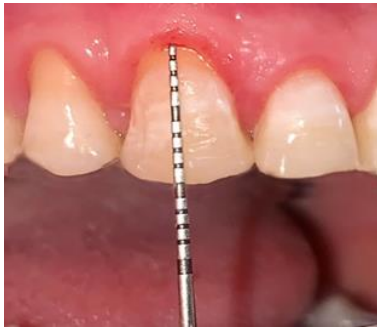

Fig. 7. Post operative view

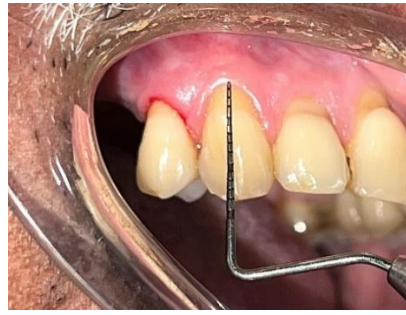


Fig. 8. Pre operative site

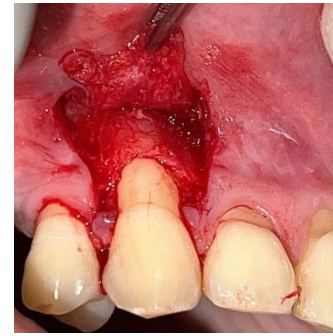

Fig. 9. Reflection at recipient site

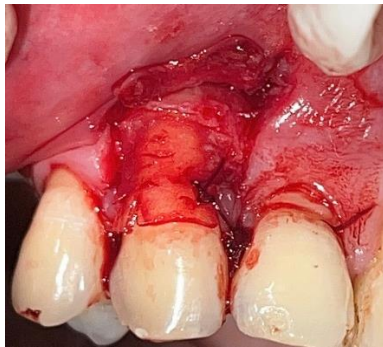

Fig. 10. Periocol® membrane placed and sutured

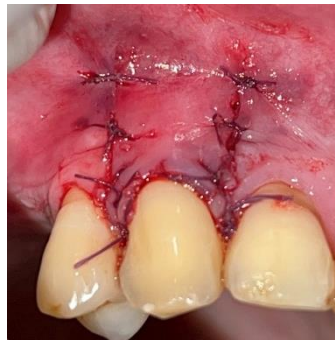


Fig. 11. Flap sutured

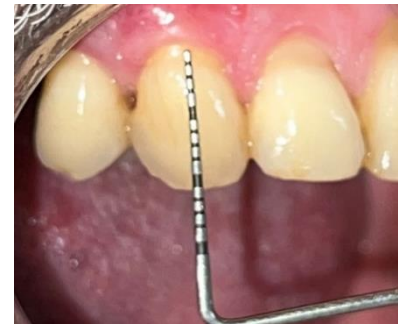

Fig. 12. Post operative site

Table 1. Gingival recession coverage in both the treatment modalities

	RL			RC%		WKG%	
	Baseline	1 month	3 months	1 month	3 months	1 month	3 months
Periocol®	3mm	1mm	1mm	66.66%	66.66%	25%	25%
CTG	2mm	1mm	1mm	50%	50%	25%	25%

Also, the results so obtained might be because of the differences in baseline measurements of clinical parameters of both the patients.

An accurate diagnostic and interdisciplinary approach is necessary for obtaining improved, conservative and predictable results in esthetically compromised areas, like the anterior maxillary dentition [10]. Gingival recession coverage in both the treatment modalities was satisfactory. Better soft tissue coverage was achieved in case of recession defect treated with Periocol compared to area treated with CTG. Although, increase in the width of keratinized gingiva was same for both the cases. Both the treatment modalities can be utilized for gingival recession coverage but with limitations in both. In

patients with thin gingival biotype, recession coverage using Periocol might be difficult. Secondly, Periocol® is a fragile GTR membrane which starts degenerating as soon as it comes in contact with body fluids. Thus, the membrane has to be handled very carefully to prevent it from tearing during suturing. As discussed earlier, though CTG being a gold standard modality for recession coverage, it offers obvious disadvantage of second surgical site. Healing might get delayed due to clot dislodgement if the patient continuously hits the palate with his tongue.

So, considering the do's and dont's of both the techniques, the clinician should judiciously select the patient for either of the

clinical modalities in order to obtain optimum results.

In a study done by Rosetti et al. [11] in which he found CTG significantly better than those of the GTR procedure for keratinized tissue width, gingival recession height, root coverage, whereas, GTR was found to be statistically superior to CTG when probing depth was evaluated at 18 months post-surgery. Similarly, Babu et al. [12] compared bioresorbable collagen membrane with autogenous CTG for recession coverage and obtained a mean root coverage of 84.84% with CTG and 84% with collagen membrane.

## 5. CONCLUSION

Both the modalities CTG and GTR procedure yields good results but can vary according to the location of the tooth in oral cavity i.e canine being the corner teeth might not result in as good coverage as that can be achieved in the incisor teeth. CTG has the limitation of requiring a second surgical site while Periocol has the limitation of it being fragile therefore suturing the membrane is an issue. In this study, better result was obtained with Periocol® in terms of recession coverage but to be conclusive on the efficacy of Periocol® in comparison with CTG requires more studies with larger sample size.

## CONSENT

Informed consent was obtained from both the patients.

## ETHICAL APPROVAL

Ethical approval was obtained from the institutional review board for the conduction of the study.

## COMPETING INTERESTS

Authors have declared that no competing interests exist.

## REFERENCES

1. Rana MN, Arora R, Kaushik M, Verma V. Root coverage with lateral pedicle flap: A Case Report. *Int J Curr Adv Res* 2021;10:2319-6505.

2. Agarwal M, Dhruvakumar D. Coronally repositioned flap with bioresorbable collagen membrane for miller's class I and II recession defects: A Case Series. *MedPrincPract* 2019;28:477-480.
3. Langer B, Langer L. Subepithelial connective tissue graft technique for root coverage. *J Periodontol* 1985;56:715-720.
4. Edel A. Clinical evaluation of free connective tissue grafts used to increase the width of keratinized gingiva. *J Clin Periodontol.* 1974;1:185-189.
5. Broome WC, Taggart EJ. Free autogenous connective tissue grafting: report of two cases. *J Periodontol.* 1976;47:580-585.
6. Nelson SW. The subpedicle connective tissue graft. *J Periodontol* 1987;58:95-102.
7. Nyman S, Lindhe J, Karring T, Gottlow J, Wennstrom J. New attachment formation in human periodontium by guided tissue regeneration: Case reports. *J Clin Periodontol* 1986;13:604-616.
8. Saleem M, Tyagi A, Rana N, Kaushik M. Root Biomodification enhancing the predictability of isolated recession coverage—A 3 year follow-up case report. *J Adv Med Dent Scie Res* 2021;9:112-114.  
DOI:https://doi.org/10.52403/ijhsr.20230620
9. de Sanctis M, Zucchelli G. Coronally advanced flap: a modified surgical approach for isolated recession-type defects: three-year results. *J Clin Periodontol.* 2007;34(3):262-8.  
DOI: 10.1111/j.1600-051X.2006.01039.x.  
PMID: 17309597.
10. Tomar N, Bansal T, Bhandari M, Sharma A. The perio-esthetic-restorative approach for anterior rehabilitation. *J Indian Soc Periodontol.* 2013;17(4):535-538.  
DOI: 10.4103/0972-124X.118332.  
PMID: 24174740; PMCID: PMC3800423.
11. Rosetti E, Marcantonio R, Rossa C, Chaves E, Goissis G, Marcantonio E et al. Treatment of gingival recession: Comparative study between subepithelial connective tissue graft and guided tissue regeneration. *J Periodontol.* 2000;71:1441-1447.  
DOI: 10.1902/jop.2000.71.9.1441.  
PMID: 11022773.



12. Babu H, Gujjari S, Prasad D, Sehgal P, Srinivasan A. Comparative evaluation of a bioabsorbable collagen membrane and connective tissue graft in the treatment of localized gingival recession: A clinical study. J Periodontol. 2011;15: 301-428.

---

© 2023 Daruka et al.; This is an Open Access article distributed under the terms of the Creative Commons Attribution License (<http://creativecommons.org/licenses/by/4.0>), which permits unrestricted use, distribution, and reproduction in any medium, provided the original work is properly cited.

*Peer-review history:*  
*The peer review history for this paper can be accessed here:*  
<https://www.sdiarticle5.com/review-history/107427>