



Radiological and Histopathological Diagnosis of Pulmonary Mass according to CT-Guided FNAC and Core Biopsy

**Tariqul Islam^{a++*}, Syed Mohammad Sajjad Jalal^{b#},
Al Asma Ul Taslima^{b†}, Asaduzzaman^{c++},
Farhana Kamal Kumu^{b†} and Mst. Nadira Parvin^{d‡}**

^a Department of Radiology and Imaging, Sheikh Hasina National Institute of Burn and Plastic Surgery, Dhaka, Bangladesh.

^b Sheikh Hasina National, Institute of Burn and Plastic Surgery, Dhaka, Bangladesh.

^c Department of Histopathology, Sheikh Hasina National Institute of Burn and Plastic Surgery, Dhaka, Bangladesh.

^d Department of Epidemiology, Bangladesh University of Health Sciences (BUHS), Dhaka, Bangladesh.

Authors' contributions

This work was carried out in collaboration among all authors. The idea for the study, statistical analyses, and manuscript draft were generated by authors TI and MNP. Feedback on the statistical analyses and the draft manuscript was provided by all authors. The concluding manuscript was read and approved by all contributors. All authors read and approved the final manuscript.

Article Information

Open Peer Review History:

This journal follows the Advanced Open Peer Review policy. Identity of the Reviewers, Editor(s) and additional Reviewers, peer review comments, different versions of the manuscript, comments of the editors, etc are available here: <https://www.sdiarticle5.com/review-history/108845>

Original Research Article

Received: 10/09/2023

Accepted: 05/11/2023

Published: 09/11/2023

⁺⁺Associate Professor;

[#]Assistant Professor;

[†]Junior Consultant;

[‡]Senior Lecturer;

^{*}Corresponding author: E-mail: tariqul33@gmail.com;

ABSTRACT

Background: Computed Tomography (CT) guided core biopsy and Fine-needle aspiration cytology (FNAC) are crucial diagnostic procedures for swiftly assessing pulmonary masses. They play a pivotal role in expediting the diagnosis process of such lesions.

Aims: The primary objectives of this study were to evaluate the effectiveness of CT-guided core biopsy and FNAC in diagnosing pulmonary mass lesions and to compare their results with histopathological findings.

Methods: We conducted a prospective analysis of 45 patients who underwent CT-guided core biopsy and FNAC between June 2022 and August 2023. Subsequently, patients clinically indicated for further assessment underwent tru-cut biopsy.

Results: Among the 45 cases studied, the majority (60%) fell within the age group of 50-65 years, followed by 28.9% and 11.1% in the age groups of 15-45 and 65+, respectively. The mean age was 52.13 ± 13.91 years. Gender distribution showed that 67% of the respondents were male, while 33% were female. Regarding diagnostic procedures, 51.1% underwent core biopsy, 44.4% underwent FNAC, and only 4.4% opted for tru-cut biopsy. Radiological diagnoses indicated that 42.2% of the respondents had neoplastic masses, 24.4% exhibited metastatic lesions, 15.6% displayed consolidation, and 2.2% were diagnosed with tumors, tuberculosis, or chronic obstructive pulmonary disease (COPD). Histopathological results demonstrated that 33.3% of the respondents had carcinoma, 24.4% tested negative for malignant cells, 22.2% showed fibrosis, and 8.9%, 6.7%, and 4.4% were diagnosed with inflammatory lesions, pulmonary tuberculosis, and pleural effusion, respectively.

Conclusion: CT-guided core biopsy and FNAC emerged as straightforward, accessible, and dependable techniques for expeditiously establishing a tissue diagnosis of pulmonary masses while presenting minimal complications.

keywords: FNAC; radiological diagnosis; histopathological; pulmonary mass.

1. INTRODUCTION

Fine-needle aspiration cytology (FNAC) is a straightforward, reasonably safe, swift, and dependable technique for diagnosing pulmonary mass lesions, particularly when complemented by computed tomography (CT) scans. FNAC not only aids in distinguishing between benign and malignant lesions but also plays a pivotal role in characterizing lung cancer tumors. This characterization enables the prompt initiation of specific therapies, such as chemotherapy or surgery, without unnecessary delays. Over more than three decades, FNAC for pulmonary masses has gained worldwide recognition and acceptance, significantly enhancing the diagnostic utility of clinical cytology in diagnosing lung cancer [1].

FNAC has long been employed for the non-surgical confirmation of both primary and metastatic thoracic lesions. One notable advantage of FNAC is its ability to detect tumor types, such as small cell carcinoma and lymphomas, which are more appropriately managed with chemotherapy rather than surgical intervention. Multiple pieces of literature support

the assertion that CT-guided FNAC is a precise and sensitive method for diagnosing lung malignancies [2]. This procedure is associated with minimal discomfort, especially compared to biopsy for pulmonary mass diagnosis, and the potential major complication of pneumothorax is exceedingly rare [3].

The current study was undertaken to gain insights into the pathological spectrum of pulmonary lesions, establish correlations between cytological findings and histological features, and evaluate the accuracy of FNAC in assessing lung masses.

2. MATERIALS AND METHODS

This prospective study was conducted at the Department of Radiology and Imaging in a tertiary-level hospital in Dhaka for one year and three months, commencing in June 2022 and concluding in August 2023. The study comprised 45 patients with strong clinical suspicion and radiographic indications of lung masses.

To initiate the procedure, we cleaned the patient's skin using isopropyl alcohol or betadine, and then we administered local anesthesia up to

the pleural area. Lumbar Puncture (LP) needles were employed to collect specimens for cytological assessment. The angle relative to the skin's surface and the needle trajectory were carefully considered to avoid vital structures such as the aorta, heart, pulmonary vessels, and main or segmental bronchi. In cases involving cavitory lesions, the aim was to target their walls.

The CT table was repositioned, and the LP needle with the stylet was introduced into the thoracic region. Particular care was taken to traverse the visceral and parietal pleura with a single puncture, as multiple punctures increase the risk of pneumothorax. The patient was instructed to hold their breath during needle insertion and withdrawal. After the needle was positioned correctly, it was allowed to swing freely, reducing the risk of lung injury. The CT table was repositioned based on previously recorded positions, and cross-sectional images were acquired to confirm the needle's placement. Adjustments were made as necessary.

The CT table was again adjusted, and the aspiration process was carried out. Aspirated samples were used to create wet-fixed or air-dried smears stained with Papanicolaou (Pap) Hematoxylin and eosin. Cell blocks were prepared whenever feasible. Immediately following the procedure, a comprehensive thoracic scan was conducted to identify any procedure-induced pneumothorax or alveolar hemorrhage along the needle's path. In cases of minimal pneumothorax, the same needle was utilized to aspirate the pleural space. However, if larger pneumothoraces encompassing a substantial portion of the lung surface were

identified, consultations with specialists in pulmonary medicine or cardiothoracic surgery were sought, and management was determined according to their recommendations. Even in the absence of pneumothorax in the immediate post-procedure imaging, patients were advised to undergo a plain chest radiograph after a four-hour interval to identify potential complications with delayed onset.

3. RESULTS

In the 45 cases where CT-guided FNAC and core biopsy were performed, it was ensured that the obtained specimens were sufficient in quantity.

Table 1 illustrates that the majority of the respondents (60%) fell within the age group of 50-65 years, followed by 28.9% and 11.1% in the age groups of 15-45 and 65+, respectively. The mean age was calculated as 52.13±13.91 years.

Fig. 1 shows that 67% of the respondents were male and 33% were female.

Table 1. Distribution of the respondents by age category (n=45)

| Age category | Frequency | Percent |
|------------------|--------------------|---------|
| 15-45 | 13 | 28.9 |
| 50-65 | 27 | 60.0 |
| 65+ | 5 | 11.1 |
| Total | 45 | 100.0 |
| Mean ± SD | 52.13±13.91 | |

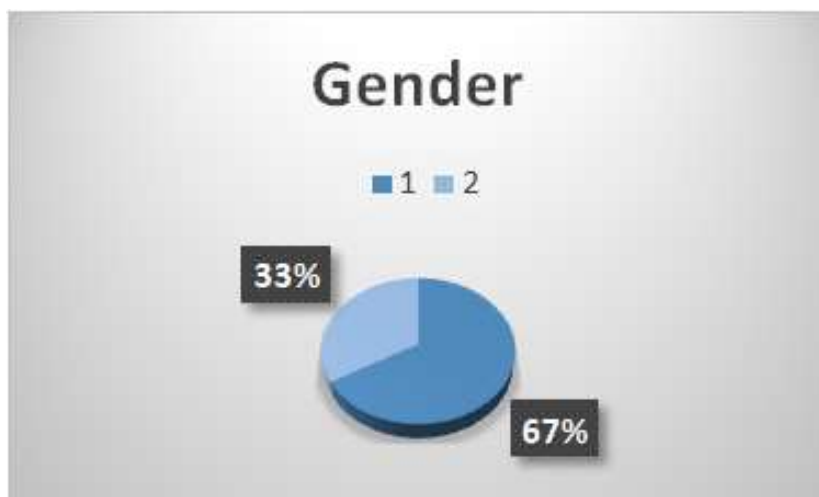


Fig. 1. Distribution of the respondents by gender (n=45)

Table 2 presents the information that most respondents (51.1%) underwent core biopsy, 44.4% opted for FNAC, and a mere 2.2% chose tru-cut biopsy.

Table 3 displays the radiological diagnoses made by the respondents. The study reveals that the majority of the respondents (42.2%) were diagnosed with neoplastic conditions, while 24.4% had metastatic lesions, 15.6% showed signs of consolidation, and 2.2% presented with diagnoses of tumors, tuberculosis (TB), and chronic obstructive pulmonary disease (COPD).

Table 4 delves into the histopathological diagnoses made for the respondents. The study indicates that the majority of respondents (33.3%) were diagnosed with carcinoma. In comparison, 24.4% tested negative for malignant cells, 22.2% exhibited signs of fibrosis, and 8.9%, 6.7%, and 4.4% were found to have inflammatory lesions, pulmonary tuberculosis (TB), and pleural effusion, respectively.

4. DISCUSSION

In modern evidence-based medical practice, using CT scans to evaluate lung masses offers patients the best chance of achieving an accurate diagnosis. CT-guided needle aspiration Cytology (FNAC) has emerged as a simple, safe, and rapid procedure for the pathological assessment of lung masses. It is recommended for obtaining bacteriological samples, staging patients with neoplastic conditions, and diagnosing mediastinal masses for tailored management [4, 5]. Bhatia et al. [5], Tan et al. [6], and Gouliamos et al. [7] have all emphasized the high sensitivity and accuracy of FNAC, considering it a vital tool in diagnostic procedures.

In our study, the sampling adequacy was found to be 93.3%. This level of adequacy is consistent with the findings of Holings et al. [8], who also reported adequacy in more than 90% of cases. Among the participants, 51.1% underwent core biopsy, 44.4% opted for FNAC, and only 2.2% chose tru-cut biopsy. Of these, 42.2% were diagnosed with neoplasms, 24.4% with metastatic lesions, 15.6% with consolidations, and 2.2% with tumors, tuberculosis (TB), and chronic obstructive pulmonary disease (COPD).

Histopathological analysis of the respondents revealed that 33.3% were diagnosed with carcinoma, 24.4% had negative results for malignant cells, 22.2% exhibited fibrosis, and 8.9%, 6.7%, and 4.4% had inflammatory lesions, pulmonary TB, and pleural effusion, respectively. Similar observations were made by Bandyopadhyay et al. [9], Tan et al. [6], and Gouliamos et al. [7], although Ahmad et al. [4] reported a higher incidence of malignancy at 78% and TB at 12%.

Thomas et al. [5] emphasized determining the cell type before planning treatment. This is especially important in the case of small cell carcinomas, as surgery is not typically the primary treatment option. It is also vital when surgery is contraindicated due to poor pulmonary function, extensive emphysema, or metastatic lesions.

Table 2. Distribution of the respondents by test procedure (n=45)

| Procedure name | Frequency | Percent |
|----------------|-----------|--------------|
| Core biopsy | 23 | 51.1 |
| FNAC | 20 | 44.4 |
| Trucut biopsy | 2 | 4.4 |
| Total | 45 | 100.0 |

Table 3. Distribution of the respondents by radiological diagnosis (n=45)

| Radiological diagnosis | Frequency | Percent |
|------------------------|-----------|--------------|
| Consolidation | 7 | 15.6 |
| Neoplasm | 19 | 42.2 |
| Metastatic lesion | 11 | 24.4 |
| Granulomatous lesion | 5 | 11.1 |
| Tumor | 1 | 2.2 |
| COPD | 1 | 2.2 |
| TB | 1 | 2.2 |
| Total | 45 | 100.0 |

Table 4. Distribution of the respondents by histopathological diagnosis (n=45)

| Histopathological diagnosis | Frequency | Percent |
|-----------------------------|-----------|--------------|
| Fibrosis | 10 | 22.2 |
| Carcinoma | 15 | 33.3 |
| Pulmonary TB | 3 | 6.7 |
| Inflammatory lesion | 4 | 8.9 |
| Negative for malignant cell | 11 | 24.4 |
| Pleural effusion | 2 | 4.4 |
| Total | 45 | 100.0 |

Therefore, an effort was made to classify the malignant lesions based on cell type. Tan et al. [6] reported a high incidence of adenocarcinoma in 49.4% of cases, primarily in peripheral locations. They also found squamous cell carcinoma in 12%, small cell carcinoma in 9.4%, and metastatic lesions in 8% of cases. Non-small cell carcinoma (NSCLC) accounted for 89.29% of cases. Distinguishing between NSCLC and small cell carcinoma (SCC) is critical, as many treatment decisions depend on this differentiation, as highlighted by Bhatia et al. [10].

Various CT findings in lung mass cases aided in distinguishing suspected benign neoplasms/lesions from malignant ones. The detection of calcification in 8.6% of malignant tumors aligns closely with Zerhouni et al.'s [11] findings, which reported a 7% prevalence of calcium in malignant nodules with a diameter of 6 cm or less. Air bronchogram was observed in 48.6% of malignant cases, which differs significantly from Kuriyama et al. [12]. FNAC plays a pivotal role as a valuable diagnostic tool and has been regarded as a primary modality alongside imaging for the expedited assessment of pulmonary mass lesions for several decades. [13]. The diagnostic precision of fine-needle aspiration cytology (FNAC) has been documented to exceed 80% for benign conditions and surpass 90% for malignancies. When employing CT guidance, it becomes feasible to biopsy virtually all lesions discernible on CT scans, irrespective of their dimensions or locations. CT facilitates precise needle placement in compact pulmonary lesions and deep mediastinal nodes while also providing clear visualization of vascular and cardiac structures, ensuring their safe avoidance during the procedure [14]. Another study reported that 72% of adenocarcinomas demonstrated air bronchograms. Our study observed Mediastinal lymphadenopathy in 28.6% of malignant lung masses, which contrasts with the findings of Webb et al. [15] who suggested that mediastinal lymph node metastases are seen in about 50% of patients with bronchogenic carcinoma.

5. CONCLUSION

The higher success rate observed in CT-guided FNAC can be attributed to its superior diagnostic accuracy, lower complication rate, and minimal tissue trauma. This study found that a majority of the respondents (51.1%) opted for core biopsy, while 44.4% chose FNAC, and only 2.2% underwent tru-cut biopsy. In this group of

individuals, the most prevalent diagnoses included neoplastic conditions (42.2%), followed by metastatic lesions (24.4%), consolidations (15.6%), and a smaller percentage with diagnoses such as tumors, tuberculosis (TB), or chronic obstructive pulmonary disease (COPD) (2.2%).

Regarding the histopathological diagnoses of the respondents, the study revealed that carcinoma was the most prevalent at 33.3%, followed by cases that tested negative for malignant cells (24.4%), those with fibrosis (22.2%), and a smaller proportion with inflammatory lesions, pulmonary TB, or pleural effusion (8.9%, 6.7%, and 4.4%, respectively). This information underscores the diverse range of conditions that can be accurately diagnosed using CT-guided FNAC, highlighting its utility in evaluating pulmonary masses.

6. LIMITATIONS

This study also had several limitations. Firstly, biopsy correlation was not available for all cases, which limited the ability to compare and confirm the accuracy of the diagnostic methods used. Additionally, follow-up of all patients could not be conducted since they were referred to a higher center for treatment, making it challenging to assess the long-term outcomes and effectiveness of the diagnostic procedures employed in this study.

CONSENT

Each patient provided written consent for their participation.

ETHICAL APPROVAL

All processes carried out in studies involving human participants conformed to the ethical standards established by the institutional research committee and adhered to the principles outlined in the 1964 Helsinki Declaration, including its subsequent amendments, or were in accordance with equivalent ethical standards.

ACKNOWLEDGEMENTS

The authors indicate their appreciation to the Department of Radiology and Imaging at Sheikh Hasina National Institute of Burn and Plastic Surgery in Dhaka for generously providing the dataset for this study.

COMPETING INTERESTS

Authors have declared that no competing interests exist.

REFERENCES

1. Ahmad M et al. Efficacy of bronchial wash cytology and its correlation with biopsy in lung tumours. JPMA. The Journal of the Pakistan Medical Association. 2004;54(1): 13-16.
2. Mullan C, et al. CT-guided fine-needle aspiration of lung nodules: Effect on outcome of using coaxial technique and immediate cytological evaluation. The Ulster Medical Journal. 2004; 73(1):32.
3. Cox JE. et al. Transthoracic needle aspiration biopsy: variables that affect risk of pneumothorax. Radiology. 1999;212(1): 165-168.
4. Ahmad S, Akhtar K, Hassan M. Zaidi. CT guided aspiration cytology in lung lesion-a feasible technique. Journal of Cytology. 2006;23(4):187-90.
5. Panda AK. et al. Correlation of CT findings of thoracic mass lesions with CT guided aspiration cytology. National Journal of Laboratory Medicine. 2017; 6(4):1.
6. Tan K. et al. Audit of transthoracic fine needle aspiration of the lung: Cytological subclassification of bronchogenic carcinomas and diagnosis of tuberculosis. Singapore Medical Journal. 2002;43(11): 570-575.
7. Gouliamos AD. et al. Computed tomography-guided fine needle aspiration of peripheral lung opacities. An Initial Diagnostic Procedure? Acta Cytologica. 2000;44(3):344-348.
8. Hollings N, Shaw P, Diagnostic imaging of lung cancer. European Respiratory Journal. 2002; 19(4):722-742.
9. Bandyopadhyay A, et al. CT guided fine needle aspiration cytology of thoracic mass lesions: a prospective study of immediate cytological evaluation. Indian Journal of Pathology & Microbiology. 2007;50(1):51-55.
10. Bhatia A, Singh N, Arora VK. A perspective on cytology of Lung Cancer. 2004;81-83.
11. Zerhouni EA, et al. CT of the pulmonary nodule: a cooperative study. Radiology. 1986;160(2): 319-327.
12. Song KS, et al., CT and MR imaging in staging non-small cell bronchogenic carcinoma. Journal of the Korean Radiological Society. 1995;32(4):579-586.
13. Mondal SK, Nag D, Parikh B, Shah M, Davara K. Computed tomogram guided fine-needle aspiration cytology of lung mass with histological correlation: A study in Eastern India. South Asian Journal of Cancer. 2013;2(01):014-8.
14. Singh J, Garg L, Setia V. Computed tomography (CT) guided transthoracic needle aspiration cytology in difficult thoracic mass lesions-not approachable by USG. Indian Journal of Radiology and Imaging. 2004;14(4).
15. Panda AK, Pradhan S, Mohapaapatra SS, Biswal R, Nisha S. Correlation of CT Findings of Thoracic Mass Lesions with CT Guided Aspiration Cytology. National Journal of Laboratory Medicine. 2017; 6(4):1.

© 2023 Islam et al.; This is an Open Access article distributed under the terms of the Creative Commons Attribution License (<http://creativecommons.org/licenses/by/4.0>), which permits unrestricted use, distribution, and reproduction in any medium, provided the original work is properly cited.

Peer-review history:

The peer review history for this paper can be accessed here:
<https://www.sdiarticle5.com/review-history/108845>