



Post-Streptococcal Nummular Keratitis: A New Clinical Entity

Said Iferkhass ^{a*} and Mohcine El Mhadi ^a

^a Department of Ophthalmology, Military Hospital, Moulay Ismail, Meknes, Morocco.

Authors' contributions

This work was carried out in collaboration among all authors. All authors read and approved the final manuscript.

Article Information

DOI: 10.9734/OR/2023/v18i6405

Open Peer Review History:

This journal follows the Advanced Open Peer Review policy. Identity of the Reviewers, Editor(s) and additional Reviewers, peer review comments, different versions of the manuscript, comments of the editors, etc are available here: <https://www.sdiarticle5.com/review-history/109055>

Case Study

Received: 12/09/2023

Accepted: 17/11/2023

Published: 20/11/2023

ABSTRACT

Introduction: Post-streptococcal nummular keratitis is an interstitial keratitis characterized by large infiltrates in the cornea. Its mechanism is probably immuno-allergic.

Patients and Methods: We report the first three cases of nummular keratitis related to a post-streptococcal infectious disease and we describe its clinical and tomographic aspect.

Results: This is a new clinical entity, characterized by multiple rounded, whitish lesions 0.5 to 3 mm in diameter, located in the stroma. These plaques are made of small infiltrates arranged radially giving a "spoke wheel" appearance. With time, these infiltrates having a greater tendency to confluence and the plaques take on a "currency" appearance resembling those described by "Demmer". Corneal sensitivity is preserved. Corneal optical coherence tomography (OCT) shows hyper-reflective lesions occupying the entire thickness of the stroma, with a "flying saucer" appearance respecting the corneal epithelium and endothelium with a tendency to confluence, particularly in the anterior stroma.

Discussion: This keratitis can be unilateral or bilateral and associated with an inflammatory syndrome, a high titer of ASLO, and a streptococcal infection.

Conclusion: Ophthalmologists faced with idiopathic nummular keratitis should consider post-streptococcal syndrome as a possible cause. A search for an increasing titer of ASLO and streptococcal infectious evidence establishes this association.

*Corresponding author: E-mail: iferkhasssaid@gmail.com;

Keywords: *Nummular keratitis; anti-streptolysin O; throat swab; post-streptococcal syndrome; pyogenic streptococcus.*

1. INTRODUCTION

Nummular keratitis is a corneal inflammatory process that is characterized by multiple sub-epithelial deposits [1]. The positive diagnosis appears simple on slit lamp examination, but the etiological diagnosis is more difficult.

It is necessary to distinguish between two clinical variant: the Dimmer's nummular keratitis and epidemiological nummular keratitis.

Dimmer's nummular keratitis is described as a slowly developing benign keratitis, usually unilateral. It is characterized by disk-shaped infiltrates in the superficial stroma, which later develop facets or depressions [2]. It is often confused with viral epidemic nummular keratitis. It is now known that (Dimmer) nummular keratitis is not a corneal disease but a founded sign in heterogeneous group of diseases, but never in post-streptococcal syndrome.

Through these cases, we report the first nummular keratitis linked to post-streptococcal disease, and describe its clinical features.

2. CASE PRESENTATION

Case 1:

A 10-year-old child followed for 4 years for bilateral and persistent nummular keratitis with frequent episodes of conjunctivitis; the diagnosis of adenovirus nummular keratitis was retained by his treating physician. In the event of an outbreak, the patient was put on topical corticosteroid, artificial tear and local antiviral treatment, but without regression of the corneal plaques.

The patient consults in our formation for slightly painful red eyes with photophobia and tearing. On examination, we note a visual acuity at 20/60 in both eyes, not improved with optical correction. The biomicroscopic examination shows a peri-keratic hyperemia with several whitish "coin" shaped lesions, sized 1.5 to 3 mm in diameter, localized in anterior stroma (Fig. 1 - A). With some rare epithelial infiltrates taking fluorescein. The anterior and posterior chamber appears normal. Ocular Tonus was normal in both eyes.

The child was treated by topical dexamethasone and artificial tears for one month and was asked for a checkup.

At the control, we note the disappearance of ocular surface irritability with persistent sub epithelial nummular plaques not taking fluorescein (Fig. 1-B).

Corneal OCT objectifying hyper-reflective lesions occupying the entire stromal thickness, respecting the epithelium and corneal endothelium with tendency to confluence especially in the anterior stroma (Fig. 2).

The biological assessment reveals an inflammatory syndrome with a sedimentation rate of 34 mm / 1 hour and a minimal anemia with hemoglobin at 11.8 g / 100 ml. Viral serology: herpetic, rubella, mononucleoside, acquired immunodeficiency and toxoplasmic, serology of Lyme and borreliosis returned negative. The ASLO title (anti-streptolysin O antibodies) achieved twice at an interval of two weeks returned high, respectively: 476.19ui / ml and 500ui / ml (reference range < 200 ui/ml). The throat swab revealed a streptococcus pyogenic infection.

We prescribed an antibiotic treatment adapted to the antibiogram containing Amoxicillin/clavulanic acid and artificial tears.

The evolution was spectacular, after 12 days, with disappearance of corneal nummular plaques in the left eye and persistence of a small plaque in the right one (Fig. 1B). The ASLO control title on the fifteenth day after treatment was 288 .0. + Ui / ml. A sinus-scan revealed mucosal thickening in the framework of the maxillary, ethmoidal and sphenoid sinuses related to chronic pan sinusitis.

OCT shows in the left eye a small residual anterior stromal lesion and some corneal pre-descemetic infiltrates.

In view of this inflammatory syndrome associated with the high ASLO title and the streptococcal infection, the diagnosis of post-streptococcal nummular keratitis was retained. The patient was treated by peni-retard with an injection every 21 days during 3months.

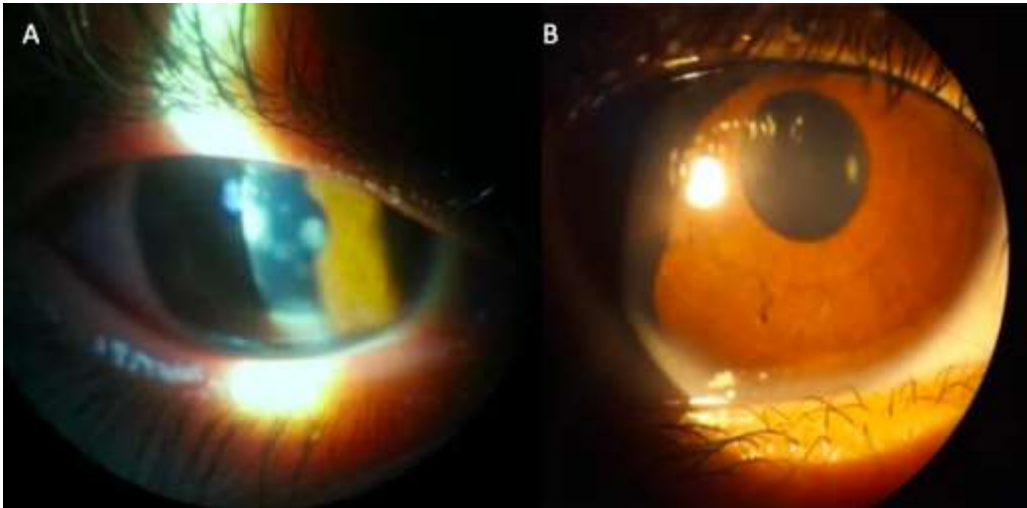


Fig. 1. Case 1: A: Large corneal opacities of different size, located in the visual axis with tendency to confluence; B: One month after treatment by co-amoxiclav: disappearance of corneal opacities

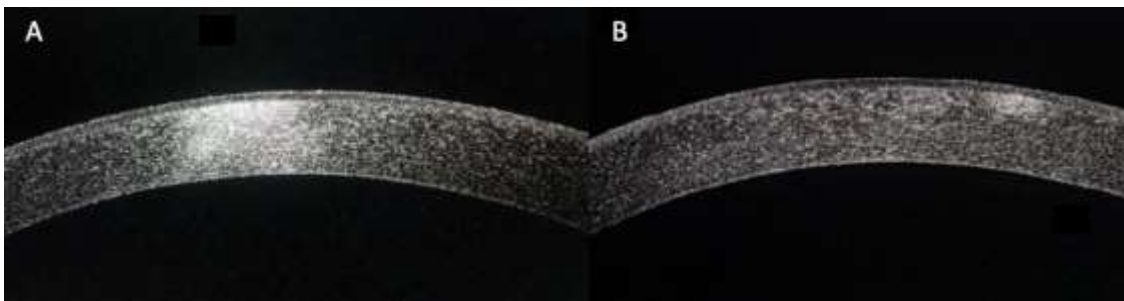


Fig. 2. Case 2: A: Corneal OCT objectifying hyper-reflective lesions occupying the entire stromal thickness, respecting the epithelium and corneal endothelium with tendency to confluence especially in the anterior stroma; B: Corneal oct on the 6th day of treatment showing regression of the lesion with persistence of a small opacity in the anterior stroma

Three months after the cut of peni-retard, the patient presented a recurrence. The Aslo title was 520ui / ml. the throat swab culture shows a bovine streptococcus sensitive to Amoxicillin/clavulanic acid; resistant to penicillin G, amoxicillin, erythromycin and cephalosporin first generation. Post-treatment control was satisfying with disappearance of corneal infiltrates.

A second recurrence was noted six months later with an aslo title of 607ui / ml and the isolation of entrococcus fucalis resistant to co-amoxiclav and amoxicillin, and sensitive for ciprofloxacin in the swab throat culture.

A third control, nine months later, objectified the presence of pyogenic streptococcus resistant to Amoxicillin/clavulanic acid and sensitive to erythromycin.

On a 47-month follow-up, no recurrence of corneal infiltrates was noted. The throat was negative and an ASLO title at 260.

Case 2:

A 6-year-old Girl having a history of repeated angina with an episode of scarlet fever treated a year ago, comes in consultation for a painful red left eye. On clinical examination we note: a preserved visual acuity with presence of a nodular episcleritis. The patient was put on local NSAI (Non-steroidal anti-inflammatory) for one month. After 15 days the patient returned for the same symptomatology with photophobia and tearing.

On examination, we note a visual acuity at 20/20 in the right eye 20/25 not improvable with optical correction at the left eye.

The biomicroscopic examination shows a conjunctival nodular episcleritis, with a corneal nummular infiltrate in the nasal side, of 1.5 to 2.5 mm in diameter not taking fluorescein, localized on the anterior stroma. These whitish plates are made of small infiltrates giving a wheel radius appearance (Fig. 3-A). Corneal sensitivity is preserved. The anterior and posterior chamber appears normal. Ocular Tonus is normal in both eyes.

The child was treated by topical dexamethasone and artificial tears for a month, and was asked for a checkup.

The biological assessment reveals an inflammatory syndrome with a sedimentation rate of 25 mm / 1 hour. Viral serology: herpetic, mononucleosal, rubiolic, toxoplasmic, syphilitic, and Lyme returned negative. The rheumatoid factor is normal. Parasitological examination of the stool is negative. Pulmonary radiology is normal. A sinus scan was requested but realized after treatment and returned normal.

The ASLO title achieved twice at an interval of two weeks returned high respectively 207ui / ml and 338ui / ml. The throat swab culture shows a multi-sensitive streptococcus pyogenic. The child was treated by adapted antibiotic treatment associated with artificial tears.

After 12 days, we notice the disappearance of nummular corneal plaques in the left eye (Fig. 3 -

B). The ASLO control title, on the fifteenth day after treatment was 195 .0. + Ui / mi, and without any recurrence after 33 months of decline.

Case 3:

A 8-year-old girl with a notion of recurrent angina, consults for bilateral painful red eye associated with tearing and photophobia. the patient had already been put on two occasions, a month and a half previously, under antibiotic and topical non-steroidal anti-inflammatory treatment, but without improvement.

On examination, we note a visual acuity at 20/25 in both eyes, which cannot be improved with its optical correction.

At the slit lamp we note the presence of diffuse and bilateral large infiltrates, (0.5 to 3mm in diameter), of stromal location, not taking fluorescein.

OCT shows the presence of infiltrates occupying the entire thickness of the stroma with a "cockade" or "flying saucer" appearance (Fig. 4). The patient was put on Amoxicillin/clavulanic acid for 10 days with artificial tear.

The evolution was marked by the disappearance of the plaques without recurrence over a 12-month follow-up.

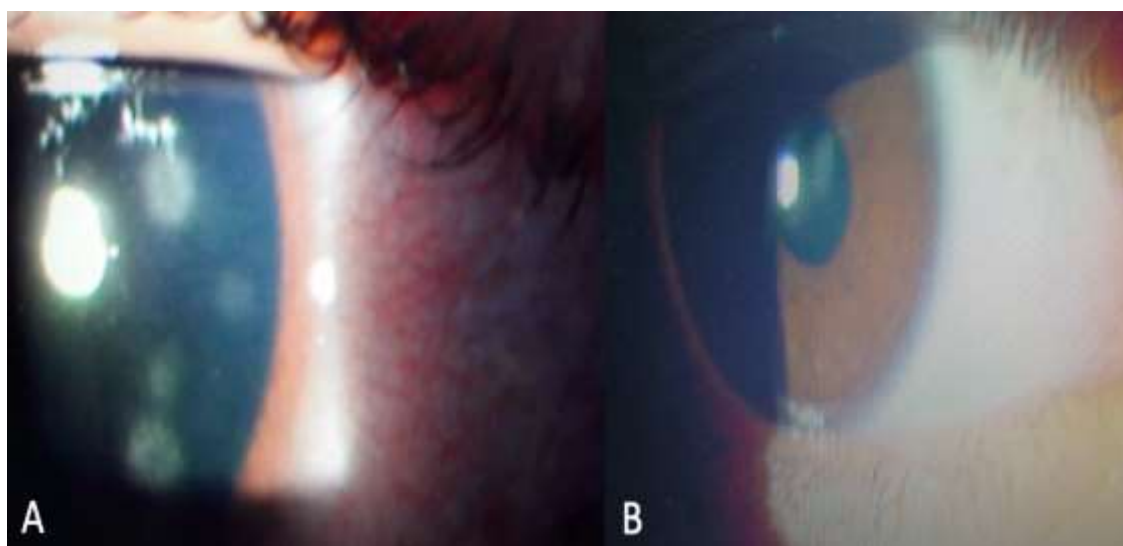


Fig. 3. Case 2: A: Conjunctival nodular episcleritis, with a corneal nummular infiltrate in the nasal side, of 1.5 to 2.5 mm in diameter, localized on the anterior stroma; These whitish plates are made of small infiltrates giving a "wheel radius" appearance; B: Disappearance of lesions after 12 days of treatment




Fig. 4. Case 3: A: Wide stromal infiltrates (0.5 to 3mm in diameter); B: Presence of infiltrates occupying the entire thickness of the stroma with a “cockade” or “flying saucer” appearance; C: Same lesions in the other eye

3. DISCUSSION

The term "nummular keratitis" was first used by von Stellwag in 1889 [3] to describe a form of keratitis. The disease was usually bilateral. It is characterized by a relatively acute onset and the occurrence of multiple, round, sharply delineated, grayish or yellowish white areas, about 0.5 to 1.5 mm. in diameter, throughout the various layers of the cornea.

These areas are often superficial and had tend to break down and ulcerate. They marked general inflammatory reaction. The course of this disease is fast: usually healed in twelve to fourteen days with no residue.

During the same month, von Reuss [4] published the report of his cases under the title "Keratitis maculosa."

In the same year, Fuchs [5] described "Superficial punctate keratitis," recorded 36 cases which developed between the 3rd and 14th day of a nummular keratitis with infiltrates of 0.5mm and Some of them increased in size by the coalescence of neighboring foci. All of these lesions were located just beneath Bowman's membrane. He also found corneal hypoesthesia and anesthesia in some patients. In 14 instances, Fuchs found that the lesions remained for, from six months to one year. He stated that one could be sure that the lesions were gone only after the lapse of one to two years.

In 1905, Dimmer [2] reported 4 cases of a unilateral peculiar keratitis. He decreed these features to designate a disease which appears different from that of VON Stellwag. It is usually unilateral, starting with pain, photophobia and lacrimation, without secretion, and characterized by the formation of peculiar infiltrates in the cornea. It is mostly laying in the middle layers

and usually reach the size of 1 to 1.5 mm. The margins are sharp; there is a tendency to confluence. It may be completely reabsorbed, or form round, umbilicated ulcers.

In the first case reported by Dimmer, there was a bilateral affection with central, superficial corneal macular lesions measuring 0.5 to 1 mm. in size. The second patient had a unilateral affection, with similar lesions just inside the limbus. There had been no preceding conjunctival inflammation in either case. The disease in the last two cases was preceded by an injury. The specificity of the disease in those two cases is somewhat doubtful.

Case 3 was followed for an acid projection in the right eye. Redness, photophobia and blurry vision resulted and persisted for some time. There was conjunctival and ciliary injection with the formation of five gray, round, superficial spots in the outer half of the cornea. One of these spots was ulcerated. The patient was only followed for about three weeks.

Case 4 was followed for lime projection into the eyes. Six weeks later, there was blurred vision, pain, slight photophobia, and tearing. The conjunctiva was markedly hyperemic. The cornea of the right eye showed six gray spots of 0.5 to 1 mm. in diameter and an infiltrate of 4 by 3 mm more in diameter.

These were white, opaque, superficial, and slightly vascularized. One lesion was ulcerated. The patient was lost in three weeks; there had been little change in his condition.

Dimmer's cases of keratitis nummularis are given in some detail in order to show the similarity of the disease in cases 1 and 2 to the condition noted in subsequent reports of "superficial punctate keratitis".

The association of the name Dimmer with the term "nummular keratitis" was reported by Aust in 1933 [6] and Salzmann in 1934 [7], who reported other cases like those described by Dimmer. Aust [6] reported 27 cases. He stated that the condition in these cases, and the cases reported by Salzmann were identical to the disease reported by Dimmer and proposed the name "keratitis nummularis (Dimmer)", adding the name of Dimmer to avoid confusion with the disease described by von Stellwag in 1889, which he said was entirely different.

Aust's description of the disease is detailed. He described it as a seasonal disease, reaching its peak in August and September, occurring mainly in young agricultural workers and generally being unilateral. In 7 of 27 cases of Aust, there was a history of previous trauma. The onset of the disease was slow, and in most cases the patient sought medical attention four to six weeks after the onset of symptoms.

Salzmann [7] reported a further series of 82 cases of "nummular keratitis, in 24 of his cases there was a history of preceding trauma, and in 14, a history of preceding colds.

Salzmann and Aust mainly examined the corneal diseases which corresponded to the last two cases described by Dimmer and which are very similar to herpetic keratitis. Actually, thought Salzmann himself decided on a relationship with herpetic keratitis, which was already expressed in the title of his study on nummular keratitis, namely: "Keratitis following herpes" [8].

Next, after the cases of Salzmann and Aust, many cases of "Dimmer" nummular keratitis were reported by Szekeley [9], Sacha [10], Jese [11] and Pillat [12].

The disease in their patients appeared with minimal conjunctival symptoms, photophobia and tearing. The descriptions and drawings of the corneal lesions of their patients are identical to those observed in other epidemics of keratoconjunctivitis

Alan C. Woods [13] suggest that the majority of cases described as cases of nummular keratitis, especially those with an epidemic tendency, were in fact cases of epidemic keratoconjunctivitis.

Pillat [12] tried to highlight the morphological characteristics distinguishing these two entities.

The foci in NKD, are larger, whiter in color, smaller in number and more tendency to confluence, than those in epidemic nummular keratitis. He introduced the preservation of corneal sensitivity and absence of conjunctivitis as additional criteria to differentiate Dimmer's keratitis from epidemic keratitis.

However, Valenton [14] in a series of 34 patients with characteristic nummular opacities simulant to the clinical entity by Dimmer, reported the tendency of the centrally located nummular opacities to involve the deep corneal stroma and to coalesce forming a typical central disciform keratitis similar to herpes simplex disciform keratitis, this was present in 38 % of the cases. he noted that corneal sensitivity was normal. However, he said nothing about the onset of the disease and when the sensitivity was determined.

Finally, O. P. van Bgsterveid and al. [15] noticed that corneal sensitivity can be normal in some cases of herpetic keratitis with infiltrates and ulcers. In this case that it is not possible to clinically differentiate between Dimmer's nummular keratitis and viral keratitis. Some authors [14-16] reported cases of nummular keratitis with only a very mild degree of conjunctivitis or none at all. Others, [17] suggest that, epidemic keratoconjunctivitis, nummularis keratitis (Dimmer), Beal's papillary form of conjunctivitis, and some forms of disciform keratitis should be included in one disease entity and Nummular keratitis (Dimmer) does not play a diagnostic part in ophthalmology, as we are not dealing with a nosological entity [15].

In our case, the first patient had chronic nummular keratitis characterized by multiple discoid opacities with subepithelial infiltrates and episodes of conjunctival inflammation concomitant with punctual rupture of the lesions. There were however some differences from the nummular keratitis of "Dimmer". Corneal lesions did not have a strong tendency to develop central necrosis or depressions or facets, which were apparently fairly characteristic this corneal disorder.

Moreover, corneal OCT objectifying hyper-reflective lesions occupying the entire stromal thickness, respecting the epithelium and corneal endothelium with tendency to confluence especially in the anterior stroma, what differentiates this entity from an endemic keratitis contracted by subepithelial corneal infiltrates.

The corneal sensitivity was preserved and the bilateral lesions have persisted 4 years despite repeated treatment with topical steroids and topical artificial tears.

For the second patient, the early diagnosis at the start of lesions installation phase, allowed us to specify their clinical aspect to differentiate them from that of dimmer.

the ocular involvement was unilateral with white discoid plaques of 0.5 and 2.5 mm in diameter; located at the level of the anterior stroma. The lesions are somewhat peripheral associated with episcleritis. They are made of multiple small infiltrates arranged in stripe giving an appearance in wheel radius.

This aspect was observed in the third patient but was less marked clinically. However, corneal OCT showed stromal lesions with a “cockade” appearance for recent lesions and “flying saucer” lesions for relatively old lesions.

In our patients this keratitis is associated with a post-streptococcal syndrome defined by the inflammatory syndrome, high ASLO title, pyogenic streptococcus in the throat.

Several features must be considered before attributing the etiology of post-streptococcal syndrome to this keratitis.

The Epstein-Barr [18], Herpes simplex [6-17-19], herpes zoster [20] virus, and adenovirus [21] can cause a nummular interstitial keratitis. In our cases the normal corneal sensitivity, the failure of antiviral local therapy and the negative viral serology were against the viral etiology.

In the literature, five isolated and sporadic cases of nummular keratitis related to brucellosis [13] was described. In these entities, the corneal opacities are often unilateral, very large, located in the visual axis, and typically develop a central depression as they resolve, which corresponds to the description of Dimmer. Our patients do not live in a ferme, and the Brucella serology was negative.

Nummular keratitis may have associated with other pathology such as: sarcoidosis [22-23], tuberculosis [22]. syphilis [22], ocular amebiasis [24], microfilaremia [25], onchocerciasis [26] and Hyper-IgD Syndrome [27].

Tuberculosis was eliminated after a normal laboratory tests (Tuberculosis sputum test and

QuantiFERON) and lung x-ray. The syphilitic serology was negative.

In our patients, the nummular keratitis was associated to a streptococcal infection. The complete resolution of corneal infiltrates with adapted antibiotics against pyogenic streptococcus, after a viral unsuccessful treatment suggests that streptococcus is probably directly or indirectly responsible of this corneal disease.

B Hemolytic streptococcus A (SGA) is a human pathogen that causes significant morbidity and mortality worldwide. Repeated SGA infection may be responsible for several immune-related complications: cardiac, articular, dermatologic, renal, cerebral and ocular [28-21]. They often appear 7 to 35 days after the infection and are named by post-streptococcal syndrome (PSS). Concerning the eyes complications, the post-streptococcal uveitis (PSU), is usually described as bilateral, anterior and non-granulomatous [29-30-22-23]. It is also posterior in 37.5 to 50% of cases [29-30-22-23], characterized by a diversity of lesions [31-24]: papillitis, papillo-phlebitis, necrotic or non-necrotic retinitis, neuro-retinitis, choroiditis, multifocal choroiditis, retinal serous detachment, and cystoid macular edema. Corneal involvement is rare since it is reported only in two cases [32-33-25-26]. It is a small marginal stromal infiltrate associated with anterior uveitis. However; no cases of nummular keratitis have been reported.

To our knowledge, our three cases are the first cases reported in the literature of nummular keratitis linked to post-streptococcal disease.

These corneal plates, 1.5 to 2.5 mm in diameter, do not take fluorescence, and are located at the level of the anterior stroma. They are made of small radial infiltrates with a clear center giving these plates a ray wheel appearance.

Over time, these infiltrates are more prone to confluence, and the plates take on a “patch” appearance similar to that described by “Dimmer”. These plates increase in diameter, varying in size from 0.5 mm to 3 mm or more. they are whitish in color, with a tendency to coalesce between them. The evolution is torpid and chronic without necrosis or vascular call with episodes of punctured rupture of the epithelium responsible of redness, photophobia and tearing. AS-OCT shows the presence of the hyper-reflective lesions occupying the entire thickness

of the stroma with a “cockade” for recent lesions and “flying saucer” for relatively old lesions. In the chronic phase, the lesions respect the epithelium and corneal endothelium with tendency to confluence especially in the anterior stroma.

The treatment of this entity is based mainly on antibiotic therapy oriented by an antibiogram until eradication of the germ which is the only guarantee of obtaining a cure. Indeed, recurrent forms are possible. These can be explained by a new streptococcal exposure or preexistence of several types of streptococcal attack as is the case of our second patient, or the persistence of a pyogenic streptococcus reservoir hence the interest of repeat the samples from the throat and ask for a sinus-scan.

Although the exact pathophysiological mechanism of PSS is still unknown, most authors propose a molecular mimicry hypothesis between bacterial antigens and auto-antigens leading to auto-immunity [28-31-34].

The peptidoglycan-polysaccharide complexes in the wall of streptococcus bacteria have many properties that can activate phagocytic cells and involve the complement cascade to cause tissue injury [35]. The low biodegradability of PG-PS [36] helps to explain how this bacterial debris persists in tissues and act as a chronic stimulus. PG-PS also has an antigenic role, and therefore its chronic presence in the tissue could lead to the production of immune complexes and to an immunopathology [35].

The specific antibodies against these proteins would act against other proteins of the human body, and become auto-antibodies [31]. In this way, cellular and humoral immunity develop PSS.

Matoba and his collaborators [37] deem that the capsule of the streptococcus can have an important role in the evolution of some clinical signs such as crystalline keratopathy.

Another component capable of activating the immune system is the streptococcus carbohydrate enolase enzyme, whose function is to bind to plasminogen and thus allows tissue destruction once the infection has occurred [31].

4. CONCLUSION

Poststreptococcal nummular keratitis is a new clinical entity, characterized by multiple rounded,

whitish lesions (0.5 to 3 mm in diameter), localized in the anterior stroma.

Facing idiopathic nummular keratitis, Ophthalmologists should consider post-streptococcal syndrome as a possible cause. The search for an increasing title of ASLO and streptococcal infectious evidence establishes this association.

CONSENT

As per international standards, parental written consent has been collected and preserved by the author(s).

ETHICAL APPROVAL

As per international standard or university standard written ethical approval has been collected and preserved by the author(s).

COMPETING INTERESTS

Authors have declared that no competing interests exist.

REFERENCES

1. Arenas E, Mieth A, D. Muñoz Combined intrastromal injection with ganciclovir and depot betamethasone for the management of nummular keratitis: case series. *Archives of the Spanish Society of Ophthalmology*. 2019;94(7):347-351.
2. Dimmer F. Nummular Keratitis and Its Related Corneal Inflammation, *Ztschr. F. Augenh.* 1905; 13:621-635.
3. Von Stellwag K. A Peculiar Form of Corneal Inflammation, *Wien. klin. Wchnschr.* 1889;2:613-614.
4. Reuss A. Macular keratitis. *Vienna. kilon. Wok.* 1889;2:665-666.
5. Fuchs E. Keratitis punctata superficialis. *Vienna. klin. Woch.* 1889;2:837-841.
6. Aust O. Keratitis Nummularis (Dimmer), *Arch. f. Ophth.* 1933;129:576-595.
7. Salzmann M. Keratitis Nummularis Dimmer, *Arch. f. Ophth.* 1934;132:399-420.
8. Wright RE. Superficial punctate keratitis. *Brit. Jour. Ophth.* 1930;14:257-291:595.
9. Szekeley J. Keratitis nummularis (Dimmer). *Arch. f. Ophth.* 1935;134:184-188.
10. Sacha A. Keratitis nummularis (Dimmer). *Arch. f. Ophth.* 1933;131:102-107.

11. Jese L. Nummular keratitis. *Klin. M.f. Augenh.* 1936;96:219–226.
12. A.Pillat MD. The differential diagnosis of nummular keratitis (dimmer) and epidemic keratoconjunctivitis. *American journal of ophthalmology.* April. 1957;43(4):58-63.
13. Alan C, Woods MD. Nummular keratitis and ocular brucellosis. *Arch Ophthalmol.* 1946;35 (5):490-508.
14. Mario J, Valenton MD. Deep stromal involvement in Dimmer's nummular keratitis. *American journal of ophthalmology* December. 1974;78(6):897-901.
15. Van Bgsterveid OP, Obster R. Keratitis nummularis Dimmer, Morbus dubius. *Klin Monatsbl Augenheilkd.* 1983;183(9):169-172.
16. Meissner W. Epidemic of nummular keratitis (Dimmer) in Bavaria. *Munich med. Woch.* 1938; 85:1939–1940.
17. Michael J. Hogan MD, Joseph W, Crawford MD. Landmark Reprint. Epidemic keratoconjunctivitis* (Superficial Punctate Keratitis, Keratitis Subepithelialis, Keratitis Maculosa, Keratitis Nummularis) With a Review of the Literature and a Report of 125 Cases. *Am J Ophthalmol.* 2018;190:xxix-xlii. DOI: 10.1016/j.ajo.2018.03.
18. Michael Pinnolis MD, James P. Mcculley MD, Jeffrey D, Urman, MD. Nummular keratitis associated with infectious mononucleosis. *American journal of ophthalmology.*1980;89:791-794.
19. Rados A. Epidemic kerato-conjunctivitis and viral diseases of the eye. *Archives of Ophthalmology.* 1944;32(4):308–329.
20. Ronald j. Marsh and Matthew cooper: ophthalmic herpes zoster eye. 1993;7:350-370.
21. Anand R. Deepshikha Solanki, Chahveer Singh Bindra, Vivek Som. Adenoviral Keratitis: A Study. *Journal of Evolution of Medical and Dental Sciences.* 2015;4(46):7887-7894.
22. Grayson M. *Diseases of the Cornea.* St. Louis CV. Mosby Co. 1979;79(81):237-483.
23. Neil Lucchese MD, Howard Tessler MD. Keratitis associated with chronic iridocyclitis. *American journal of ophthalmology.*1981;92:717-721.
24. Thomas Reinhard, Gisbert Schilgen, Michael Steinert, Jörg Hacker.: Nummular infiltrates in Acanthamoeba keratitis. *Acta ophthalmologica scandinavica.* 2003;81(5): 541-543.
25. Lucas Monferrari, Monteiro Vianna, Marilaine Martins, Marcos Jacob Cohen, Jacob Moyses Cohen, Rubens Belfort, Mansonella ozzardi.: Corneal lesions in the Amazon: a cross-sectional study. *BMJ Open.* 2012;2:e001266. DOI:10.1136/bmjopen-2012-001266.
26. Sarkies JWR. Ocular onchocerciasis* *Brit. J. Ophthalmol.* 1952;36:81-99.
27. Courtney L, Kraus and Susan M, Culican.: Nummular keratopathy in a patient with Hyper-IgD Syndrome. *Pediatric Rheumatology.* 2009;7:14 DOI:10.1186/1546-0096-7-14
28. Anna Henningham; Timothy C. Barnett Peter G. Maamary; Mark J. Walker.: Pathogenesis of Group A Streptococcal Infections. *Discov med* –May. 2012;13(72):329-342.
29. Ur Rehman S, Anand S, Reddy A, Backhouse OC, Mohamed M, Mahomed I, et al. Poststreptococcal syndrome uveitis: a descriptive case series and literature review. *Ophthalmology.* 2006;113(4):701–6.
30. Christopher Tinley, Lourens Van Zyl, Rhian Grotte.: Poststreptococcal syndrome uveitis in South African children. *Br J Ophthalmol.* 2012;96:87e89.
31. Valentín Huerva and Lorena Villalba.: Poststreptococcal uveitis. *Med Clin (Barc).* 2008;131 (9):344-8.
32. Nathaniel Nataneli.: Poststreptococcal kerato-uveitis associated with group C streptococcus pharyngitis. *Clin Ophthalmol.* 2011;5:1257–1259.
33. Valentin Huerva M. Carmen Sanchez and Luisa M. Canto.: Post-streptococcal syndrome uveitis. *Acta Ophthalmologica Scandinavica.* 2007;85(2):223-224.
34. Phillips GN Jr, Flicker PF, Cohen C, et al.: Streptococcal M proteins: alpha helical coiled coil structure and arrangement on the cell surface. *Proc Natl Acad Sci U S A.* 1981;78:4689.
35. Alvin Wells, Geero Pararajosegaram, Marsha Baldwin, Chang-Hsu Yang, -f-Mark Hammer and Alvin Fox.: Uveitis and Arthritis Induced by Systemic Injection of Streptococcal Cell Walls. *Investigative ophthalmology 6 visual science* – June. 1986;6(27):921-925.

36. Matoba A, O'Brien T, Wilhemus K, Jones D. Infectious crystalline keratopathy due to streptococcus pneumoniae. *Ophthalmology*. 1994;101:1000-1004.
37. Eisenberg R, Fox A, Greenblatt J, Anderle S, Cromartie W, and Schwab J: Measurement of bacterial cell wall in tissues by solidphase radioimmunoassay. Correlation of distribution and persistence with experimental arthritis in rats. *Infect Immun*. 1982.38:127.

© 2023 Iferkhass and El Mhadi; This is an Open Access article distributed under the terms of the Creative Commons Attribution License (<http://creativecommons.org/licenses/by/4.0>), which permits unrestricted use, distribution, and reproduction in any medium, provided the original work is properly cited.

Peer-review history:

The peer review history for this paper can be accessed here:
<https://www.sdiarticle5.com/review-history/109055>