



# Takotsubo Cardiomyopathy in Patients with Myasthenia Gravis, 2023

Naba Mahdi Sheikh Musa

Sudan University of Science and Technology, Omdurman, Sudan

Email: nabamahady@gmail.com

**How to cite this paper:** Musa, N.M.S. (2024) Takotsubo Cardiomyopathy in Patients with Myasthenia Gravis, 2023. *Open Access Library Journal*, 11: e10948. <https://doi.org/10.4236/oalib.1110948>

**Received:** October 31, 2023

**Accepted:** January 1, 2024

**Published:** January 4, 2024

Copyright © 2024 by author(s) and Open Access Library Inc.

This work is licensed under the Creative Commons Attribution International License (CC BY 4.0).

<http://creativecommons.org/licenses/by/4.0/>



Open Access

## Abstract

**Background:** Myasthenia gravis associated with takotsubo cardiomyopathy (broken heart syndrome) is a rare condition but a life threatening. Broken heart syndrome is reversible apical ballooning like dilation of left ventricle related to stress. **Method:** This is a systematic review of previously reported cases of patients with myasthenia gravis developed takotsubo cardiomyopathy, worldwide 2003-2023, pubmed and google scholar, to analyze and find out the definitive treatment and ways of prevention from it. **Results:** Cases reported previously indicate that takotsubo cardiomyopathy developed in patients with myasthenia gravis during myasthenic crisis in the second day of admission with worsened dyspnea, low ejection fraction, short PR - interval, QT-prolongation and T wave inversion on electrocardiogram; most cases have been occurred in female, and most cases were of age of more than 15 years, especially in presence of thymectomy due to malignant thymoma; some cases have been associated with diabetes mellitus and low frequency smoking history; most cases have been improved with anticholinergic (pyridostigmine) and plasma exchange, NSAIDs (prednisone), and immunoglobulines for myasthenia gravis, dobutamine for takotsubo cardiomyopathy, and ventilator support for respiratory events from myasthenia gravis. Inotropes and vasopressor have been led to poor outcomes; it has been hypothesized that excess catecholamin stimulation cause stress on cardiac muscles presented as takotsubo cardiomyopathy (stress related cardiomyopathy); most cases have been occurred in European and American decent. **Conclusion:** As physical and emotional stress cause takotsubo cardiomyopathy, they are also a risk factor for developing myasthenia gravis, so avoiding stressful conditions is a prevention, and monitoring cardiac manifestation in myasthenic crisis's patients with cardiac MRI is very important.

## Subject Areas

Cardiology

---

## Keywords

Malignant Thymoma, Myasthenia Crisis, Apical Ballooning Like Dilation, Broken Heart Syndrome, Cardiac MRI

---

## 1. Background

Myasthenia gravis is a neuromuscular disease, occurring due to autoimmune destruction of post synaptic acetylcholine receptor, resulting in fluctuating and fatigable proximal muscle weakness, including ocular (diplopia, ptosis), bulbar (dysphagia and dysarthria) and respiratory muscles in myasthenic crisis. It exacerbates by: 1) Medication as aminoglycosides, fluoroquinolones, beta blockers, magnesium sulfate, penicillamine and neuromuscular blocking agents. 2) Physiologic stress as pregnancy, surgery (especially thymectomy). 3) Infections.

Diagnosis is made by ice pack test (beside), acetylcholine receptor antibody (highly specific) and CT scan of chest (thymoma). Treatment is done by acetylcholinesterase inhibitors (pyridostigmine) immunotherapy (corticosteroids, azathioprine) and thymectomy. Exacerbation of symptoms leads to myasthenic crisis, which presents with dyspnea, respiratory compromise (which is the most common cause of death in myasthenia gravis) and increased oropharyngeal weakness. Patients in this state are treated with intubation for deteriorated respiratory status and plasmapheresis or intramuscular immunoglobulines and corticosteroids.

Takotsubo cardiomyopathy (stress induce cardiomyopathy) is a cardiac systolic dysfunction, occurs in postmenopausal women due to physical or emotional stress, present with chest pain mimicking myocardial infarction, decompensated heart failure, moderate troponin elevation. Electrocardiogram shows ischemic changes in pericardial leads. Diagnosis is made by: 1) Catheterization shows no obstructive coronary artery disease as in [1]. 2) Echocardiograph shows left ventricular ballooning like dilation, apical hypokinesis and basilar hyperkinesis. It resolves in several weeks with supportive treatment.

Patients with myasthenia gravis especially during myasthenic crisis may develop a takotsubo cardiomyopathy. The main aim is to generalize the knowledge about association of takotsubo cardiomyopathy with myasthenic crisis, and the importance of controlling myasthenia gravis to prevent these complications.

## 2. Methods

The main aim of this study is to find the definitive treatment of this case by reviewing of all previously reported cases and systematic review of previous cases reported in pubmed and google scholar in years from 2003 to 2023.

**Data collection and data analysis:** All data have been collected from previous cases in years from 2003- to 2023 from pubmed (advanced search) and google scholar (advanced search), without exclusion of any case reported during this period of time.

Analysis of data was done by excel software.

### 3. Results

22 reported cases out of 28 have been analyzed (**Table 1**). 13 of these cases have been occurred among female, nine of them were died. Nine of these cases occurred among male, two of them were died (one induced because of cancer as in [2]). Most of cases have been occurred in presence of thymectomy because of malignant thymoma as in [2] [3] [4] [5] [6] and most of them have antibody against striated muscles (anti titin, anti ryanodine, and anti kv 1.4 anti bodies) as in [7]. All over it's a rare condition but some patients can die, unless controlled well. Takotsubo cardiomyopathy in patients with myasthenia gravis emerges as worsening dyspnea also can be presented without dyspnea as in [8]. Chest pain, respiratory failure as in [9] elevated troponin level (same as myocardial infarction) as in [10]. Creatine kinase, and CK-MB isoenzymes as in [4] and [10], ST elevation firstly as in [3], followed by T wave inversion and QT prolongation in 12 lead on electrocardiogram as in [10] [11] [12] [13], there is no obstructive coronary arteries on angiogram as in [1] [14] [15], and left ventricular ballooning like dilation as in [2] and [12], apical akinesia as in [13] [15] [16] [17] [18] basal hyperkinesis and left ventricular dysfunction in ventriculography as in [12] [14] [18], and reduced ejection fraction (equal or less than 45%) on transthoracic echocardiograph as in [8] [10] [12] [13] [15], most of them have been occurred after thymectomy, takotsubo cardiomyopathy among these patients has been hypothesized to be occurred due to excess catecholamine stimulation as in [17] [19] which induces a stress on cardiac muscles, also it can be occurred during plasmapheresis as in [20] and [21], and it may be repeated, also it can be occurred after treatment with human immunoglobulin perfusion as in [22], so close monitoring with cardiac MRI as in [23] and echocardiograph is required to avoid the complications, and exacerbated myasthenia gravis present as generalized weakness, dysphagia, dysarthria, disabling myalgias, and hyperkalemia as in [4] fatigue as in [24], shortness of breath and respiratory distress, some cases have been developed as bilateral facial weakness, unilateral ptosis as in [13] and [19], and blepharoptosis as in [2] and [16]. History of diabetes mellitus, hypertension, atrial fibrillation as in [25] and smoking have been found in minority of

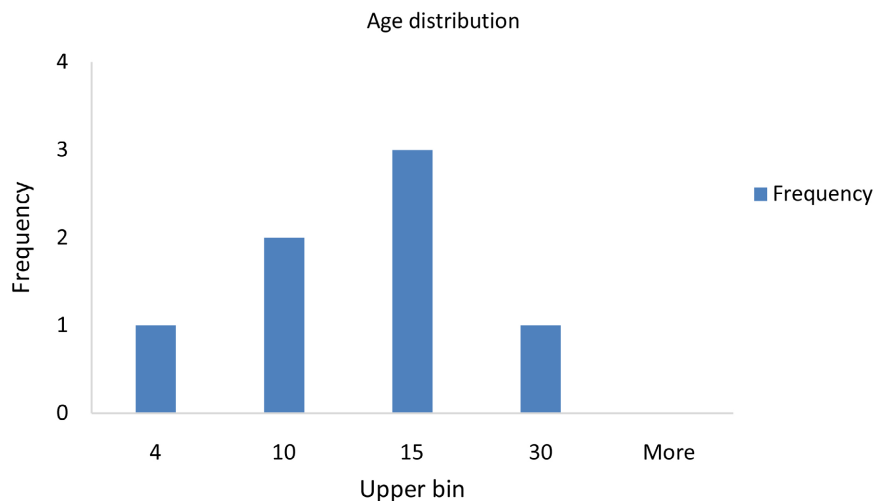
**Table 1.** Data analysis of samples.

Sample	Number
Reported cases	22
Female	13
Male	9
All cases	28
Live cases	13
Dead cases	9
Dead male	2
Dead Female	7

the cases, most cases have been cured by anticholinergic (pyridostigmine), NSAIDs (prednisone), immunoglobulines, plasma exchange as in [1] and ventilatory support for mytheniccrisis as in [4] and [26], and dobutamine for takotsubo cardiomyopathy, vasopressor and inotropes have been led to a poor outcomes including death and intractable heart failure as in [12]. Broken heart syndrome have been occurred on second day of admission with mythenia gravis as in [27] and [28], vital signs have been demonstrated normal blood pressure without tachycardia or bradycardia as in [12].

#### 4. Discussion

Most of the cases have been occurred among patients from Western pacific, American and European regions as in [27], and there were no cases reported from African and Eastern Mediterranean regions. Most of the cases have been occurred among female (Table 1) because takotsubo cardiomyopathy is most likely associated with postmenopausal female, but it can be occurred among male gender also. Myasthenia gravis is also associated most likely with female gender because it is an autoimmune disease, and the autoimmune diseases are more common in female gender. Table 2 represents the age group distribution of cases. Frequency of patients in age more than 15 is the highest (Figure 1). The



**Figure 1.** Age distribution of takotsubo cardiomyopathy in patients with myasthenia gravis.

**Table 2.** Age distribution.

Value	Low bin	Upper bin	Frequency
0 - 4	0	4	1
4 - 10	4	10	2
10 - 15	10	15	3
15 - 30	15	30	1
30-More	30	More	0

age groups over 15 years old, especially in presence of malignant thymoma, cardiac medications as beta blockers have been led to exacerbation of myasthenia gravis, so must be avoided in treating stress induce cardiomyopathy (broken heart syndrome), and most cases have been cured well.

## 5. Conclusion

Occurrence of takotsubo cardiomyopathy in patients with myasthenia gravis is a rare condition but a life threatening, so this study is made to find out the treatment and methods of prevention of it by analyzing the previous cases reported, and it must be understood clearly and avoided by avoiding stressful conditions as in [27] and triggering of mythenic crisis, and further studies should be focused in understanding the mechanism of occurrence for controlling it well.

## Conflicts of Interest

The author declares no conflicts of interest.

## References

- [1] Kuo, Y., Ottens, T.H., van der Bilt, I., Keunen, R.W. and Akin, S. (2021) Myasthenic Crisis-Induced Takotsubo Cardiomyopathy in an Elderly Man: A case Report of an Underestimated but Deadly Combination. *World Journal of Cardiology*, **13**, 21-27. <https://doi.org/10.4330/wjc.v13.i1.21>
- [2] Shivamurthy, P. and Parker, M.W. (2014) Cardiac Manifestations of Myasthenia Gravis: A Systematic Review. *IJC Metabolic & Endocrine*, **5**, 3-6. <https://doi.org/10.1016/j.ijcme.2014.08.003>
- [3] Douglas, T.M., Wengrofsky, P., Haseeb, S., Kupferstein, E., Kariyanna, P.T., Schwartz, J., Salciccioli, L. and McFarlane, S.I. (2018) Takotsubo Cardiomyopathy Mimicking Myocardial Infarction in a Man with Myasthenic Crisis: A Case Report and Literature Review. *American Journal of Medical Case Reports*, **6**, 184-188. <https://doi.org/10.12691/ajmcr-6-9-4>
- [4] Thanaviratnanich, S., Katirji, B. and Alsheklee, A. (2014) Broken Heart Syndrome during Myasthenic Crisis. *Journal of Clinical Neuromuscular Disease*, **15**, 90-95. <https://doi.org/10.1097/CND.000000000000022>
- [5] Hirose, K., Yamaguchi, H., Oshima, Y., Choraku, M., Hirono, A., Takamori, N. and Tamura, K. (2008) Severe Respiratory Failure and Torsades de Pointes Induced by Disopyramide in a Patient with Myasthenia Gravis. *Internal Medicine*, **47**, 1703-1708. <https://doi.org/10.2169/internalmedicine.47.0976>
- [6] Nishijuka, F.A., El Hage Ahmad, K.A. and Zuchen, F. (2022) Myasthenia Gravis and Takotsubo Syndrome. *Journal of the American College of Cardiology*, **79**, 3374-3374. [https://doi.org/10.1016/S0735-1097\(22\)04365-0](https://doi.org/10.1016/S0735-1097(22)04365-0)
- [7] Nishinarita, R., Kawamura, Y., Yasuda, T., Horikoshi, Y., Ito, D., Sugihara, T., *et al.* (2012) A Case of Takotsubo Cardiomyopathy Leading to the Diagnosis of Myasthenia Gravis. *Journal of Cardiology Cases*, **6**, e141-e144. <https://doi.org/10.1016/j.jccase.2012.07.005>
- [8] Parodi, G., Bellandi, B., Del Pace, S., Barchielli, A., Zampini, L., Velluzzi, S., *et al.* (2011) Natural History of Tako-Tsubo Cardiomyopathy. *Chest*, **139**, 887-892. <https://doi.org/10.1378/chest.10-1041>

- [9] Kariyanna, P.T., Sutarjono, B., Jayarangaiah, A., Okwechime, R., Jayarangaiah, A., Wengrofsky, P. and McFarlane, I.M. (2019) Defining Features of Patients Who Develop Takotsubo Cardiomyopathy during Myasthenic Crisis: A Systematic Review of Case Studies. *American Journal of Medical Case Reports*, 7, 203-209. <https://doi.org/10.12691/ajmcr-7-9-6>
- [10] Sousa, J.M., Knobel, M., Buchelle, G., Sousa, J.A., Fisher, C.H., Born, D., Akamine, N. and Knobel, E. (2005) Síndrome da disfunção apical reversível (Takotsubo) [Transient Ventricular Dysfunction (Takotsubo Cardiomyopathy)]. *Arquivos Brasileiros de Cardiologia*, 84, 340-342. <https://doi.org/10.1590/S0066-782X2005000400013>
- [11] Pongbangli, N., Jae-Aue, S., Wongcharoen, W. and Phrommintikul, A. (2019) Takotsubo Cardiomyopathy Complicated with Left Ventricular Thrombus in Myasthenic Crisis: A Case Report. *American Journal of Case Reports*, 20, 743-747. <https://doi.org/10.12659/AJCR.915415>
- [12] Jeans, K., Kapoor, S. and Siddique, M. (2018) Broken Hearted from Myasthenia. *Chest*, 154, 73A. <https://doi.org/10.1016/j.chest.2018.08.067>
- [13] Giallafos, E., Zouvelou, V., Maurogeni, S. and Stamboulis, E. (2016) Subclinical Cardiac Involvement in Thymomatous Myasthenia Gravis. *Hellenic Journal of Cardiology*, 57, 345-347. <https://doi.org/10.1016/j.hjc.2017.01.024>
- [14] Gautier, P., Ravan, R., Najjar, M., Belhakem, A., Ferrier, N., Marcaggi, X., Colamarino, R. and Amat, G. (2011) Syndrome Tako-tsubo au décours d'une perfusion d'immunoglobuline humaine normale (Tégeline®) [Tako-Tsubo Syndrome during Normal Human Immunoglobulin Perfusion]. *Annales de Cardiologie et d'Angéiologie (Paris)*, 60, 290-295. <https://doi.org/10.1016/j.ancard.2011.08.003>
- [15] Jolly, G., Haidry, A., Koulova, A., Horblitt, A., Naidu, S. and Cooper, H. (2018) Myasthenia Gravis Crisis Associated Stress (Takotsubo) Cardiomyopathy. *Journal of the American College of Cardiology*, 71, A2355. [https://doi.org/10.1016/S0735-1097\(18\)32896-1](https://doi.org/10.1016/S0735-1097(18)32896-1)
- [16] Khan, M.S., Nwaedozie, S., Shogren, S.L., Malovrh, R. and Surendran, S. (2023) Acute Hypoxia from Different Clinical Entities Can Potentially Break the Heart: Takotsubo Cardiomyopathy. *WJM*, 122, 70-73.
- [17] Ho, R.Y.J., Chern, Z.R.B. and Kristanto, W. (2019) Takotsubo Cardiomyopathy, or "Broken-Heart Syndrome", with Concomitant Myasthenic Crisis. *Singapore Medical Journal*, 60, 267-269. <https://doi.org/10.11622/smedj.2019046>
- [18] Battineni, A., Mullaguri, N., Thanki, S., Chockalingam, A. and Govindarajan, R. (2017) A Case Report of Recurrent Takotsubo Cardiomyopathy in a Patient during Myasthenia Crisis. *Case Reports in Critical Care*, 2017, Article ID: 5702075. <https://doi.org/10.1155/2017/5702075>
- [19] Beydoun, S.R., Wang, J., Levine, R.L. and Farvid, A. (2010) Emotional Stress as a Trigger of Myasthenic Crisis and Concomitant Takotsubo Cardiomyopathy: A Case Report. *Journal of Medical Case Reports*, 4, Article No. 393. <https://doi.org/10.1186/1752-1947-4-393>
- [20] Bijulal, S., Harikrishnan, S., Namboodiri, N., Ajitkumar, V.K., Gupta, D. and Mathuranath, P.S. (2009) Tako-Tsubo Cardiomyopathy in a Patient with Myasthenia Gravis Crisis: A Rare Clinical Association. *BMJ Case Reports*, 2009, bcr06.2008.0182. <https://doi.org/10.1136/bcr.06.2008.0182>
- [21] Jahangir, A., Rafay, K.N.M., Sahra, S., Javed, A. and Krzyzak, M. (2022) An Unfortunate Case of Takotsubo Cardiomyopathy during Plasmapheresis for Myasthenia Crisis. *Cureus*, 14, e20865. <https://doi.org/10.7759/cureus.20865>

- 
- [22] Mayor-Gomez, S., Lacruz, F. and Ezpeleta, D. (2012) Crisis miastenica y sindrome de takotsubo: Una relacion no casual [Myasthenic Crisis and Takotsubo Syndrome: A Non-Chance Relationship]. *Revue Neurologique*, **55**, 725-728. <https://doi.org/10.33588/rn.5512.2012465>
- [23] Harries, I.B., Levoir, H., Bucciarelli-Ducci, C. and Ramcharitar, S. (2015) Takotsubo Cardiomyopathy in Myasthenia Gravis Crisis Confirmed by Cardiac MRI. *BMJ Case Reports*, **2015**, bcr2015209631. <https://doi.org/10.1136/bcr-2015-209631>
- [24] Pelliccia, F. and Gaudio, C. (2020) Takotsubo Syndrome and Myasthenia Gravis: When Neuromuscular Disease Meets Cardiac Dysfunction. *International Journal of Cardiology*, **299**, 73-74. <https://doi.org/10.1016/j.ijcard.2019.10.014>
- [25] Arai, M., Ukigai, H. and Miyata, H. (2004) A Case of Transient Left Ventricular Ballooning ("Takotsubo"-Shaped Cardiomyopathy) Developed during Plasmapheresis for Treatment of Myasthenic Crisis. *Rinsho Shinkeigaku*, **44**, 207-210.
- [26] Ramrattan, A., Gonzalez, I., Abdullah, H., Maraj, K. and Browne, M. (2022) A Myasthenic Crisis Complicated by a Takotsubo Cardiomyopathy. *Cureus*, **14**, e21067. <https://doi.org/10.7759/cureus.21067>
- [27] Rathish, D. and Karalliyadda, M. (2019) Takotsubo Syndrome in Patients with Myasthenia Gravis: A Systematic Review of Previously Reported Cases. *BMC Neurology*, **19**, Article No. 281. <https://doi.org/10.1186/s12883-019-1523-z>
- [28] Gayfield, S., Busken, J. and Mansur, S. (2022) A Case Report and 31-Case Study: Does Takotsubo Cardiomyopathy in Myasthenia Gravis Patients Have a High Mortality Rate? *Cureus*, **14**, e28625. <https://doi.org/10.7759/cureus.28625>